This is a digital copy of a book that was preserved for generations on library shelves before it was carefully scanned by Google as part of a project to make the world's books discoverable online.

It has survived long enough for the copyright to expire and the book to enter the public domain. A public domain book is one that was never subject to copyright or whose legal copyright term has expired. Whether a book is in the public domain may vary country to country. Public domain books are our gateways to the past, representing a wealth of history, culture and knowledge that's often difficult to discover.

Marks, notations and other marginalia present in the original volume will appear in this file - a reminder of this book's long journey from the publisher to a library and finally to you.

Usage guidelines

Google is proud to partner with libraries to digitize public domain materials and make them widely accessible. Public domain books belong to the public and we are merely their custodians. Nevertheless, this work is expensive, so in order to keep providing this resource, we have taken steps to prevent abuse by commercial parties, including placing technical restrictions on automated querying.

We also ask that you:

+ *Make non-commercial use of the files* We designed Google Book Search for use by individuals, and we request that you use these files for personal, non-commercial purposes.
+ *Refrain from automated querying* Do not send automated queries of any sort to Google's system: If you are conducting research on machine translation, optical character recognition or other areas where access to a large amount of text is helpful, please contact us. We encourage the use of public domain materials for these purposes and may be able to help.
+ *Maintain attribution* The Google "watermark" you see on each file is essential for informing people about this project and helping them find additional materials through Google Book Search. Please do not remove it.
+ *Keep it legal* Whatever your use, remember that you are responsible for ensuring that what you are doing is legal. Do not assume that just because we believe a book is in the public domain for users in the United States, that the work is also in the public domain for users in other countries. Whether a book is still in copyright varies from country to country, and we can't offer guidance on whether any specific use of any specific book is allowed. Please do not assume that a book's appearance in Google Book Search means it can be used in any manner anywhere in the world. Copyright infringement liability can be quite severe.

About Google Book Search

Google's mission is to organize the world's information and to make it universally accessible and useful. Google Book Search helps readers discover the world's books while helping authors and publishers reach new audiences. You can search through the full text of this book on the web at `http://books.google.com/`

PROPERTY OF THE
PUBLIC LIBRARY OF THE
CITY OF BOSTON,
DEPOSITED IN THE
BOSTON MEDICAL LIBRARY.



BOSTON
MEDICAL LIBRARY
8 THE FENWAY

TRANSACTIONS

OF THE

AMERICAN

OPHTHALMOLOGICAL SOCIETY.

EIGHTH ANNUAL MEETING.

Newport, July, 1871.

NEW YORK:
D. APPLETON AND COMPANY,
549 & 551 BROADWAY.
1871.

INDEX.

PAGE

Members of the Society 5

Minutes of Eighth Annual Meeting 7

Report on the Progress of Ophthalmology. By B. Joy Jeffries, M. D., Boston 13

An Apparatus for cutting Microscopic Sections of Eyes. By Edward Curtis, M. D., New York 60

General Syphilitic Inflammation of the Eye. By Francis Delafield, M. D., New York 69

Halo round Macula. By Edward G. Loring, M. D., New York 73

A Scheme to aid in recording and examining Cases of Asthenopia. By Henry D. Noyes, M. D., New York 81

On the Tables given by Loring and Knapp to show the Displacement of the Retina in Ametropia. By O. F. Wadsworth, M. D., Boston. 87

Variety of Forms of Small Pencils of Astigmatic Rays. By Gustavus Hay, M. D., Boston 90

The Retina an Asymmetrical Surface. By Russell Murdoch, M. D., Baltimore 93

An Additional Method for the Determination of Astigmatism. By George Strawbridge, M. D., Philadelphia 100

On Astigmatism as an Active Cause of Myopia. By J. Green, M. D., St. Louis 105

An Astigmatic Glass for Cataract Patients, with some Remarks on the Statistics of Vision in Cataract Operations. By Edward G. Loring, M. D., New York 108

An Apparatus for testing the Perception of Color. By Henry D. Noyes, M. D., New York 118

Modification of Jaeger's Ophthalmoscope. By G. Strawbridge, M. D., Philadelphia 120

Gunshot-wound of the Brain, followed by Fungus Cerebri: Hemiopsia. By William F. Thomson, M. D., Philadelphia 122

PAGE

Detachment of Retina with Laceration at Macula. By HENRY D. NOYES, M. D., New York 128

Report of Passavant Operations with and without Ether, and also under Nitrous Oxide. By B. JOY JEFFRIES, Boston 130

Readjustment of Levator Muscle of Upper Lid. By J. GREEN, M. D., St. Louis 134

Additional Note upon the Use of Atropine in the Treatment of Incipient Strabismus. By J. GREEN, M. D., St. Louis 136

Paralysis of Trigeminus followed by Sloughing of Cornea. By WILLIAM F. NORRIS, M. D., Philadelphia 138

A Case of Congenital Fissure of the Lids. By W. W. SEELY, M. D., Cincinnati 142

Congenital Absence of both Eyeballs. By G. STRAWBRIDGE, M. D., Philadelphia 144

MEMBERS

OF THE

American Ophthalmological Society.

ACTIVE MEMBERS.

Dr. C. R. Agnew	New York,	New York.
Dr. C. M. Allin	"	"
Dr. H. Althof	"	"
Dr. Joseph Aub	Cincinnati,	Ohio.
Dr. Charles S. Bull	New York,	New York.
Dr. F. J. Bumstead	"	"
Dr. William H. Carmalt	"	"
Dr. Edward Curtis	"	"
Dr. Edward M. Curtis	Sacramento,	California.
Dr. Edward Delafield	New York,	New York.
Dr. Francis Delafield	"	"
Dr. Hasket Derby	Boston,	Massachusetts.
Dr. R. H. Derby	New York,	New York.
Dr. John H. Dix	Boston,	Massachusetts.
Dr. A. Du Bois	New York,	New York.
Dr. E. Dyer	Philadelphia,	Pennsylvania.
Dr. Henry C. Eno	New York,	New York.
Dr. John Green	St. Louis,	Missouri.
Dr. A. D. Hall	Philadelphia,	Pennsylvania.
Dr. Gustavus Hay	Boston,	Massachusetts.
Dr. John H. Hinton	New York,	New York.
Dr. Edward L. Holmes	Chicago,	Illinois.
Dr. Edwin Hutchinson	Utica,	New York.
Dr. B. Joy Jeffries	Boston,	Massachusetts.
Dr. Samuel J. Jones	Chicago,	Illinois.
Dr. H. Knapp	New York,	New York.
Dr. Edward G. Loring	"	"
Dr. Arthur Matthewson	Brooklyn,	"
Dr. H. G. Miller	Providence,	Rhode Island.

Dr. T. G. Morton	Philadelphia,	Pennsylvania.
Dr. Russell Murdoch	Baltimore,	Maryland.
Dr. Homer G. Newton	Brooklyn,	New York.
Dr. William F. Norris	Philadelphia,	Pennsylvania.
Dr. Henry D. Noyes	New York,	New York.
Dr. J. F. Noyes	Detroit,	Michigan.
Dr. O. D. Pomeroy	New York,	New York.
Dr. Thomas R. Pooley	"	"
Dr. J. S. Prout	Brooklyn,	"
Dr. Charles E. Rider	Rochester,	"
Dr. C. A. Robertson	Albany,	"
Dr. D. B. St. John Roosa	New York,	"
Dr. W. W. Seely	Cincinnati,	Ohio.
Dr. Henry L. Shaw	Boston,	Massachusetts.
Dr. Francis Simrock	New York,	New York.
Dr. Francis P. Sprague	Boston,	Massachusetts.
Dr. George Strawbridge	Philadelphia,	Pennsylvania.
Dr. William F. Thomson	"	"
Dr. O. F. Wadsworth	Boston,	Massachusetts.
Dr. Robert Willard	"	"
Dr. A. D. Williams	Cincinnati,	Ohio.
Dr. E. Williams	"	"
Dr. Henry W. Williams	Boston,	Massachusetts.
Total		51

HONORARY MEMBERS.

Dr. G. A. Bethune	Boston,	Massachusetts.
Dr. Isaac Hays	Philadelphia,	Pennsylvania.
Dr. R. Hooper	Boston,	Massachusetts.
Dr. John Jeffries	"	"
Dr. E. Reynolds	"	"
Dr. C. Schweigger	Berlin,	Prussia.
Dr. George Wilkes	New York,	New York.
Total		7
Whole Number		58

AMERICAN

Ophthalmological Society.

NEWPORT, *July* 20, 1871.

The Society met at the Ocean House, at 10 A. M., and was called to order by the President, Dr. H. W. WILLIAMS.—Present:

Dr. C. R. AGNEW	New York.
" F. DELAFIELD	"
" O. D. POMEROY	"
" E. G. LORING	"
" EDWARD CURTIS	"
" WM. F. NORRIS	"
" H. D. NOYES	Philadelphia.
" WM. THOMSON	"
" E. DYER	"
" G. HAY	Boston.
" B. J. JEFFRIES	"
" O. F. WADSWORTH	"
" H. G. NEWTON	Brooklyn.
" JOHN GREEN	St. Louis.

Minutes of the session of the last day of the last meeting read and approved. The President appointed a Business Committee to prepare a bulletin, and to select the topic of discussion for next meeting, consisting of Drs. Agnew and Thomson.

He also appointed a Nominating Committee, consisting of Drs. Loring, Wadsworth, Norris, Green, and Pomeroy. The Secretary presented the resignation of Dr. Robert Watts,

of New York, which was accepted. The Nominating Committee reported for election as active members:

Dr. George Strawbridge . .	Philadelphia.
" Charles S. Bull . . .	New York.
" Edwin Hutchinson . .	Utica.
" Richard H. Derby . .	New York.

All of whom were elected.

The Business Committee then reported the bulletin, which was taken up for consideration:

1. Remarks on cataract, by Dr. Loring. A pair of cataract-glasses was shown, in which a cylindric and a spherical surface were united by a novel method.

2. A case of congenital fissure of the lids, by Dr. Seely, of Cincinnati.

3. A case of congenital absence of both eyeballs, by Dr. George Strawbridge, of Philadelphia.

In reference to the question of how much effect in the production of congenital deformities is to be ascribed to impressions made on the mind of the mother during pregnancy, Dr. Agnew reported a case of a child born with staphyloma of the cornea, whose mother during pregnancy had been greatly disturbed by seeing, in Dr. Agnew's office, a patient having staphyloma of the cornea. Dr. Norris reported a case of congenital absence of the prepuce in a child whose mother during pregnancy had witnessed the operation of circumcision.

4. Sloughing of the cornea following paralysis of the trigeminal nerve, by Dr. Norris, of Philadelphia. Dr. Noyes related several cases which he had observed, and alluded to a report which he had recently made of some of them in the *New York Medical Journal.*

5. Dr. Jeffries read by title the report on ophthalmology, and reported also cases of herpes zoster ophthalmicus.

6. Two cases of general syphilitic inflammation of the eye, by Dr. F. Delafield, of New York, with morbid specimens.

7. Report of Passavant's operations, with and without ether, and also under nitrous-oxide gas, by Dr. Jeffries. Dr. Noyes related cases of the operation, in most instances with

success—in a few cases with relapses. Dr. Noyes was in the habit of using nitrous-oxide gas for minor operations on and about the eye.

8. An additional method for testing cases of astigmatism, by Dr. Strawbridge, of Philadelphia.

Dr. Green remarked upon the delicacy and value of the diagram described, but denied that it was new. He had used and exhibited similar figures, to be viewed, like this one, by transmitted light, and had made other diagrams on the same principle, some of which other members of the Society had also employed.

9. Variety of forms of astigmatic pencils, by Dr. Hay.

10. Ophthalmoscopic signs in asthenopia, by Dr. Loring, with drawings of alterations in the fundus oculi.

11. An apparatus for cutting microscopic sections of eyes, by Dr. Edward Curtis, of New York, with many specimens mounted for study under the microscope, which were examined by the Society. The papers were referred to the Publishing Committee.

On motion, adjourned.

EVENING SESSION, AT HALF-PAST SEVEN O'CLOCK.

President in the chair. Minutes of the previous meeting read and approved.

The Treasurer read his report, which was referred to an Auditing Committee, consisting of Drs. Dyer and Jeffries.

The bulletin was then resumed.

12. A case of readjustment of the levator palpebræ superioris, by Dr. Green.

13. Astigmatism from old corneal disease, treated by cylindrical glasses. Dr. Green.

14. Astigmatism as a cause of myopia. Dr. Green.

15. Experiences with the use of atropia in the treatment of strabismus. Dr. Green.

16. Remarks on Sämisch's method of treating ulcus corneæ serpens, by Dr. Noyes.

17. Description of a Jaeger's ophthalmoscope, modified by Dr. Strawbridge.

Papers referred to Publishing Committee.

On motion, adjourned.

July 21, 1871.

Society met at 9½ A. M. The President in the chair. Minutes of previous meeting read and approved. Dr. Jeffries offered the following resolutions, which were adopted:

Resolved, That the Committee of Publication be directed not to print any communication unless it has been presented in person by the author at the annual meeting, except it shall have been accompanied by explanations of his non-attendance which shall be satisfactory to the Society.

Resolved, That the Secretary be directed to communicate this vote to the members of the Society before January, 1872.

The Auditing Committee reported the Treasurer's account correct and properly vouched for.

The Secretary moved that the resolution, adopted for two years past, relating to papers to be sent to the Publishing Committee, be reënacted, and that the date of reception of papers be September 1st. Adopted.

The bulletin was next in order.

18. On the tables given by Loring and by Knapp to show the amount of displacement of the retina in ametropia, by Dr. Wadsworth.

19. The halo seen around the macula lutea, illustrated by an apparatus, by Dr. Loring.

20. A scheme for recording cases of asthenopia, and a disk to aid in testing perception of color, by Dr. Noyes.

21. Cases of hemiopia, by Dr. Thomson.

22. The retina an asymmetrical surface, by Dr. Murdoch, of Baltimore; the paper read by Dr. Agnew. Dr. Hay made remarks in criticism of the paper, which he was requested to put in writing for the Publishing Committee, and to send a copy to Dr. Murdoch, who was absent from the meeting.

23. Cases of soft cataract, treated by discission, by Dr. Agnew; read by title.

24. A peculiar case of sub-retinal effusion, by Dr. Noyes.

The above papers all referred to the Publishing Committee.

The Nominating Committee then reported for reëlection the same officers as for the last year, viz.:

President, Dr. H. W. Williams, of Boston.

Vice-President, Dr. C. R. Agnew, of New York.

Recording Secretary and Treasurer, Dr. Henry D. Noyes, of New York.

Corresponding Secretary, Dr. H. Althof, of New York.

Committee on Progress of Ophthalmology, Dr. B. J. Jeffries, of Boston.

Publishing Committee, Drs. Loring, Roosa, and Noyes.

All of whom were duly elected.

The place of meeting to be either Niagara or Newport, the latter was chosen by a vote of eight to three. The time of meeting to be the third Thursday in July.

It was voted that the assessment for the ensuing year be ten dollars, and that the Publishing Committee be authorized to call for an additional assessment if necessary.

After reading the minutes, on motion, adjourned.

Henry D. Noyes, M. D.,
Recording Secretary.

IN MEMORY OF

ALBRECHT VON GRAEFE,

Whose life and work so greatly helped to turn a doubtful specialty into a certain science.

REPORT ON THE PROGRESS OF OPHTHALMOLOGY. By B. Joy Jeffries, M. D., Boston.

For the fifth time as your committee, I would make my report on the progress of our specialty. As I said last year, perhaps a running sketch, without criticism, of what has been published since we last met, will more readily inform those of the profession outside of our specialty what is going on among us, and also save time for some of us who are too busy to keep as thoroughly conversant with others' results as they could wish, and as the ever-advancing science of ophthalmology demands. I would again call attention to the report of our Secretary, Prof. Noyes, published in the New York Medical Journal early in this year. The articles he has there sketched I have, of course, omitted to notice in detail here. It has been fortunate that I could not finish this report till the time it was absolutely called for by the publishing committee, since thus I have been enabled to notice all the material which the war in France and Germany had delayed the printing of, and which, of course, properly belonged to the time when it was ready for the press.

I therefore here give a brief sketch of what has been published, since my last report, in "Graefe's Archiv für Ophthalmologie," now continued by Donders, Arlt, and Leber, the

"Klinische Monatsblätter für Augenheilkunde," the "Annales d'Oculistique," the "Royal London Ophthalmic Hospital Reports," the "Giornale d'Oftalmologia Italiano," the "Archives of Ophthalmology and Otology," and the new Italian journal, commenced this year, the "Annali d'Oftalmologia." I have also noticed some of the books and monographs published, and the scattered articles in various reviews and society reports. Appended is a list of those which time and space have failed me to sketch in detail; the ophthalmic journals where these latter have been discussed will be found mentioned, e. g., Zehender's Monatsblätter, or the Annales, etc.

Again, we would call the attention of our brother ophthalmic surgeons in this country to the fact that the profession at large have a right to demand from them a better *account* of their stewardship at the ophthalmic hospitals and infirmaries now established in our larger cities. Also, we may justly ask in return for a more definite recognition of our specialty on the part of many of the professional schools and colleges.

Ophthalmology has recently lost from its ranks some devoted workers and earnest thinkers. The pens of friends and colleagues have better told than I can here, what our specialty owes to Alexander Quadri, of Naples, and Auguste Serre, of Uzès.

While we were gathering last year from the various parts of this country to our annual meeting at Newport, one of the confessedly greatest clinical teachers and leaders passed away from his life and work. Albrecht von Graefe, I hold, was the greatest scientific practitioner in the medical profession. Higher praise I cannot give. That it is not too great has been amply proved by what has been written of his life and work by his nephew, Prof. Alfred Graefe, in his "Ein Wort der Erinnerung an Albrecht von Graefe," Halle, 1870; Dr. A. Goschen's "Albrecht von Graefe," Berlin, 1870; and Dr. Cohn's "Was verdankt die Menschheit Albrecht von Graefe," Breslau, 1871. An extended compilation of what has been said of Graefe will also be found in the Ophthalmic Hospital Reports, London, which journal, as well as all the other ophthalmic reviews in the different parts of the world, have spoken editorially of Von Graefe in such terms as are applied to but few, and deserved by as few.

Let the commemorative page at the head of this report prove to the profession that our Society recognizes what Albrecht von Graefe has done for us and them.

Archiv für Ophthalmologie, Bd. 16, 1870.

Corneal Abscess. Prof. ARLT.—The clinical reputation of our former master induces us to give in detail his report of treatment. He says, when we have an abscess, we must treat the patient as if already suffering from *iritis*, since this, if not already present, may occur any minute. The eyes are to be protected from strong light and accommodative efforts, and the iris kept under atropine.

As with the open corneal ulcer, so also with the closed (an abscess), we must decide whether pus-formation exists and continues with symptoms of irritation, as ciliary injection, tears, photophobia, and pain; whether, when these cease, the pus-formation stops; or whether the eye is in, so to speak, a torpid condition, with increasing purulent formation. In the first case every thing irritating is to be kept away, and we must use local bleeding, narcotic inunctions on brow and temple, and morphine injections, cooling cathartics, etc., without, however, reducing the strength too much. Simple opening of the abscess or of the anterior chamber in addition will be indicated or demanded on the yellow color of pus showing its collecting in the anterior chamber, the cornea, or both. He perfectly agrees with Weber's advice, to make the opening with an iridectomy-knife below the abscess, thrusting up and backward, making the cut 2½''' to 3'''. He avoids turning the knife, in coming out, to prevent too rapid evacuation of aqueous, and uses a Daviel's spoon to gradually open the wound, and has fine forceps ready to remove lumps of pus sticking in the cut. He does not consider the perfect evacuation of the abscess or chamber absolutely necessary, since quite sizable remains of pus may be absorbed or extruded within twenty-four hours. He warns against injections, formerly advised. If merely the abscess is to be opened, he uses a cataract-knife, passing it through the under part of the anterior wall, making, not a cataract flap-like cut, but rather a linear or curved section. In regard to Sämisch's

proposed plan of opening corneal ulcers, Arlt will not at present decide. When there are only small deposits along the edge to be released, he makes a 1–2‴ long opening on either side. Sometimes a radial cut into the cycle-shaped deposit allows the pus to escape, or two or three such cuts may be made. He uses a compressive bandage tighter at first, covering also the other eye from light, and keeping the patient if possible a few hours in bed. On reappearance of pus in twenty-four hours, he uses a Daviel's spoon to open the wound only when the abscess progresses or severe pain returns. When a necessity for evacuation of the pus shows itself by the third day, or later, he again punctures in the same or a neighboring place. Although the continued pressing open of the wound was recommended by Himly in 1843, yet Arlt does not greatly favor it, since he found no good result after doing it two or three times.

He has had good results from opening the abscess, or the chamber alone, although, in spite of this, a goodly number of eyes have been lost after repeated puncture, where this result was quite unexpected. The patients were, however, all in poor condition, or affected with lachrymal blennorrhœa. He always slits up the lower canaliculus and evacuates the pus in these last-named cases. The excessive pain accompanying these abscesses is best relieved by opening the chamber, and warm moist applications. When pus in the chamber reaches the pupil, puncture is indicated to prevent iritic attachments and pupillary membranes, even when the condition of the cornea or pain does not seem to require it.

Iridectomy he does not so much favor from experience, perhaps, as he says, because he has regarded it as the *ultimum refugium.* It is not so readily done, since the iris may be quite soft.

If, now, we have the pus in the cornea quiescent or progressing peripherically, while the eye presents no conditions of irritation, then opening the abscess or the chamber, or both, are to be thought of; but, at the same time, we must decide whether this torpor is simply local or connected with the strength or spirits of the patient. Anxiety, care, and homesickness, act very depressingly, as if the vascular and nervous

activity were paralyzed thereby, and hence digestion and nutrition interfered with. Out-door exercise, stimulants, iron, quinine, and mineral acids, are then in place. Warm cataplasms are to be used only under the physician's eye. Small deposits may be touched, even where there is some irritation, with a sharp pencil of nitrate of silver, to expose the pus there collected.

Above all these absolutely necessary means, Arlt holds a compressive bandage, by which he means such as shall prevent *motion of the lids* quite distinct from the usual compressive bandage of Graefe. He uses also the collodion bandage, which he spoke of in vol. ix., p. 1, when the patient strongly objects to operative interference. In regard to Sämisch's operation so successfully used by himself, Arlt speaks with some degree of reserve. He says it, as all other operations, is to be postponed so long as there is fair hope of succeeding with the lint-bandage. His whole treatment is well worth carefully reading by any one having under his care these ugly forms of corneal abscesses.

Drs. Hippel and Gruenhager continue and finish their article "*On the Effect of the Nerves on Intraocular Pressure.*"

Dr. Monnik describes "*A New Tonometer and its Use.*" From a series of experiments he finds that the tension of a normal eye may vary considerably, rendering it difficult to decide sometimes whether an eye is to be considered hard or soft. Age has an influence on the ocular tension, increasing with it. Tension in myopes was found within the normal range, in hypermetropes as in normal. Tension varies in diseased eyes as in normal ones. With strong convergence, notwithstanding the subjective feeling of tension, there is, in reality, no alteration, contrary to what might have been expected from Dr. Schurman's results in his dissertation on the action of the antagonistic muscles. In reference to the pressure of vitreous and aqueous, experiment shows that the iris, at least after death, offers very little resistance.

Prof. Alfred Graefe reports an interesting case of *Blepharospasmus;* also one of "*A Seeming Perversion of the Law of Concomitant Squint in Certain Forms of Anisometropia.*"

The result of examination educed that, 1. One eye is hypermetropic, while the other may be myopic or emmetropic; 2. There is insufficiency of the R. interni; 3. Each eye has sufficiently good vision.

Now, as was proved, the covered myopic eye *converged*, the covered hyperopic eye diverged. Neglecting to notice this might, in certain cases, lead to practical mistakes.

Dr. Haase reports on the pathological anatomy of a case of "*Coloboma of the iris and choroid.*" It seems the retina may remain intact over a coloboma of the choroid; and, if further examinations should substantiate this, then it must be that the primitive ophthalmic groove closed at the right time, and some days later an interference occurred in the growth and development of the retina.

Dr. Claassen, on "*Resistance to Single Vision after Operation for Internal Squint, in reference to the Theory of Retinal Congruence.*" We give only his closing paragraph: "May not some psychological data underlie the meaning of this case, which may be peculiar to every individual, but not subject to such strict analysis as by the mathematical method; if so, then the principles elucidated are of still greater importance. Comparing the cases similar to this, published by Von Graefe and Alfred Graefe, and we shall find them explainable by the same fundamental laws. Hence the importance of separating the two elements of the visual act as distinct from each other—seeing with subjective visual field, only possible from *a priori* given extended retinal impression, and the projection of the visual field for the purpose of objective vision. The relations of congruence are the immediate result of seeing (Orientirung) in subjective visual field, and the combined use of the two eyes."

Accommodation in Presbyopia.—Drs. Adamük and Woinow report, as the result of absolute measurement, that the posterior surface of the lens becomes more curved in old people in accommodation than has been thought, even as much as the interior surface, but the two curves together are not as much as in young people. They say that, from their present data, they are quite unable to deduce the cause of this; their measurements, careful as they were, answered nothing in

reference to the question of accommodation. In the eyes examined they ascertained that the posterior surface of the lens changed, in relation to the anterior surface, more where the pupils were small.

The Movements of the Globe exhibited by the Phænophthalmotrope.—Prof. Donders shows, by a plate, the instrument thus called, which is contrived to exhibit the ocular movements correctly, a very desirable necessity for *teacher* as well as pupil. We must refer to the plate and article for his explanation, as without the former the latter would be unintelligible if here introduced.

Accommodation and Refraction. Dr. Schneller.—From a series of experiments we cannot here introduce, it is rendered probable that accommodation may take place differently in the two eyes, and that this variation, at least in myopia, may affect the refraction. This, once granted, gives us a further insight into the causal relations of many diseased conditions. May there not be a connection between this difference of accommodation and the fact that, in myopia, the right eye generally turns outward (in more than three to one of the cases), because there is here an anomaly of the accommodative position? It may be found in practice that more severe choroidal changes and deleterious affections of the eye are in myopia more frequent in the right than left. This would point toward taking care, in the selection of glasses for myopes, to consider this disposition of the right eye to injure itself by excessive accommodation.

The Contest of the "Nativisten" and "Empiristen," although a philosophical one, may be thus of eminent practical importance, and induce ophthalmic surgeons to test experimentally this question, and see whether Dr. Schneller's results are individual or general.

Contention of the Visual Field. M. Woinow.—This is a condition caused by exhibiting to each eye different pictures or visual fields. In some cases the dominant contour or color alternates; in others, the color of the whole field is more steady; and again, in others, we have the so-called glance or shimmer. Woinow found that the difference of the pictures to be combined may depend on variation in form; or, if the

form is the same, it may be due to difference in color or brightness; or, thirdly, it may depend on the clearness of the groundwork of the picture. In general, our *degree* of attention governs the perception of form. If we pay special attention to the bodily form of the picture, then the differently-colored outlines of the two stereoscopic pictures are seen side by side; if, on the other hand, we carefully examine the special details of the picture, then the "contention" takes place, and our will completely controls the appearing of one or the other picture. A general law held good that the contention was greater when the individual points of the picture were fixed, or when the color alone of the combined field was tested, especially if one of the combined surfaces was uneven. On the other hand, the contention was least when our attention was simply directed to the bodily form. As to the color of the common field, this is more quiet the less there is of contrast in the two fields (red and orange, orange and yellow, blue and violet, etc.). If there is considerable difference in the lightness of the two fields, then the common field shimmers.

As to this glance or shimmer, it is stronger the greater the contrast of the two fields in color and brightness; the latter, however, affects it most. The brighter the one and darker the other field, the stronger the shimmer; for instance, a black and a white surface. When we close one eye, and again presently open it, the common field appears more of the color which is now presented to the reopened eye. Occasionally, during certain moments, the alternating colored spots in the common field began to appear close to the object delineated, and at first took the form or figure which they would assume as after pictures.

On Color-perception. Same author.—By a series of careful experiments with colored papers, etc., Woinow has found that red appears yellow as soon as it is removed from the optic axis, and gradually shades into yellowish brown, becoming darker the farther removed it is, till finally it seems black. This last, however, greatly depends on the ground on which the color lies. If the ground is brighter than the color examined, then the peripheric perception of the color will be black;

gray, on the other hand, if the ground is much darker than the color. Orange thus becomes yellowish and gradually dirtier, to a peripheric gray of varying brightness, in accordance with the ground it is on. Yellow appears gradually less deep, more whitish, and on the periphery seems almost a clear white. Green exhibits in this method of examination very peculiar appearances. It becomes laterally yellowish. Some greens give at certain spots a good clear yellow. Toward the periphery of the visual field it becomes dirtier, and finally ends in gray, of varying brightness, in accordance with the ground it is seen on. Like yellow, it never appears black on the periphery, as the other colors. A peculiar phenomenon is noticeable, when we view the spectrum with one eye directed to the red end. We then see first red, then a broad streak of yellow, and finally blue. Green will not be seen as such, but as yellow. Violet is also not visible.

Blue becomes less intense—a grayish blue. On the periphery it appears black. If the ground is too dark, it gives the impression of gray. Violet passes into blue, quite a strong blue at some portions of the visual field. On the periphery it acts as blue. Purple red passes into a dark violet, then into deep blue, and finally, on the periphery, acts as blue and violet. The changes depend principally on the degree of saturation, that is, whether it is a pure purple red or a more rosy red. On the periphery of the visual field, where we have no definite differences of color-perception, and only can distinguish between light and dark, all colors give, according to their ground, varying shades of brightness. The borders, where differences of color stop, are very definite, and are not dependent on the ground of the color. The border-lines of the visual field for differences of brightness vary, and are greater the greater the relative difference between the brightness of the pigmented surface and its ground.

On Binocular Vision. Same author.—He proposed three experimental questions, namely: 1. The examination of the contraction of the visual field in accommodation for the near; 2. The condition of the eyes in observing objects at different distances from them; 3. The accommodation individual to each eye during binocular vision of laterally dis-

posed objects. Contrary to Hering's results, he finds under the first head that the excursive power of the eyes is not limited in accommodation. The visual field alone, not the "Blickfeld," is contracted. From his experiments he also deduces that, in monocular vision, when the eye alternately focuses for objects at different distances, it does not necessarily undergo any convulsive action, but simply changes its accommodation; this, of course, only when all the objects fixed are in one and the same line coincident with the visual axis.

In careful binocular fixation of lateral objects, the accommodation of the two eyes varies, the eye nearest the object accommodating more strongly than the other.

Hence, from all Woinow's experiments, he deduces that there is not exactly the same innervation in reference to accommodation and movements of the two eyes in binocular vision, and that it is therefore impossible to reduce the action of the two eyes to that of one double (Cyclops) eye, as Hering has proposed.

In reference to the Angle Alpha. Same author.—An additional article to his previous ones. In this he concludes: 1. That the angle a and y not only vary in size, but have a different meaning; 2. That the angle a is of great importance as respects the elliptic and dioptric condition of the eye, and changes in accommodation, but has nothing to do with the refraction and position of the eyes; 3. That the angle y, which is quite independent of the accommodation, has a certain connection with the refraction and positions (movements) of the eyes; 4. That the angle a can only be measured according to the principle of Helmholz's method, and the angle y only according to Donders.

Rotation-point of the Eye. Same author.—Woinow, from experiment here declares that there is but one point of rotation in the eye. He holds that the eye not only turns round a fixed point, the rotation-point, when it passes from a primary to a secondary position, but also when it passes from a secondary into any other, and the changes of accommodation, as he has convinced himself, do not affect the rotation-point, as this remains unchanged.

The Intensity of Color-perception. Same author.—From a series of extremely interesting experiments, Woinow concludes

that the strength or intensity of color-perception is less than that of light-perception (shades). It is also different for different colors, independent of the brilliancy of the color or of the ground on which this is seen.

Experimental Research into the Diseases of the Optic Nerve consequent on Intracranial Troubles. Prof. MANZ.—He found that, as soon as even a little fluid was thrown beneath the cranial wall, there was seen a filling of the retinal veins, most visible on their first subdivisions; the arteries and capillaries showing varying conditions. Thus, increase of the venous calibre, and their tortuosity up to pulsatory movements, are of course the consequence and expression of a stasis which the venous blood has met with somewhere between the optic-nerve entrance and the vein into which the vena centralis retinæ empties.

Woinow noticed also constantly a contraction of the pupil, certain rotations of the globe, and closure of the lids. As soon as a certain amount of fluid of any character entered the cranium, a contraction of the pupil quickly followed, generally quite considerable; it was a sign that, if the animal's life was to be saved, the injection must cease, or else the experiment was rapidly fatal. This is of course at variance with the assumed position that cerebral pressure causes dilatation of the pupil. With this contraction of the iris there was always, as said, rotation of the globe and closure of the pupil; the rotation was upward, often accompanied also with a strong rotation on the visual axis.

Some Rare Ocular Tumors. Drs. HIRSCHBERG and HAPPE. —1. Glioma retinæ endophytum. In a young infant. No neoplastic growth in the uveal tract; it evidently started from the *pars ciliaris* and the neighborhood of the retina, and was microscopically undoubted glioma.

2. Sarcoma of the choroid and secondary tubercles in the retina and sclero-corneal region. Choroidal sarcoma occurred in a child twelve years old. The growth was free of pigment. The *secondary* tubercles in the retina came with *primary* choroidal tumor. Three interesting points.

Motions of the Hypermetropic Eye. Dr. KUGEL.—The result of testing his own hypermetropic and astigmatic eye

was to formulate this, namely, that it differed the least from the normal eye in those positions which are mostly used in looking at distance or near; and the abnormal turning and variations in elevation were more prominent the farther the eye moved from these positions. Thus it would seem that these accustomed positions were, so to speak, cultivated at the cost of the other less frequently used ones, since the ocular muscles in their development are accommodated to the special needs of accurate vision in the most usual position of the globes.

Development of Acute Myopia. Same author.—From two cases reported, Dr. Kugel believes himself justified in assuming that lengthening of the bulb may take place in exceptional cases where there is no predisposition; this change is due to alteration of the tissue of the sclera, this coat not preserving resistance sufficient to withstand the normal pressure within the globe, a condition dependent on concomitant intracranial, retrobulbar, or subconjunctival processes, or from inflammations within the globe in which the sclerotic has participated.

Effect of the Crystalline on Tension of the Iris. Same author.—His arguments show that the lens does cause a certain tension of the iris. He also shows that increase of vitreous does not press the lens forward.

Trichiasis Operation. Same author.—Dr. Kugel has operated on five hundred the last two years, and devotes a few pages to speaking of his results, and the various well-known operations as compared with each other.

A Ready Method of detecting Monocular Simulated Amaurosis or Amblyopia. Same author.—This depends on the fact that, if we hold a colored glass before the eyes, and at one side it is not transparent, we shall not be able to say, offhand, with which eye we are seeing, especially when the eyes have nearly equal power of vision. Monocular defects may also thus be demonstrated.

A Case of Acute Atropine-poisoning. Same author.—There was coma for sixty-two hours (the patient being fed by enema), before any reflex action was noticed, this latter consisting of a slight contraction of the lid to bright light. The

case was treated by repeated subcutaneous injections of morphine.

Inflammation of the Ciliary Region as Sequela of Febris Recurrens. Dr. LOGETSCHNIKOW.—An epidemic of *febris recurrens* in Petersburg and Moscow gave the doctor opportunity to observe this peculiar affection, already spoken of by others, as Middlemore and Himly. He saw over seven hundred cases, and holds to his previously-expressed views that it is an inflammation of the ciliary body tending, but not always, to run over to the iris. It occurs in from a few days to several months after the fever. Cases occurred when it came on during convalescence, but the eyes were never affected *between the attacks.* A more complete article in reference to the nomenclature and true position of this disease will appear as a separate publication.

Archiv für Ophthalmologie. ALBRECHT VON GRAEFE. Vol. xvii., part 1, *continued under* AHLT, DONDERS, and LEBER.

The Development of Myopia, based on the Examination of the Eyes of 4,358 *Scholars, Girls and Boys.* Dr. ERISMANN, St. Petersburg.—We can here only give a glance at these extremely interesting series of observations made at St. Petersburg in seven *gymnasia* with scholars from 10 to 21 years of age; one progymnasium, four German schools (boys and girls), 8 to 20 years of age, and a female gymnasium for the education of teachers, of ages from 17 to 24. Whole number examined 4,358.

Myopes	1,317	=	30.2 per cent.
Emmetropes	1,132	=	26. "
Hypermetropes	1,889	=	43.3 "
Amblyopes	20	=	0.5 "
Total	4,358		100 per cent.

Among 3,266 boys, there were

Myopes	1,017	=	31.1 per cent.
Emmetropes	867	=	26.5 "
Hypermetropes	1,369	=	42. "
Amblyopes	13	=	0.4 "
Total	3,266		100 per cent.

Among 1,092 girls, there were

Myopes	300	=	27.5 per cent.
Emmetropes	265	=	24.2 "
Hypermetropes	520	=	47.7 "
Amblyopes	7	=	0.6 "
Total	1,092		100 per cent.

Among 2,534 pupils of the Russian Gymnasia there were

Myopes	866	=	34.2 per cent.
Emmetropes	654	=	25.8 "
Hypermetropes	1008	=	39.5 "
Amblyopes	11	=	0.5 "
Total	2,534		100 per cent.

And among 1,824 pupils of the German schools, there were

Myopes	451	=	24.7 per cent.
Emmetropes	478	=	26.2 "
Hypermetropes	886	=	48.6 "
Amblyopes	9	=	0.5 "
Total	1,824		100 per cent.

The author concludes that between six and seven years of age still more hypermetropes will be found. He found in the lower classes two-thirds of the children thus, and even one-third in the upper classes. Remembering that, without atropine, hypermetropia cannot always be determined, it would seem that it is the normal, the common, condition of refraction of the young uninjured eye; and what we call emmetropia, or still more, myopia, is an exceptional condition for this age. A small part of these large number of hypermetropes remain so; the majority become myopic after passing through a condition of emmetropia.

Cohn says it seemed as if myopia was transmitted from mother to daughter, or from father to son. Erismann says he cannot confirm this, only that with myopic girls the number of myopic mothers is greater than with myopic boys. The number of myopic fathers of both boys and girls was decidedly greater, being 57.6 per cent.

He deduces that the use of concave glasses in itself has a bad effect on the eye while its condition of refraction is in a

process of change, and it is a misfortune to be obliged to order glasses for a young myope. Their use should be limited as much as possible; music, drawing, etc., should be forbidden when the object must be brought very near, or glasses be worn. This, of course, refers to progressive myopia of youth, but is of the greatest importance here. The wish to see in the distance does not countenance glasses; it is time enough when these myopes wear a glass after the tissue of the bulb has become firm. When absolutely necessary at school, a lorgnette can be used.

The increase of myopes among the older school classes of more years' study shows that it is the occupation, with all its concomitant circumstances, which produces this condition.

The becoming myopic of a hypermetropic or emmetropic bulb depends on the lengthening of its axis. Erismann says he is perfectly convinced and sure that by far the principal cause of this myopic globe is the working at badly-constructed school-desks, and inadequate and bad light.

We have but sketched a few sentences, to lead our readers to carefully study through Dr. Erismann's article, which should be seen and understood by all teachers and school-committees.

Support of the Eye during the Expiratory Pressure of Blood. Prof. Donders.—He concludes that the *external* vessels of the eye, as well as the *intra-* and *retro-ocular* are distended during expirations. The closure of the eyelids either limits or entirely prevents this, partly from pressure, partly, perhaps, from certain associated action. It was noticed that during every increased expiratory pressure the lids were closed or tended to close. Hence, closing the lids, combined with the action of the ocular muscles, prevents injury from blood overfilling.

Movements of Eyes. Dr. Skrebitzky.—His experiments show:

1. That bending the head toward the shoulder while keeping the eye fixed on a point at the height of the eye, and firmly attached to the head, caused for short distances a real movement of the eye around its visual axis in a direction contrary to the movement of the head, but not to the degree assumed by Hueck.

2. That there is an undoubted proportion between the lateral turning of the head and the movement of the eye. For himself, he found this to be for ten degrees of lateral motion of the head about one degree of movement of the eye around its visual axis.

Cerebral Atrophy of Optic Nerve, with Pressure Excavation of the Optic Papilla. Dr. SCHMIDT.—He thinks his case may have some meaning in reference to others diagnosticated as *glaucoma simplex*, simply from the pressure excavation, and in which iridectomy was of no possible avail.

Sensitiveness of the Eye for Spectral Colors. Dr. LAMANSKY.—A series of experiments has shown that our eyes are more sensitive to green, yellow, and blue, and less sensitive to violet, orange, and red, than to white light, so that, by experiments with color-sensation, the brightness of white is not exactly unity for the other colors to be compared with, as Aubert held in his experiments.

Negative After-Pictures. Drs. ADAMÜK and WOINOW.—Their experiments gave the following results:

1. Peripheric after-images, produced in broad daylight, appear in different colors than central ones.

2. The duration of the impression of the primary light has no effect on the color-tone of the after-image.

3. The difference of color-tone of the peripheric after-images takes place in all meridians from the centre.

4. In reference to the difference of the colored after-images, the whole retina may be divided into zones, which perfectly agree with those of color-impression in general.

The experiments showed also: 1. The duration of the after-image is in general not only subject to individual variations, but varies also in the same person. When several experiments are made in succession, the second in the same way and intensity as the first, then the variations amount to only one to two seconds.

2. The central after-images last longest, especially those with binocular fixation. This is explainable by the fact that there is less effort in binocular than in monocular fixation. The after-pictures from double images last a shorter time, as both experimenters found, and shorter with convergent than with parallel visual axes.

The duration of the after-image from different pigments (seen on variously-colored grounds) is about the same; the difference of duration is so slight as to prevent our deducing any special effect of the ground color on the retina.

Changes of the Pupil during Accommodation. Drs. Adamük and Woinow.—From experimental observation they conclude that in general, during accommodation, the centre of the pupil tends inward from the optic axis; this tendency, however, is not in proportion to the accommodation. Moreover, this tendency only shows itself when the fixation changes from the far to the near point of the eye; that is, when the whole range of accommodation is called into play. When the whole range is not called for, as in changing from one to a neighboring point, then there are variations from the law above given; the pupil's centre tends outward from its former position, in which a more distant object was being gazed at.

Contributions to the Pathological Anatomy of the Eye. Dr. Berthold.—1. Total sclero-choroideal staphyloma, vascular formation in the cornea and vitreous, atrophy of the uveal tract, congenital posterior capsular cataract.

2. The alterations of the eyeball occurring in meningitis. These he found to be: 1. Due to a spreading of the inflammation of the meninges to the globe; 2. This takes place through the lymphatics by the optic canal; 3. According to the intensity of the extended inflammation and the exudation thereby existing in the lymphatics of the eye, we have either a filling of Tenon's space with chemosis conjunctivæ, or a filling of the subvaginal room with stagnant papilla and neuritis optica, or, in the worst cases, to purulent retinal and vitreous inflammation; 4. Iritis and irido-choriditis in meningitis are consecutive.

Three Cases of Phthisis Bulbi, Sequelæ of Melanotic Choroidal Sarcoma.

A Case of Granuloma Iridis.

Bony Formation in Choroid, New Growths in Vitreous, Peculiar Condition of Optic Nerve.

Historical Notice of Morbus Basedowi, with reference to twenty Cases of the Disease seen by Dr. Emmet, who says it should not be called *Morbus Basedowi*, or *Graves's Disease*,

but properly *Parry's Disease;* why, we must refer our readers to the article.

Abuse of Spirits and Tobacco as Causes of Amblyopia. Dr. HIRSCHLER.—He thinks the abuse of both together the special cause of the disease; but, besides, must be reckoned all the additional conditions, hyperæmia of the brain, overwork of the eyes, producing troubles of the circulation within the globe, and individual peculiarities and dispositions. Prognosis is good if alcoholism has not proceeded too far; alcoholic amblyopia does not necessarily lead to optic atrophy; here "cessante causa, cessat effectus," leading in the first stages to complete recovery. When changes appear in the papilla the *restitutio in integrum* is no longer to be hoped for, yet a cessation of the process may occur and the visual power present be retained. The first indication for treatment is the removal of the cause; treatment of "magenkatarrh," strict diet, and open-air exercise. The author does not think much of antiphlogistic treatment often recommended, and only in place where there are internal hyperæmia of the globe and textural changes. Goudret's salve he has used very frequently.

True Rolling of the Eye around its Visual Axis. Dr. NAGEL.—This is a second article, which goes with one by Nagel, in the fourteenth volume of "Graefe's Archiv." He here says that it is a rule, when the head is bent toward the shoulder, the eyes turn in the opposite direction, around their visual axis, about the sixth part (measured by degrees) of the movement of the head. The object of this seems to be to assist the sensation of poise (Gleichgewichtsgefühl). The degree and direction of this rolling of the eyes depend on the lateral movement of the head from the upright normal position, no matter how this latter is accomplished.

Thirty-eight Cases of Accommodative Paralysis. Dr. SCHEBY-BUCK.—In nearly all these cases, dependent on different causes, a tonic treatment was pursued, combined with Calabar bean, which proved of great therapeutic value. He found: 1. Mydriasis in only one case of diphtheritic paralysis. In the other cases it occurred in only a small proportion. Mydriasis, when present, does not exactly coincide with the paralysis of the ciliary muscle. 2. Loss of refraction occurred;

always disappearing with the disease. 3. Occasionally loss of visual power was observed, depending perhaps on astigmatism of the lens, and disappearing with the accommodative paralysis. 4. Diagnosis can often be made by observing the absence of change of shape of the lens in changing accommodation. 5. Accommodative paralysis occurs with diphtheritic wounds. It has also been certainly seen in sausage-poisoning.

Clinical Cases. Dr. LANDERSBERG.—They are as follows: 1. A peculiar form of epidemic ophthalmia. 2. Further contribution to the essentials of phthisis bulbi, in which he says some of the inflammatory processes of the cornea may also become the source of secondary glaucoma. 3. Chronic idiopathic œdema of the left upper lid and conjunctiva bulbi.

Anomalous Forms of Retinitis Pigmentosa. Dr. LEBER. —(The new additional editor of this [Graefe's] Archiv.) He makes the following divisions:

1. Typical retinitis pigmentosa.

2. Retinitis pigmentosa with typical disturbance of vision and anomalous ophthalmoscopic appearances. Here belong:

a. The long-known retinitis pigmentosa *without pigment*, which passes with all possible shades into the common form. It shows that the essence of the process is not the pigmenting but the accompanying interstitial hypertrophy of the retinal neuroglia and atrophy of the nervous elements. In general, the ophthalmoscopic appearances are characteristic enough for diagnosis, even when pigment is absent.

b. Retinitis pigmentosa with disseminated atrophic masses in the choroid.

3. Retinitis pigmentosa with typical ophthalmoscopic appearances and anomalous forms of visual disturbance.

a. Retinitis pigmentosa with prominent loss of central vision.

b. Retinitis pigmentosa with typical ophthalmoscopic appearances and good central vision, but with variations in the other symptoms of visual power.

4. Retinitis pigmentosa with anomalous ophthalmoscopic appearances and anomalous visual disturbances. Here the most numerous are:

a. Amblyopia or amaurosis, congenital, from retinitis pigmentosa.

b. Retinitis pigmentosa, not congenital, with principally central amblyopia and absence of retinal pigmenting.

c. Chorio-retinitis pigmentosa with anomalous symptoms.

5. Retinitis pigmentosa with varying course, unequal affection of the two eyes. Dr. Leber says that what he has presented naturally tells us nothing of the cause of retinitis pigmentosa, and is but a slight contribution to the material facts. It may be at least assumed that retinitis pigmentosa is on the whole a many-sided affection. If we would retain the name of retinitis pigmentosa for the typical cases, we must grant that it shades through many variations into the allied forms of this disease, and can be considered but as one of several related affections, which is dependent on the parents' consanguinity, or is hereditary.

Needle-Forceps, a New Instrument to form Pupils in Tough Membranes. Dr. HEYMANN.—It can hardly be clearly understood except by seeing the accompanying woodcut of it, which we cannot here reproduce.

Archives of Ophthalmology and Otology, vol. ii., No. 1.

Formation of Bone in the Eye. Dr. KNAPP.—His conclusions are:

Formation of bone in the eye is the consequence and final stage of a plastic inflammation of the capillary layer of the choroid. It invests the inner surface of the choroid, and continues, in the form of a transverse septum, through the anterior part of the vitreous humor, behind the ciliary body and the crystalline lens, without, however, involving these structures. The diseases which lead to ossific productions are chronic inflammations of the interior coats of the eye, called internal ophthalmia by the earlier, irido-choroiditis by modern writers. It should be particularly mentioned that chronic plastic inflammation limited to the ciliary body and iris, irido-cyclitis, which is not uncommon, and leads to the formation of false membranes before and behind the crystalline lens, has not been found to generate osseous tissue, nor has ossification been demonstrated as a sequel of iritis alone.

The diagnosis of ossification may be based upon the unyielding and hard condition of the posterior part of the globe, terminating about two lines behind the cornea, while the anterior region is soft, or at least impressible.

Simultaneous occurrence of calcification and ossification is frequent. Calcification may be diagnosticated by atrophy or degeneration of the iris, in combination with a shrunken, white or yellowish cataractous lens. As ossification does not involve the outer choroidal layers, nor the ciliary muscle and iris, it in itself is not to be dreaded as a cause of sympathetic ophthalmia. The latter can only result from irido-cyclitis supervening as a complication to ossific choroiditis. As long as an eye, in which ossification has been diagnosticated, remains free from irritation, and its fellow also, the removal of the former, for fear of sympathetic inflammation, is not indicated.

A Case of Glioma Retinæ, operated on at an Early Stage, and exhibiting some New and Peculiar Anatomical Conditions. Dr. Knapp.—He concluded that the very early removal of the whole organ was, therefore, a step approaching the practical solution of the question on morbid growths in general, and on intraocular tumors in particular—a question which, as a maxim, may be expressed thus: extirpate when the tumor is still a local disease, that is, before infection of the system has begun, and life will be saved.

Case of Pterygium superius. Dr. Knapp.—It resulted from an attack of blennorrhoic conjunctivitis in a child of eleven years of age, and seems to us more properly classified with symblephara, as he says most of the cases reported are.

Tumors of the Retina. Dr. Delafield.—He draws these conclusions:

1. The rule laid down by Hirschberg, that retinal tumors grow outward toward the choroid, has many exceptions.

2. The elements of these tumors only resemble the granules of the retina when altered by reagents and seen with low powers. When examined fresh and with high powers, they are seen to be identical with so-called lymphoid cells which compose so many new growths.

3. If we dismiss from our minds the superficial resemblance between the elements of these tumors and the retinal granules,

they at once take their place in the class of round-celled medullary sarcoma.

4. The variation in the size of the cell-body, and in the proportion of stroma in different parts of these tumors, is almost always found. This variation is the same which we find in most sarcomata, and is no reason why we should speak of a tumor as beginning as a glioma, and then becoming sarcomatous.

5. Not only the anatomy, but also the clinical history of retinal tumors, corresponds exactly with those of the medullary sarcomata.

6. The development of secondary tumors follows the rule laid down by Virchow for sarcomata, and occurs: 1. By continuous infection of the retina, optic nerve, and, perhaps, the brain. 2. By discontinuous infection, forming the choroidal, scleral, and episcleral tumors. 3. By metastasis proper, forming tumors on the bones, lymphatic glands, and liver.

The idea that the choroidal tumors are formed by continuous infection from the retinal tumors, and that the scleral and episcleral tumors are formed by continuous infection from the choroidal tumors, seems to be erroneous. In the very great majority of sections these tumors are evidently discontinuous. And even if in some few instances a scanty cell-communication is found between the two, it seems most probable, from what we know of other sarcomata, that this is a cell-growth posterior to the development of the secondary tumor. That, however, these secondary tumors, although discontinuous, are produced from cells which have wandered from the parent tumor, is possible.

Special Application to the Case of the Eye of Knapp's General Formulæ for Astigmatic Rays. Dr. Hay.

Iridectomia without Division of the Sphincter Pupillæ. Dr. Pope.—He has performed six operations, in cases which he says may come under the four following classes. The operation is of course optical, not therapeutic:

1. Those in which there is a central opacity of the cornea, and in which there has been acute or chronic internal inflammation of the eye, with or without adhesions of the iris to the lens capsule.

2. Those in which there has been perforation of the cornea with prolapsus of the iris, the pupil having suffered displacement, and being totally or almost entirely placed behind more or less opaque cornea. In case the cornea has suffered very decided changes in form, not amounting, however, to staphyloma, the operation is most strongly indicated. If there be present in the case iritis, or irido-choroiditis, which does not yield to treatment, it may be best to operate with division of the sphincter. If the pupil has been drawn to a very eccentric portion of the cornea by the prolapsus of the iris, it may still be best, in some cases, to excise the iris rather largely, without dividing its sphincter. When the whole pupillary margin has been engaged in the corneal opening, the operation for displacement, and that for iridectomia, after the usual method, are of course excluded.

3. Cases where there is diffuse opacity of the cornea, most marked centrally, and gradually diminishing toward its circumference, together with iritis or irido choroiditis, with or without adhesions of the pupillary margin to the lens capsule.

4. Cases where an extremely eccentric pupil may be required, and internal disease of the eye may exist. It may even be best in this class of cases, when no actual disease is present, but when there is doubt as to whether the iris will allow of extreme displacement of the pupil without inflammatory reaction. This condition might be found in the cases of old persons in whom the pupil was rigid and but slightly dilatable by the action of atropine. Prof. von Graefe recommended the use of Calabar bean in order to contract the pupil preparatory to the operation for iridectomia, in those cases of glaucoma where the pupil is evidently dilated. It may be in some cases beneficial in the proposed operation, when the pupil is large, and the pupillary margin free. The bean was not found necessary by Dr. Pope, to whose paper we refer for the technic of this operation.

The Light Streak seen in the Centre of the Retinal Vessels with the Ophthalmoscope. Dr. Loring.—In last year's Transactions of our Society.

Observations on Cases of Paralyzed Accommodation. Dr. Colsman.—He reports cases due to the following causes: un-

due exertion; straining the eye during work over a bright fire; Hm; sequel of *rubeola;* after angina; still another case from the same; accompanying mydriasis; syphilis; after iritis serosa from herpes zoster ophthalmicus; syphilis.

Kerato-conus and its Treatment. Dr. STEINHEIM.—Three cases operated on by Von Graefe's method. An addition to the already published cases, and, if they do not differ from the others, yet, in their details and especially in their results, are sufficiently worthy of mention to direct attention again to this method of treatment, and assist in giving it its proper place in the manuals of ophthalmology. The patient in one case drew the illustrations himself.

Annales d'Oculistique. May, 1870, *to June,* 1871, *inclusive.*

Retinal Anæsthesia. Dr. A. SICHEL.—By this term he means, not the absence of perceptive power in the retina, but the loss of transmission to the brain of the impressions perceived by it. In these conditions the retina perceives or receives the impression, but the patient is unconscious of it. Retinal anæsthesia generally occurs suddenly after some violent impression has affected the moral faculties of the patient a longer or shorter time. It will not appear at the time, but, sooner or later, some days afterward. There are no objective symptoms; the ophthalmoscope reveals nothing; phosphenes exist in every direction; the pupils act normally to light. Under examination with prisms the muscular action is perfect. Examination of the visual field affords us the only precise data. It is generally concentrically reduced, or we have scotoma, or, what is especially interesting, multiple variations. The patient's symptoms vary from slight amblyopia to complete amaurosis. Photopsy, photophobia, and achromatopsy, are observed in nearly every case. Often, vision is reduced to one-half or one-third. The disease may last a variable time, generally better and worse at times, as proved by the variations in the field of vision. Yet the affection seems to be quite benignant, always ending in recovery. As to treatment, this is to be especially directed to the general condition, and so determined by each individual case. Protection of the eyes from light, as much as possible, is the local treatment necessary.

Caries of the Orbit. Dr. JULES SICHEL.—Published after his death, by his son, Dr. Arthur Sichel. This is a very interesting and instructive memoir, which Sichel commenced in 1840. It makes some 55 pages in the Annales, which we would gladly quote from, had we room here. It is based on the absolute experience of Sichel, *père*, and would be quite acceptable published in English as a monograph.

Clinical Observations. By Dr. LEBRUN, of Brabant.—Epithelial tumor of the globe. Dermoid tumor of globe. Foreign body in the iris. Traumatic division of rectus internus five years previous; divergent strabismus; proraphie, cure.

Abscess of the Cornea. Prof. ARLT.—Translated by Dr. Schobbens, from vol. xvi., part 1, of Graefe's Archiv.

Table of Reciprocals, Dr. Schobbens, whom we should thank for the necessary calculations he has made for this table, by which we can readily calculate the effect of our combinations of glasses.

Pure (essentielle) Phthisis Bulbi. Dr. SWANZY.—A case observed at Graefe's clinique to be compared with others. Vide Arch. für Opth., xii., 2, p. 256; xiii., 2, p. 407.

Ophthalmia of Scrofulous or Lymphatic Children, and the Employment of an Ointment of Tannate of Lead. Dr. SCHOENFELD.—The ointment is prepared by triturating ʒ iss of tannate of lead with ʒ iij of fine oil and ʒ j of fresh lard, carefully washed. This the author speaks highly of in scrofulous ophthalmia of children.

International Tests for the Acuity and Range of Vision. Dr. BURCHARDT.—These have now been published, and we would call especial attention to them.

Clinical Report of Dr. HIRSCHBERG.—Embolus of central retinal artery. Sudden blindness in an infant of eight months. Several cases of *membrana pupillaris perseverans.*

Artificial Fistula of the Cornea when this is so altered as to cause Blindness. Dr. GRADENIGO.—He reports a case certainly successful enough to induce one to attempt likewise to cure the blind.

Ophthalmic Répertoire. Dr. WARLOMONT.—He wants others to follow him and print individual ideas about various

ophthalmic matters. He speaks of ocular inflammations; tincture of iodine with morphine in painful symptoms; local sublimate baths; ointment of balsam of Peru; lance-knives in iridectomy; how to remove suture-needles without separating the wound; circumcision of the cornea.

Strabismus. Dr. JAVAL.—The first and second parts of an article which will prove as practical as interesting. We commend its *study.*

Deafness in its Relations to Panniform Keratitis and Conical Incisor Teeth. Dr. DAVIDSON.

Some Forms of the Intermittent Affections of the Eye. Prof. QUAGLINO.—Translated by Dr. Delstanche, from the *Annali di Ottalmologia*, vol. i., 1871.

Retinitis Pigmentosa; its Locality and Nature. Dr. WINDSOR.—Translated from the Manchester Medical and Surgical Reports. The conclusions are—1. That in certain, probably in the majority of cases, the trouble commences and is localized in the external layers of the retina. 2. The affection is probably inflammatory, and the processes inflammatory or nutritive in the adjacent portion of the choroid, the deeper layers of the retina and optic nerve, vitreous and lens, are secondary.

Opistoblefari. Dr. ALBINI.—Metallic plates to slip under the lids and compress or retain the globe in staphyloma, etc. Also to protect the globe when caustic is applied to the lids, and likewise to keep off the pressure of the latter. To protect an ulcerated cornea. They may be used like artificial eyes, and, when there is any vision, glasses may be set in them. They can be used to apply electricity to the eyeball.

Some Considerations on Color-Blindness. Dr. GALEZOWSKI.—From his researches, based on the examination of more than seven hundred and sixty-six patients affected with internal troubles of the eye, he would make three varieties of chromatic trouble. 1. Pathological contrast of colors. 2. Blindness to colors. 3. Scotoma to colors. The first occurs from the abuse of alcohol, and is seen in certain varieties of alcoholic amblyopia. He saw it thirty-four times in one hundred and thirty-three patients, i. e., twenty-five per cent.

Pathological blindness to colors occurs with optic atrophy and amblyopia from alcohol, hysteria, or syphilis. In the

progressive atrophy of the papilla there is often noticed a peculiar variety of dyschromatopsy, and that is, blindness for green first, and after for red. Nearly all patients mistake green for gray, and, as the trouble increases, red becomes more and more dull, changing to brown and afterward black.

Hysterical amblyopia occurs most frequently in one eye, and that the left. The patients lose the power of distinguishing colors. Thus, yellow and rose appear white, while green, crimson, and blue, are black.

Optic neuritis, hemiopia, and other varieties of cerebral amblyopia, are often exempt from color-blindness. Of thirty-five cases he found chromatic trouble in but five; one patient could not tell yellow or blue, the other three confounded red and green. Inability to distinguish yellow indicated a syphilitic cause, and the optic neuritis was accompanied by choroiditis and syphilitic retinitis.

Albuminuric retinitis causes very irregular color-blindness; more often the patients recognize the principal colors, and only confound the secondary shades. Some remark a peculiar central scotoma. Glycosuric retinitis is rare, and produces color-blindness only when accompanied by atrophy of the papilla.

Congenital pigmentary retinitis does not generally cause color-blindness. Of twenty-one patients three only could not distinguish green, blue, and yellow; red appeared of a deep violet. This alteration of chromatic faculty is observed always at an advanced stage when the region of the macula lutea is invaded by pigmentary infiltrations.

In syphilitic choroido-retinitis the patients do not recognize yellow, the color last lost in cerebral atrophy of the papilla; blue and green are frequently lost; red often appears black.

Central Scotoma for Colors.—This is probably due to alterations at the macula, and to certain varieties of atrophy of the papilla. Retinal apoplexies occupying the region of the macula often temporarily or permanently compromise central vision.

In a number of cases of retinal detachment there was observed a peculiar chromatic trouble, namely, colored vision,

appearing either before the disease or during the first days of the detachment. The patients state that for some days, weeks, or even a longer time, they have seen every thing colored blue or violet. This is remarked most frequently during the first days of the trouble. Lights, the flames of lamps or candles, appear quite bright, and of a beautiful blue, sky-blue, or sea-blue. In fifty cases of detachment this was observed sixteen times.

Zehender's Klinisch Monatsblätter für Augenheilkunde, February, 1870, to May, 1871, inclusive.

Description of a New Ophthalmometer. Dr. EMMET.

Still another Ophthalmometer. Dr. ZEHENDER.

An Exquisite Case of Monocular Triplopia. Dr. DUFOUR. —Caused by an eccentric pupil, and two additional holes through the iris.

Exophthalmos from Orbital Aneurism. Dr. SHIESS-GEMUSEUS.—Treated with partial success by ergot-injections, digital compression, and ligature of the carotid.

Graefe's Peripheral Linear Section, Dr. Steffan, who now accepts Graefe's assertion that the largest lens may be removed through a cut of 4.5''' inner length, and 0.5''' height of flap.

Aphorism on the Success of the New Cataract Operations. Dr. STILLING.—He attributes this success to the cut being subconjunctival.

Acute Neuritis Optici with Tumor of Brain. Dr. SCHIESS-GEMUSEUS.

Strabismus Concomitans, Convergens, Intermittens. Dr. WAGNER.

Monocular, Vertical, Oscillating Nystagmus. Dr. ZEHENDER.

Chronic Spasm of the Eyelids. Dr. TALKOW.—This case was treated by section of the supraorbital nerve. The author concludes by saying that the patient, though still complaining of his endless trouble, yet admitted that the neurotomy was of inestimable benefit to him, and would have been of still more, had it not caused loss of sensation in the skin, and pain in the forehead. About a year after, he returned to the hospital with

muscular rheumatism of the lower limbs. Besides the muscular pain, there was an unpleasant drawing sensation in the extensors, in the fingers. The blepherospasm had disappeared, the right sphincter alone occasionally contracting. The left supraorbital region has, however, become more sensitive. The case and treatment are of interest to any one who thinks of neurotomy for the pain left in old people after an attack of herpes zoster ophthalmicus.

Astigmatism and Cranial Formation, Dr. Wecker, who reports to the Paris Anthropological Society, July, 1869, that: 1. "The anomalies of refraction, known as astigmatism, stand in direct relation with the formation of the skull, and this holds good in cases besides those where, as Donders said, the anomaly of refraction was excessive. 2. The formation of the eyes and indirectly of the skull determines the written characters." We may thus decide, from the old sculptured letters, the form of the eyes and of the skulls of those who cut them.

Congenital Choroidal Coloboma without Iritic Coloboma. Dr. Talkow.

Acute Conjunctival Œdema. Dr. Zehender.

Xanthelasma Palpebrarum. Dr. Hirschberg and Dr. Talkow.

Post-mortem Examination of an Intraocular Cysticercus. Dr. Sämisch.

Tumor of Back of Orbit, and Nasal Cavity. Dr. Rheindorf.

New Iris Forceps. Dr. Liebreich.

Cancer, starting from the Conjunctiva of the Lid. Gliosarcoma of the Retina. Dr. Hirschberg, with explanatory woodcuts.

Cataplasms in the Treatment of Acute Iritis. Dr. Schiess-Gemuseus, who reintroduces poultices, and says he finds them of great use in treating acute iritis, as also in secondary iritic processes and injuries, or cataract operations.

Ulcus Corneæ Serpens, Dr. Pagenstecher, who has tried with great success Sämisch's proposed method of treatment, by cutting through the corneal ulcer. His success others have not always met with.

Atrophy of the Optic Nerve, following Erysipelas of the Face.—Dr. Pagenstecher reports a curious case.

Subretinal Effusion in the Region of the Macula.—Dr. Betke, who thinks the whitish color left was due to fatty degeneration of the effused blood. Sudden total amaurosis of left eye; complete recovery. Intraocular glioma. Iridocyclitis with great changes in the visual power. Entrance of the whole lens into the anterior chamber after discision, spontaneous absorption without interference. Cataract with fluid vitreous; attempt at extraction, subsequent discision. Complete traumatic amaurosis, total paralysis of all the ocular muscles except the trochlearis, and partial paralysis of this. Purulent periostitis without exophthalmos, subsequent keratitis parenchymatosa. Sclerosis keratitis, iritis, episkleretis. Parenchymatous keratitis, subsequent iritis with corneal opacities from sclerosis. Sclerosis of cornea, partial right, total left; chronic iritis episkleritis. These are all clinical cases sketched by Dr. Schiess-Gemuseus.

Action of Calabar Bean in Diphtheritic Paralysis of Accommodation. Prof. Manz.—He advises his colleagues to try Calabar bean, for he says, although the spontaneous cure of accommodative paralysis may be generally expected, yet even with treatment by good diet, iron, and quinine, or by Jacobson's method by convex glasses, takes weeks or months, while the methodical local application of the bean acts so much more quickly as to entirely recommend it.

Acute Formation of Cataract. Dr. Ritter.—The opacity came on in a lad, aged nineteen, within a week, sufficient to cause the patient to grope about the house. Dr. Ritter suggests whether the lad's occupation, standing at a brick furnace, and exposed to blasts of intense heat, was not the cause. There was no disease of fundus present so far as could be ascertained.

Gummy Tumor of the Conjunctiva of the Bulb. Dr. Estlander speaks of this and other similar cases reported. Iodide of potassium had no effect. He says, as in syphilitic iritis, energetic inunction or other mercurial course is in place.

The Central-venous Retinal Pulse in Epilepsy and Allied Conditions. Drs. Köstl and Niemetschek.—Their observations tend to show that epilepsy is produced by cerebral anæmia, whether this is due to general lack of blood, dilatation of the art. thyreoidea sup., contraction of the carotid, stenosis of

the aorta, or lessened contractility of the heart's muscle. The anæmia is seen in the eye by blanching of the papilla. The increased motor activity and psychical exaltation following the anæmic condition, can only be explained by the increased flow of blood to the brain, and thus in the period of reaction there is an increased reddening of the papilla. This reactive hyperæmia is characterized by ectasia of the central vein, greater filling of the optic capillaries, and turgor of the retinal network.

The Blind in the Archduchy of Mecklenburg.—The combined numbers for October, November, and December, of 1870, give an interesting report of some one hundred pages, under the following heads: Official Report of the Number of Blind; Comparison with the Numbers in some other Countries; Deaths; Degree of Blindness; Ages; Causes; Relative Health of the Blind; Occupations; Blind Asylums; Possible Occupations, etc.

Tumors in the Neighborhood of the Eye. Dr. Horner.—These are reports of a series of tumors in the lids, conjunctiva, lachrymal gland, and orbit; of interest, on account of their rarity or course. The microscopic examination was made by Prof. Eberth. Fibroma molluscum of upper lid. Multipled cell, melano-sarcoma of the conjunctiva tarsi. Cancroid of the conjunctiva bulbi at an unusual spot. Fibroma, papillary of the conjunctiva bulbi. Carcinoma of the lachrymal gland. Periosteal fibroma of the orbit. Pigmented cavernous angioma of the orbit. Recurrent myxo-sarcoma of the orbit, metaplasia. Cysticercus in the orbit.

Arrangement of Prisms for the Better Measurement of Lateral Deviation in Insufficiency. Dr. Berlin.—By his arrangement, he holds that we have a limited but a sufficient series of glasses, within the range of which there are no greater sources of error than the method of trial offers. The use is more easy, leaving one hand free, and allows of much quicker measurement.

Neurosis Nervi Optici et Retinæ. Dr. Pagenstecher.—Great anæsthesia of the retina to white light; reflex irritability from opticus and retina, shown by peculiar appearances of color. Contraction of the visual field; spasm of accommoda-

tion. Cure by wearing blue glasses, and use of the constant current.

Double Isolated Rupture of the Choroid. Dr. TALKOW.—This makes the thirty-second so far reported in ophthalmic literature.

Gunshot-Wound of the Orbit without Injury of the Globe.

Case of Blepharospasm. Prof. SÄMISCH, of Bonn.—Contributions from ophthalmic practice during the war.

Phantasms during Sleep. Dr. GEISSLER.—An interesting article, in the closing sentence of which, the author says he cannot regard the phantasms as pathological, since they occur under perfectly regular diet, and absolutely clear mental action and activity. These being so little spoken of, would lead to the idea that they but very unfrequently occurred. This conclusion, however, is doubtful. We may readily convince every one that they have *muscæ volitantes*, and yet few know of their existence. And this very fact deterred Geissler from inquiring among the laity for phantasms. If they are physiological, then, when once recognized, they are with difficulty gotten rid of. This is by no means pleasant. Their artificial reproduction or increase might make among the laity, as with entoptic globules, a confirmed hypochondriac.

Iritic Exudation taking on a Peculiar Form. Dr. SCHMIDT.

Congenital Defect in the Lens. Dacryo-adenitis with Abscess. Dr. SCHIESS-GEMUSEUS.—In the first case there was an absence of one edge of the lens, as if a concave piece had been taken out, about one-fourth of the whole lens. Here the dilated pupil was free of the lens, looking almost like a lateral dislocation.

Glioma of Both Eyes. Dr. GEISSLER.—A child, six months old. There was atrophy of both optic nerves up above the chiasma. No convulsion or cerebral symptom up to the time of death.

Zehender devotes some twenty pages to analysis of the Transactions of our Society.

Royal London Ophthalmic Hospital Reports. Vol. i., Part 1. February, 1871.

Cases of Temporary Anchyloblepharon. Mr. WORKMAN reports from Mr. BOWMAN's Practice.—In a case of ectropion he conceived the idea that, if, after releasing the tissues, he were to unite the upper and lower lids for a time, he would obtain a better effect than by simply performing a plastic operation. The result fully realized his anticipations, as the band of union between the two lids prevented, to a great extent, the upper one being drawn up again, while the tissues were cicatrizing at the site of the plastic operation. The success of this proceeding has led to its being adopted in another class of cases—that of palsy of the seventh nerve, where the patient is unable to close the eye, which, in consequence, suffers from constant exposure. Here, too, the result has been very satisfactory. Mr. Bowman cautions, in this operation of uniting the eyelids for a temporary object, care must be taken not to interfere with the subsequent integrity of the tissues at the tarsal margin. If delicately done, it will be found sufficient to shave off a very thin slice of the opposed margins along the line of the Meibomian orifices, not including that of the cilia. Very fine threads should be used, and should extend beyond the bare surfaces, and take a good hold of the edge of the lid, so as not to cut themselves out. They should be removed on the fifth to the eighth day.

Lead Poisoning as a Cause of Optic Neuritis. Mr. HUTCHINSON.—Three good ophthalmoscopic pictures explain what he means and what he has seen, and to these, with the cases reported, we would refer our readers.

Punctured Wound of the Sclerotic, with Escape of Vitreous, treated by closing the Wound with a Suture. Mr. LAWSON.—He found that, if the sclerotic wound be closed by a single fine suture, and the escape of the vitreous be arrested, union of the cut edges will rapidly follow. The suture should be of the finest silk, and to each end of it a needle should be fastened, so as to allow of the silk being drawn through each edge of the wound separately, and from *within* outward.

Case of Sympathetic Retinitis Pigmentosa. D. A. ROBERTSON.—This he believed to be a true example of sympathetic ophthalmia, although the character of the inflammation differed from that which we usually observe resulting from sympathetic irritation; for while this disease is usually characterized by plastic inflammation of the iris, extending back to the ciliary processes and choroid, this had as its chief feature retinal inflammation with pigmentary deposit.

The Treatment of Sämisch's "Ulcus Corneæ Serpens." Dr. PAGENSTECHER.—He has tried this slitting through of the ulcer twelve times, and with almost unexceptional success. He deduces—1. That the ulceration on the cornea is arrested in its progress, and retained within its already acquired limits. The clouding of the cornea, so inimical to the sight, is thus reduced to the utmost possible minimum. 2. The base of the ulcer is cleansed, and becomes more transparent, and the existing infiltration, limited to one side, disappears totally after a few days. In one instance he noticed this to have taken place at the end of twenty-four hours, in another at the end of thirty-six hours. 3. Hypopyon, when such existed, or the particles clouding the aqueous humor were, to a very great extent, at the time of the operation, emptied out, and the absorption of such particles as remained behind was much accelerated. Hereby one danger, frequently unavoidable under other modes of treatment, is obviated—the organization of these elements; and the closing of the pupil thereby often occasioned, or its adhesion to the anterior capsule, is much diminished. 4. The irritation of the iris decreases rapidly; and in cases submitted to treatment at an early period, a very favorable mydriasis is seen soon to set in. 5. Ciliary neuralgia, when present, is completely allayed—if not immediately, within a few hours.

We would strongly recommend a perusal of this article of Dr. Pagenstecher to any one intending using Sämisch's method of treatment.

A Case of Amaurosis after Erysipelas. Mr. HUTCHINSON.—This very interesting case he prints in connection with two cases of

Atrophy of the Optic Nerve after Erysipelas of the Face, Dr. Pagenstecher, observed at the ophthalmic institution at Wiesbaden.

Miscellaneous Cases and Observations. Mr. HUTCHINSON.

Albinism (incomplete). Divergence and oscillation of the globes.

Albinism in a brother and sister. Defective vision and oscillation of globes in both. Hypermetropia.

Artificial eyes worn by young children (three years of age).

Failure of sight during lactation, and its meaning as a symptom.

Loss of accommodation from nervous shock.

Pyramidal cataract after purulent ophthalmia, but in one eye only.

Myosis and irido-plegia from brain-disease. Autopsy.

On the occasional intractable character of pustular ophthalmia.

Pyramidal cataract in one eye only, with corneal opacity.

Mydriasis and cataract in infancy in connection with syphilis. Subsequent dislocation of the lens into the vitreous. Excision of the globe.

Acute abscess in the lachrymal gland. Good recovery after incision.

Retinitis pigmentosa. Chronic rheumatic arthritis.

Case of congenital cataracts, with myopia and deafness.

Symmetrical ptosis in a child after purulent ophthalmia. Operation.

Case of extreme myopia. $V=\frac{20}{70}$ with $-\frac{1}{2}$.

Neuro-retinitis in connection with albuminuria and disease of the heart.

Atrophy of left optic disk, and deafness on the same side, after a severe blow on the head, which was attended for a time with hemiplegia.

Hereditary syphilis; severe ulcerations since childhood; characteristic teeth.

Keratitis; rapid improvement under iodide of potassium.

Giornale d'Oftalmologia Italiano. (Continued from our last year's Report, through the numbers for 1870, all so far received.)

Three Cases of Penetrating Wound of the Eye from Percussion Caps. Prof. BUSINELLI.—These well support the hope, in which we join, that the professor closes with, namely, that some law might prevent the sale of the poorer qualities of percussion caps, and that, in the perfection of fire-arms, these may be quite done away with. *Quod est in votis.*

Under what Circumstances the abuse of smoking Tobacco and drinking Alcohol produces Amaurosis. Dr. REYMOND.—He would treat cases much more actively than the mere abstinence from tobacco or stimulants. He uses also paracentesis of the aqueous chamber.

Cysticercus in the Vitreous. Dr. MARINI.—He decided it was a cysticercus tenuicollis of Rudolph.

Some Cases of Syphilitic Ophthalmic Disease cured by the Hypodermic Injection of Calomel. Prof. QUAGLINO.—Of special interest to the student of syphilography.

Removal of Capsule and Lens together in Cataract..—Prof. Gioppi continues his report on this, together with correspondence on the same from his Italian colleagues.

Prof. Cesare Paoli published in the "Sperimentale" accounts of the bad effects of petroleum-light on the eyes, and in the Italian Journal of Ophthalmology Drs. Calderini and Reymond publish two articles on protective glasses against the chemical rays in gas and petroleum lights.

Hemeralopia in a Woman operated on for Cataract, appearing spontaneously with the Effect of Sunlight. Dr. REYMOND.—This was an interesting case, showing that hemeralopia may be developed by other causes. Clinically it was shown that it was here due to the existence of minute blind points in the centre of the retina.

Quinine as a Topical Application in Affections of the Eyes.—Dr. FLARER follows Nagel's suggestions made at the Heidelberg Congress in September, 1869.

Lachrymal Fistula cured in Eighteen Days by Destruction of the Sac, with some Considerations on the Conditions in which Caustic is applicable. Dr. T. FRASSATI.

The Principles governing Inflammations of the Eye. Dr. ROSMINI.—This is the first portion of quite an extended article not yet finished.

Interpretation of Hemeralopia Aphorisms. Dr. REYMOND.

Electricity in Granular Conjunctivitis. Dr. RODOLFO.

Besides the articles enumerated, the Italian Journal of Opthalmology keeps its readers apprised of what is going on, by analysis of all the other ophthalmic journals published in English, French, and German.

Report of the Medical Society of Steirmark. 1869–'70.

Dislocation of the lens; exhibition of a patient. Dr. BLODIG.

Case of *carcinoma medull. bulbi* removed; patient exhibited. Dr. KELLER.

Three cases of prolapse of the iris exhibited by Dr. KELLER.

Treatment of acute ophthalmia blennorhagica. Dr. NINAUS.

Annali di Ottalmologia. Under direction of Prof. A. QUAGLINO.—This is a new Italian ophthalmic journal commenced this year, 1871, and published at Milan. The first number contains the following:

Some forms of intermittent ocular affections. Prof. QUAGLINO.—This has been pretty completely translated in the Annales d'Oculistique, vol. i., for 1871, p. 119.

Contribution to the Clinical History of Ocular Tumors. Prof. QUAGLINO.—These are: 1. White sarcoma of the choroid; 2. Detachment of the retina, followed by cataract, consecutive symptoms of glaucoma with rebellious periorbital neuralgia, enucleation, melanotic sarcoma of the choroid; 3. Squint and paralytic diplopia; consecutive atrophy of the papilla, with amaurosis and mydriasis; exophthalmos, enucleation of the globe, and extirpation of the tumor; myxoma of the optic nerve.

Molluscum Contagiosum. Drs. BIZZOZERO and MANFREDI.

Experimental Studies of Inflammation of the Lens. Dr. FORLANINI.—He gives only the results of his researches hereafter to be published in detail. He holds that a suppuration of the true fibres of the crystalline is possible.

Development of Optic Neuritis in Cerebral Affections. Dr. FLARER.—Dr. Forlanini follows this with his observations and experience *à propos* to Dr. Flarer's memoir on optic neuritis.

Formation of Bone in the Eye. Dr. Knapp. *New York Medical Journal*, February, 1871.—He, from observation of several cases, concludes that the origin of true bone in the eye may always be traced to plastic inflammation of the capillary layer of the choroid. Calcification may occur, and has been observed in every tissue of the eye, but ossification only in connection with the vascular chorio-capillaris. The nature of the ossific process in the eye is the same as that in connective tissue generally, the same as in the formation of bone from periosteum. The cells (white blood-corpuscles) and intercellular substance are poured out, the former in some places densely crowded; and then, with a clear line of demarcation, the infiltration with chalk begins. In some portions, the connective-tissue corpuscles are still preserved round, or nearly so, having few offsets; but the more the chalky infiltration advances, the more numerous the offsets become, communicating with each other to form the canaliculi. The round, movable, lymphoid cell, putting forth its processes and retracting them again, becomes, first, the jagged cell of the osteoid tissue; and, finally, the stellate cell—the real bone-corpuscle.

Contributions to Ophthalmic Therapeutics.—On the period of operating in Senile Cataract. R. B. Carter. Practitioner, March, 1871.

I cannot resist quoting his closing remarks in speaking of Graefe's new cataract-operation: "Besides influencing our judgment about the time for the performance of extraction, the new operation has greatly taken from the importance of several conditions that used to be regarded as almost prohibiting interference. In the days of flap-extraction, cough was a great bugbear, and frequently caused prolapse of the iris into the wound. Now that the piece of iris opposite the wound is excised, no such prolapse can take place, and cough is comparatively, perhaps absolutely, harmless. In the same way conditions requiring frequent recourse to an upright posture, such as asthma or irritability of the bladder, have very little influence upon the small section. Chloroform, which was shunned by many in flap-extraction for fear of the straining of sickness, may also be administered with good effect, and

protracted confinement to bed is no longer necessary. It follows that many of the fears and precautions with which cataract-extraction was once properly surrounded, may now be regarded as belonging to the past, and that they should be suffered to go the way of the circumstances in which they took their origin. Surgery can boast of few greater triumphs than the modern improvements in cataract-extraction; and these improvements have been brought about in the only right and sound way, by careful study of all the sources of failure in the old operation. It is now time that the public should enter upon the full fruition of the benefits that have been thus obtained for them."

Return of Vision after Atrophy of Optic Papilla. Dr. R. P. Oglesby. *Dublin Quarterly*, 1870. See also his previous publications in *Lancet*, August 22, 1868; Royal London Ophthalmic Hospital Reports, April, 1869.—He makes three periods in the process of recovery, to the third of which he would call special attention: 1. If the patient does not distinguish colors with a certain degree of assurance, it is rare that vision becomes reëstablished to any great degree. 2. If color-perception is pretty good, the patient may recover, most probably, a degree of vision that will enable him to go about alone, or do some coarse work. 3. If the patient distinguishes colors readily and with facility, entire recovery of sight is probable.

Leipsic Ophthalmic Dispensary. Its first five-years' report from Drs. Coccius and Wilhelmi.—We wish all ophthalmic hospitals and infirmaries would give us like experience of what has and is being done within their walls. We quote only what they say as to Graefe's peripheric linear cataract-operation: 1. Removing the cut from the cornea to the neighboring sclerotic tissue greatly lessens the danger of corneal sloughing, and thereby improves the chances of success. 2. In an eye without the lens, an iridectomy downward, if not too large, does not materially affect the visual perception as compared with a sound pupil. 3. A comparative glance at the two series of operations they report would incline them to trust most to a *preparatory* iridectomy rather than a contemporaneous one. In 127 cases, they lost but *two* from sup-

puration of the cornea, which they say is decidedly better than the results with the corneal flap-operation.

De l'Ophthalmie névro-paralytique. Dr. J. B. Coppez.—This name he gives to the group of changes that take place in the eye after section, paralysis, or irritation of the fifth pair of nerves. To be more precise, the ocular lesions are due not to an absence of the nervous influence, as the term "névro-paralytique" might imply, but to an irritating agent acting exteriorly on the anatomical elements of the cornea, or interiorly on the nerve itself, and thus, by means of the nutritive and formative irritation, an exaggerated cell-proliferation. He admits this last mode of action is denied by the majority of physiologists, who cannot produce it experimentally. But surgical pathology, in advance of experimentation, must needs admit the direct influence of the nervous system on nutritive phenomena, from the evidence of numerous and tested facts which careful observation daily accumulates. To the essay itself we would refer for proof of the above.

The Ophthalmic Phantom and the Ophthalmoscope as an Optometer. Dr. Franz Mohr. Wurzburg, 1870.—He recommends his apparatus to all interested in ophthalmoscopy, examination with the upright image, and optometry, convinced that it will greatly assist students and teachers in ophthalmoscopy, and enable them to employ Jäger's pictures where the living eye cannot be used for teaching or demonstrating.

Étude sur l'Iridectomie. Dr. Pomier. Paris, 1870.—He gives the diseases in which the operation is applicable and how it is to be carried out—as an optical effect, for prophylactic reasons, as an antiphlogistic, and still more, *in extenso*, its use in Graefe's peripheric linear operation for cataract. A *résumé* is in *Zehender's Journal*, May, 1870, page 156.

Ueber die therapeutische Wirkung des Atropin auf myopische Augen. Dr. Wosch. Basel, 1871.—An inaugural dissertation before the medical faculty of Basle. The author concludes that atropine is the only known remedy which, in a certain class of cases, produces a decided effect, namely, a pushing off of the far-point; in others, renders stationary a

process which is otherwise progressive, not only according to Donders's statement, but in accordance, also, with the experience of all scientific physicians. His method of employing atropine has the additional value of showing the patients and those around them that the accommodative efforts are what increase the myopia, and this often very rapidily. Thus they will be induced to avoid such hurtful influences, and so much is already gained. His plan also is devoid of danger when the eyes are properly protected against too great light.

Aside from the therapeutic value, the use of atropine is of worth in the pathological physiology of the eye. It proves that, in the large majority of cases, the myopia is the result of two components. Their relative value depends on the duration and amount of the myopia. The longer this has lasted and the larger it is, the greater is the import of the axial elongation compared to the cramp. The more recent the myopia, the more is it to be laid to the cramp. His experience would indorse this, namely, that atropine acts persistently only in young people, while in older myopes this does not hold. He considers his results of etiological value also. Donders was inclined to consider that there was in every case of myopia a congenital, generally hereditary predisposition, and he rejects totally a primary cramp of the muscles of accommodation. Of the author's patients, mostly of the educated classes, the majority denied having been previously myopic, and myopia could but seldom be traced to other members of the family. Of the cases, he holds, moreover, a majority were purely and simply acquired by constant accommodative effort. His results are only explainable by accommodative cramp, which, having commenced, caused, by long continuance, axial elongation. This last seems proved by the fact that in those cases where atropine removed only a portion of the myopia, this, therefore, being dependent both on cramp and axial elongation, the myopia began first to show itself at the time when accommodative effort was imperative.

Several new or newly-edited hand-books or compendiums have appeared, since my last report, to be here mentioned. This is not the place to criticise them, as the journal-reviewers take care of that much better. Schauenberg sends out

the fifth edition of his "Ophthalmiatrik," with 40 woodcuts, a volume of 350 pages. Rheindorf gives us the second edition of his "Handbuch der Augenheilkunde," with 23 cuts and 238 pages. Ignatz Meyer publishes the third edition of his "Compendium der Augenheilkunde," with 16 cuts and 358 pages. Schelske offers the first part, 202 pages, of a "Lehrbuch der Augenheilkunde." Schweigger, who has taken Graefe's place, has written a "Handbuch der speciellen Augenheilkunde," with 43 cuts and 538 pages. Tetzer's "Compendium der Augenheilkunde" has been issued by Dr. Grünfeld, with three lithographic plates and 488 pages. Klaunig has edited a "Compendium der Augenheilkunde," of 300 pages, dated Leipzig, 1872.

German students and practitioners at least seem, therefore, to be well looked after in the matter of hand-books. Mr. Soelberg Wells keeps his "Treatise on Diseases of the Eye" up to the times, and we would again recommend it as the best book for the English or American student or practitioner.

BOOKS, MONOGRAPHS, AND JOURNAL ARTICLES NOT NOTICED IN THE REPORT.

Das Auge und der Blick. W. Henke. Rostock, 1871.

Recovery from Double Optic Neuritis. Haynes Walton. Med. Times and Gazette, August 6, 1870.

Sympathetic Ophthalmia. Dr. T. R. Pooley. New York Med. Journal, October, 1870.

Anterior Epithelium of the Cornea. W. Krause, Reichert in Du Bois-Reymond's Archiv, July, 1870.

Ciliary Muscle. D. Wende. Ditto.

Lymph-Spaces in the Eyeball. G. Schwalbe. Schultze's Archiv, 1870. pp. 1–261.

Parts concerned in Accommodation. J. W. Hulke. Quarterly Microscopical Journal, October, 1870.

Circulation in the Eye. Dobrowolsky. Centralblatt, 1870. pp. 305.

Papers on Accommodation by Adamük. Centralblatt, 292, and Woinow, reviewed in Centralblatt, 478.

On Movement of the Iris. By Engelhardt. Würzburg, Untersuchungen iv., 296.

On Intermittent Irritation of the Retina. Pflüger's Archiv, iv., 214.

Parenchymatous Keratitis, associated with Acute Rheumatism. Spencer Watson. Lancet, October 22, 1870.

Traumatic Paralysis of the Visual Accommodation. Geo. C. Harlan, M. D., American Medical Journal, January, 1871.

Does Disease of the Cerebellum lead to Loss of Sight? British Medical Journal, October 14, 1870.

Parenchymatous Keratitis associated with Acute Rheumatism. Mr. Spencer Watson. British Medical Journal, October 22, 1870.

An inquiry into the Causes of the Occasional Failure of the Operation for Squint. Mr. Spencer Watson. Practitioner, January, 1871.

Injury to the Ciliary Nerves by a Blow. Mr. B. Carter. Lancet, December 3, 1870.

Three Cases of optic Neuritis. Mr. B. Carter. Lancet. November 5, 1870.

Zur Aetiologie und Prophylaxis der Myopie. Dr. Kämpf. Allgemeine Wiener Zeitung, Nos. 2–3, 1871.

The Ophthalmoscope in the Treatment of Epilepsy. R. A. Vance, M. D. New York Medical Journal, February, 1871.

Remarks on Divergent Strabismus. By Ed. G. Loring, M. D. American Medical Journal, April, 1871.

Account of a Severe Ophthalmia caused by Exposure to the Intense Light reflected from a Dazzling Surface of Snow. W. H. Gardner, M. D., U. S. A. American Medical Journal, April, 1871.

Paralysis of the Ciliary Muscle from Diphtheria. J. Hutchinson. Lancet, January 7, 1871.

Nævus of Orbit, Excision, Recovery. Mr. S. Lawson. Lancet, January 28, 1871.

Death by Chloroform during Enucleation. Mr. Power, Lancet, January 28, 1871.

Ueber die Ursachen des nicht selten vorkommenden Misserfolges der Operationen für Strabismus. Dr. S. Watson. Wiener Medizinische Zeitung, 10–11, 1871.

On the Color of the Eyes of the Newly-born. Dr. A. Wiltshire. Lancet, February 11, 1871.

A Very Rare Form of Strabismus and Astigmatism. Dr. Partridge. Medical Times and Gazette, March 4, 1871.

Opthalmoscopische Zeichen des Todes. F. Poncet. Allgemeine Wiener Zeitung, No. 2, February, 1871.

Albuminuric Retinitis. Dr. A. Robertson. Edin. Med. Jour., January, 1871.

Case of Renal Retinitis with Peculiar History as to Scarlet Fever. Lancet, April 8, 1871.

A New Operation for Entropium. J. McGraith. Medical Times and Gazette, March 25, 1871.

Retinitis pigmentosa in Two Brothers, the Offspring of a Marriage of Consanguinity. Rare Form of Vertical Nystagmus. S. Wells. Lancet, May 6, 1871.

Influence of the Sympathetic Nerve upon the Eye. Dr. Sinitzin. Centralblatt.

On the Various Operations for Lachrymal Obstructions and Tumors. Dr. A. Sichel. Bulletin générale de Thérapie, April and May, 1870.

Astigmatism as connected with the Form of the Cranial Bones Dr. Wecker. Gazette Médicale de Paris.

Antagonism of the Alkaloid of the Calabar Bean and Atropine. Recueil des Memoires de Médecine, de Chirurgie, et de Pharmacie militaire.

Causes of Myopia, its Frequency, and its Influence on Military Service. Gazette Hebdomadaire, Revue des Cours scientif., Sep., 1870.

Retinitis leucæmica. Dr. Becker. Gazette des Hôpitaux.

Diabetic Cataract. Ditto, ditto.

Alcoholic Amblyopia. Dr. Daguenet. Union Méd., 1870, No. 47.

Calomel in Ophthalmia. Ditto.

Effects of Abuse of Tobacco on the Eyes. Dr. Blatin. Bull. Gén. de Thér.

New Plastic Operation on the Lids. Dr. Gradenigo. Gazz. Med. Ital. Prov. Sarde.

Cure of a Case of Separation of the Retina by Puncture. Prof. Secondi. Nuova Liguria Medica.

Periphery of Descemet's Tunic and its Influence on Accommodation. Dr. Heiberg. Nordishk medicinskt Archiv, Bd. 2, No. 11.

Retinal Hæmorrhage foreboding Fatal Apoplexy. Dr. Berthold. Berl. klin. Wochenschrift, No. 39, Sept., 1869.

Investigations into the Lymphatics of the Eye and their Distribution. Dr. G. Schwalbe. Archiv für Mikroskopische Anatomie, Bd. 6.

De canali Peteti et de Zonula ciliari. Schwalbe. 1870.

Ueber die Nerven der Conjunctiva und Sclera. Helferich. Würzburg, 1870.

Musculus dilatator pupillæ in Man, Mammals, and Birds. J. Dogiel. Archiv f. Mikroscop. Anat., Bd. 6.

Phosphene besonderer Art. Dr. Szokalski. Zehender's k. Mon., p. 146. 1870.

Teleangiectasie palpebræ inferioris. Dr. Dobrzycki. Ditto, p. 147.

Wirkung der Calabarbohne bei Annomalien der Accommodation. Dr. Talkow. Ditto, p. 148.

Retinitis leukæmica. Dr. Roth. Virchow's Archiv, Band 49, pp. 441–446.

Behandlung der Conjunctival-Leiden mit Plumbum Aceticum. Dr. Schmidt. Berlin. klin. Wochenschr., No. 2, January 10, 1870.

Bijdrage tot de Behandling van sommige Gebreken der Oogleden. Inaug. Diss. Van Gil's. Utrecht, 1870.

Rendiconto della Divisione ottalmica dell' Ospedale di Pavia, 1868–69. Dr. G. Flarer. Milano, 1870.

Ueber die Grösse des ophthalmoskopischen Bildes. Dr. Schweigger.

Grundsubstanz und Zellen der Hornhaut des Auges. Schweigger-Seidel. Zehender. 1870, p. 175.

Aneurism in Sinus Cavernosus, with Paralysis of Third, Fourth, Fifth, and Sixth Cerebral Nerves. J. Adams. New Orleans Med. Jour., April 1870.

Conjunctivitis granulosa. Dr. Sämisch. Zehender, 1870, p. 181.

Melanosarcoma of Ciliary pressing into Anterior Chamber. Dr. Wells. Lancet, January 20, 1870.

Ueber Erweiterung des Thränen-Nasencanals bei Lungenkranken. Dr. Starke. Deutsch. Archiv f. klin. Med., 7. 2, pp. 212–217.

Morbus Brightii, chronic, with Retinitis. Memorabilien, Jahr 15. May 25, 1870.

Sudden transitory Blindness in an Adult aged eighteen. Zehender, 1870, p. 263.

Practical Suggestions for the Treatment of Lachrymal Diseases. C. R. Agnew. Am. Practitioner, January, 1871.

Cavernous Tumor of Orbit, Removal without Injury to Globe or Optic Nerve. Dr. E. L. Holmes. Chicago, Med. Jour., 1871.

Connection of Ocular Muscular Activity with Scoliosis. Dr. Ellinger. Wien. med. Wochenschrift, June 25, 1870.

Miseries of Myopes. Medical Times and Gazette, September 3, 1870.

Strychnin als Heilmittel bei Amaurosen. A. Nagel. Centralblatt für die medizinischen Wissenschaften, 55, 1870.

Our Eyes and how to take care of them. Dr. H. W. Williams. Boston.

Heilung einer durch Schussverletzung verursachten Amaurose mittelst Strychnininjectionen. A. Nagel. Berl. klin. Woch., 6, 1871.

Beitrag zur Lehre von der Choroiditis disseminata. Inaug. Diss. H. Fitzer, 1870.

Urœmische Amaurosen. H. Schmidt. Sep. Abdr. Berl. klin. Woch., 48. 1870.

De vulneribus oculi, etc. A. Coccius. Lipsiæ, 1870.

Albuminuric Retinitis. A. Robertson. Edinburgh, 1871.

Wirkung des Atropin auf myopische Augen. F. Hosch. Basel, 1871.

Melano-Carcinoma polyposum præconeale. Hirschberg. Aus Virchow's Archiv.

Conjunctivitis Diphtheritica. Hirschberg. Berl. klin. Woch., No. 4, 1871.

Neubildung des Hornhautepithels. Heiburg. Zehender, 1871, p. 116.

Observations on the Hygiene of Vision. Dr. R. B. Carter. Practitioner, 1871.

Objectif à Prismes pour l'Usage d'une Ophthalmoscope démonstratif. Wecker et G. Roger. Annales d'Oculistique. Vol. i., 1870, p. 286.

Nouvel Ophthalmoscope de M. Javal. Ditto, p. 287.

Nouvelle Pince pour la Pupille Artificielle. Liebreich. Ditto, p. 287.

Die Augendiätetik, oder die Kunst das Sehvermögen zu erhalten and zu verbessern. Dr. F. Ch. Jüngken. Berlin, 1870.

Ueber eine neue Art Stereoskopischer Wahrnehmung. J. B. Listing. K. Gesellsch. d. Wissensch. zu Göttingen, 1869, No. 17, pp. 431–455.

Ophthalmic Symptoms in Spinal Affections. Dr. A. Robertson. Edin. Med. Journ., 1870.

Moyens de Constatation de l'Amblyopie ou de l'Amaurose d'un Œil. Cuiguet. Annales, vol. ii., 1870, p. 68.

Extraction linéaire périphérique. Incision au moyen du couteau de Weber. Giraud-Teulon. Ditto, p. 60.

Exposé des différentes Méthodes de Traitement du Larmoiement, de la Tumeur et de la Fistule Lacrymales, et des Obstructions du Canal Nasal. A. Siebel. Ditto, p. 73.

Kyste d'un des Conduits Excréteurs de la Glande Lacrymale. Dubrueil. Ditto, p. 75.

Les Mouvements de l'Œil éclairés à l'Aide du Phénophthalmotrope. Donders. Ditto, p. 77.

De la Loi de Rotation du Globe Oculaire dans les Mouvements associés des Yeux. Helmholz. Ditto, p. 77.

Gliome ascendant de la Rétine, suivi de Mort. Arcoleo. Ditto, p. 77.

Klinische Erfahrungen und Studien im Zeitraume der Jahre 1867–'69. Steffan. Ditto, p. 86.

Traité des Maladies des Yeux. Galezowski. Paris, 1870, Part 1.

Diphtheritic Conjunctivitis, a Case of, Dr. Robertson. Edin. Med. Journ. 1870.

Coexistence d'Altérations Anéurysmales dans la Rétine avec des anéurysmes des petites artères dans l'Encéphale. Dr. Lionville. Annales d'Oculistique, vol. ii., 1870, p. 169.

Asthénopie par Spasme des Muscles Accommodateurs. Fano. Ditto, p. 172.

Sur la Structure de la Portion Ciliare de la Rétine. Manfredi. Ditto, p. 173.

Quelques Formes Rares de Maladies Oculaires. Gradenigo. Ditto, p. 174.

Der Markschwamm der Netzhaut. Hirschberg. Ditto, p. 267.

Troubles de la Vision dans la Leucocythémie. Penin. Ditto, vol. i., 1871, p. 69.

Operation de l'Entropion. Durand. Ditto, ditto.

Nouvelles Expériences sur l'Influence du Sympathetique et du Trijumeau, sur la Pression et la Filtration oculaires. Dr. Adamük. Ditto, p. 77.

Diseases of the Eye; attached to Holmes's Surgery. Dr. Dixon, p. 256.

Traité des Maladies du Fond de l'Œil et Atlas d'Ophthalmoscopie. Wecker et Jüger. 1870. Prix 35 francs.

Color Blindness. Dr. R. Derby. New York Med. Jour., March, 1871.

Modern Operation for Cataract. Dr. H. Derby. 1871. Boston Med. and Surg. Journal.

Hémorrhagies rétiniennes. D. E. Larrien. Paris, 1870, pp. 112.

Ueber Corelyse. Dr. A. Reuss. Wiener Med. Presse, No. 47, 1870.

Ueber Tätowirung der Cornea. Ditto.

Zwei Fälle von Sarkoma der Orbita. Dr. E. Emmert. Berlin, 1870.

Ein neues Exophthalmometer. Ditto.

Second Report Brooklyn Eye and Ear Hospital. January, 1871.

La Igiene degli Occhi. Dr. Monte. Napoli, 1870.

Hydrophthalmus congenitus. Inaug. Diss., Dr. Muralt. Zürich, 1869.

Ophthalmia militaris sive granulosa. Dr. M. Peltzer. Berlin, 1870.

Ein Wort der Erinnerung an Albrecht von Graefe. Prof. A. Graefe. Halle, 1870.

Albrecht von Graefe. Dr. A. Göschen. Berlin, 1870.

Was verdankt die Menschheit Albrecht von Graefe. Dr. H. Cohn. Breslau, 1871.

Das Auge und seine Pflege im gesunden und kranken Zustande. Dr. F. N. Heymann. Leipzig, 1870.

Diagnosis of Intraocular Sarcoma. Dr. Becker. Am. Med. Journal, July, 1871.

Loss of Accommodation from Nervous Shock. Hutchinson. Ditto. p. 280.

Failure of Sight during Lactation and its Meaning as a Symptom. Ditto, ditto.

Du Décollement de l'Hyaloide. Dr. Fr. Vacca. Rivista Clinica, 1870, fasc. 72.

Notes sur les Tumeurs de l'Orbite et principalement sur le Myxôme du Nerf Optique. Dr. A. Sichel. Gaz. hebdom., 8–9, 1871.

Études sur les Amblyopies et les Amauroses Syphilitiques. Dr. X. Gelezowsky. Arch. Génér. de Médecine, Jan., Fev., 1871.

De l'Extracture de la Cataracte. Dr. Droguet-Landré. Annales, 1871, p. 288.

Pathologie iconographique de Fond de l'Œil. A. de Mortema. Paris, 1870.

Atlas d'Ophthalmoscopie et d'Optomètrie. M. Perrin. Paris, 1870.

Atlas d'Ophthalmoscopie. R. Liebreich. Seconde édition. Paris, 1870.

Ueber das Verhalten der Doppelbilder bei Augenmuskel-Lähmungen. Dr. M. Woinow. Wien, 1870.

The Eye in Health and Disease. Dr. B. Joy Jeffries. Boston, 1871.

AN APPARATUS FOR CUTTING MICROSCOPIC SECTIONS OF EYES. By EDWARD CURTIS, M. D., of New York.

So-called "section-cutters," or "microtomes," of various kinds, have long been used by working microscopists for cutting thin sections of substances intended for microscopical examination. The advantage of these instruments is, that by their use more extensive sections can be obtained, and that too with greater certainty, and less waste of material than by the usual method of cutting by hand. Hence, the special occasions when a section-cutter comes into play are the following: First, when it is desired to get an unbroken section of considerable extent to show the mutual relations of comparatively distant parts; secondly, when a number of sections are wanted from a scanty amount of valuable material; and thirdly, when, as may be the case for various reasons, it is desired to cut into available sections the whole of a given area of tissue.

Now, all three of these considerations often peculiarly obtain in the microscopic examination of morbid eyes. For, in the first place, when we remember the complex structure of the eye, and the close physiological connection in it of anatomically dissimilar parts, it is plain that the study of regional pathology is often of the greatest importance, as in cases of tumor, or traumatic lesions. And, in such cases, the advantage of having extensive microscopical sections, that will show all the tissues of a diseased region *in situ*, is obvious. In the second place, the number of similar sections that can be cut through any part of special interest in a morbid eye is, of course, small, so that, if duplicates are wanted,

there is no material to waste. Thirdly, many lesions of the eye are so minute and scattered, that, to be sure of getting sections that pass through them, it is often necessary to cut the whole of a given area into sections, and examine these seriatim.

To secure these advantages, I have been at some pains to obtain an apparatus that should enable me if possible to cut sections, when needed, of an entire eye. None of the section-cutters supplied by dealers being of the right size to hold a whole eye, I had one made large enough to do so, and to this I have added various accessories, so that the whole forms practically a new piece of apparatus, which, from its successful working, I have thought worth describing. The apparatus is shown in the accompanying woodcut. It con-

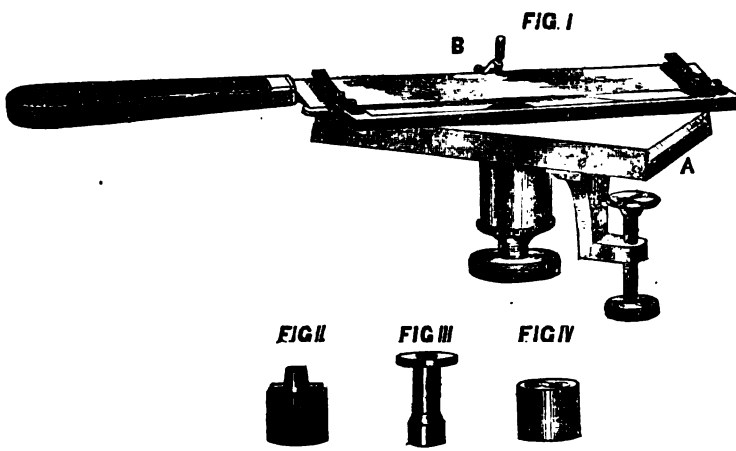

sists of the part *A* (Fig. 1), for holding the object to be cut, modelled after a form of section-cutter in common use; and of the cutting part *B*, after my own device, composed of a long straight knife held in a frame. The holder, *A*, consists of a heavy brass plate, faced with glass, six inches long by three and three-quarters wide, from the centre of which is sunk a hollow cylindrical barrel, one inch and three-quarters in depth, and one inch and one-quarter in diameter, inside measurement. Through the bottom piece of this barrel (which unscrews for convenience) works a screw-shaft, fur-

nished with a large milled head. The threads of the screw are fifty to the inch, and the circumference of the milled head is marked off into eighths, so that, if desired, the thickness of the sections cut can be measured. Attached to the under surface of the face-plate, near one end, is a screw clamp for fastening the apparatus to the edge of a table, so as to leave both hands of the operator at liberty to work the cutter. The principle of this "holder," as it might be called, is very simple. The object to be cut is first embedded in a cast of wax and oil, or paraffine, made to exactly fit the bore of the barrel; this mass is then pressed into the barrel, pushed upward by turning the milled head of the screw-shaft until it projects slightly above the level of the face-plate, when the projecting part is cut off by a sweep of the knife. Another turn, or fraction of a turn, of the milled head is then made, and again the projecting portion is cut off, this time as a smooth, even section of microscopic thinness. For a cutter, I had a straight knife made with a blade eight inches long, one and a quarter inch wide, and three-twentieths of an inch thick at the back, and with the sides concave like a razor. This I at first used by itself, sweeping it over the surface of the holder in cutting the sections, but I found that, from the length and thinness of the blade, it was apt to bend under pressure, and so fail to cut an even section, and also that the edge soon got dull from friction upon the face-plate. To obviate these difficulties, I conceived the idea of having the knife fixed in a frame, which should answer the double purpose of holding the blade stiff, and carrying it with the edge raised slightly above the level of the surface of the holder, so that the under surface of the arms of the frame should be the bearing surface upon the holder, and the edge of the knife be allowed to touch nothing but the tissue to be cut. The design of the frame will be seen at once from the figure; it is made of brass, and the knife is pushed into place from behind, under a couple of springs, which hold the blade down, and, when pressed home, the knife is kept from slipping back by a little fastening which is pushed against the back of the blade and then fixed by a turn of a quick screw. Besides the advantages of the frame in holding the knife stiff, and keeping its edge from

scraping over the surface of the holder, its weight and broad tread make its sweep much more steady and true than that of a light knife used by itself.

Such is, in brief, the mechanism of the apparatus, and I may remark, as proof of its efficiency, that I can often cut with it sections of an entire human eye, thin enough for microscopical examination. In preparing the tissue and cutting the sections, however, there are one or two points which it is necessary to observe in order to get the best results. To make these clear, it is, perhaps, best to detail the whole process of manipulation, although this is essentially the one in common use in preparing sections for examination in oil of cloves, or mounting in balsam or varnish. Supposing the object to be a morbid eye, this must, *immediately* after enucleation, be put into Müller's fluid,[1] and there left for at least three weeks. It is then cut open with a sharp knife or razor, and the halves soaked in water to remove the bichromate. This will take one or two days, the water being often changed. Such portion as is intended for cutting in the section-cutter is then to be further hardened in alcohol. In doing this I prefer to put it first into alcohol and water, half and half, for a couple of days; then into alcohol of full strength for an equal time, and then into absolute alcohol. In this last fluid the piece stays until hard enough to cut; the time required varies with different specimens, but is generally, with eyes, at least several weeks, as a very thorough hardening is necessary when the section-cutter is to be used. When ready for cutting, the piece is transferred to oil of cloves,[2] where it is allowed to stay until thoroughly impregnated with the oil: this takes from half an hour to several hours, according to the size and solidity of the specimen. The piece, however, must not be left indefinitely in the oil, as this slowly stains tissues an indelible dingy yellow, increases their index of refraction, so that the sections will look semi-opaque, even in Canada balsam, and may ultimately even spoil them for microscopical examination. When thoroughly soaked in oil of cloves, the

[1] Bichromate of potash, 75 grains; sulphate of soda, 25 grains; water, 6 fluidounces.

[2] The light-colored samples are best for use in microscopy.

piece is to be embedded for cutting. For this purpose two menstrua have been principally used, a mixture of white wax and olive-oil, in about equal proportions, and paraffine. I had been in the habit of using the former, although it has many disadvantages, having found paraffine, though in other respects preferable, too hard and brittle to cut well. My friend Dr. William Thomson, of Philadelphia, however, lately told me that he got excellent results from paraffine thinned with kerosene, its natural solvent. This I have tried, and have also used oil of turpentine and benzine for the diluent, and from what experience I have had I am now disposed to prefer thinned paraffine to wax and oil. Its most important advantage is that, so far as my experience goes, an accidental infiltration of the tissue with the melted paraffine itself is not so apt to ruin the sections for subsequent carmine-staining, as is a similar impregnation with wax and oil. The mixture I use is about one part of oil of turpentine or benzine to twelve or sixteen of paraffine. The embedding is easiest done as follows: In order to get a mould for the paraffine, which shall yield a cast of the right size to go into the barrel of the section-cutter, a solid brass plug (Fig. 4 of the woodcut) one inch high, and made to exactly fit the bore of the barrel, forms part of the apparatus. In one end of it an oval excavation is countersunk, to let the cast of paraffine take a firm hold of its surface, and to keep the same from turning round under the pressure of the knife. A strip of letter-paper, about two inches and a half wide is now wrapped tightly around this plug, the plug being in the middle of the strip, so that the paper projects at both ends. The part projecting beyond the flat end of the plug is folded down over it, and the opposite projecting cylinder of paper then forms a cup, with the excavated face of the plug for a bottom, of the exact calibre of the barrel of the section-cutter. Into this the melted paraffine is to be poured. A capsule containing paraffine or wax and oil, in considerable excess of the amount required for the embedding, is held over a lamp until the mass is just melted, when it is taken off and the piece of tissue dropped into it, and stirred about for a few minutes to rinse off the excess of oil of cloves. Then some of the melted material is

poured into the paper mould, the piece of tissue immediately transferred to the same, arranged in proper position, and the whole set aside to cool. The hardening may be hastened by standing the mould in a basin of water, the water, of course, not being allowed to come over the top. When perfectly cold and hard, the paper is unwrapped, care being taken not to loosen the paraffine cast from the brass plug, and cast and plug together are then pushed into the barrel of the holder, and each section is cut by a single sidelong sweep of the cutter. It is usual in cutting sections to flood the surface of the tissue and the blade of the knife with alcohol, so that the section, in cutting, floats freely over the blade. In this apparatus, however, from the great length of the knife, and from the fact that its edge is raised off the surface of the holder, this procedure is impracticable; but I find that I get even more perfect sections by the plan of cutting dry—that is, without flushing the surface of the tissue with any fluid. It will be seen in the figure that the knife is set at a slight angle in the frame; and this obliquity seems to give the section a tendency to curl away from the knife-blade in the cutting, so that in this dry process there is not only no more, but there is actually less danger than by the wet method of the section clinging to the blade in the cutting, and so getting torn. But here the preliminary impregnation of the tissue with oil of cloves is essential; for, were it in alcohol, the microscopically thin section would instantly become ruinously dry as soon as cut. The oil of cloves, however, from its very slight volatility, keeps the tissue of the section moist until it can be transferred to a fluid. But it will not do so long, and, hence, the moment a section is cut, it should be promptly seized, and dropped into fluid; and, if, from imperfect impregnation before embedding, the surface of the cut tissue looks dry, it should be *moistened* only by a touch of a camel's-hair brush dipped in oil of cloves. If the sections are not to be stained, they are dropped into turpentine as soon as cut; this dissolves the adhering wax or paraffine, very promptly if slightly warmed, and the sections are then ready for examination or mounting. If they are to be stained, they are put into alcohol instead of turpentine. This in a few minutes dissolves

out the oil of cloves, and the sections are then put at once into the carmine staining-fluid. For this I much prefer the solution of carmine in borax and water to the ammoniacal solution, and I obtain the best results from an intense staining in a strong solution,[1] and subsequent prolonged decolorizing with oxalic acid. Using the solution given in the foot-note, the sections are left in it for from half an hour to one hour, or until they are uniformly stained of a deep, purplish crimson. The staining-fluid is then poured off, and, *without any washing at all*, a saturated solution of oxalic acid in *water* is poured on. This instantly precipitates the dregs of the carmine in the dish, and changes the color of the sections to a bright scarlet. As soon as it has done so thoroughly, it is poured off, and a little fresh solution added. In this the sections are allowed to steep until the color is discharged from all but the cellular or protoplasmatic elements of the tissue. This takes, as a general rule, about as long as the original staining, but the time varies with different tissues; hence it will not do to trust to any rule, but the sections should be watched and the proper moment seized for stopping the action. This can, after a little practice, be told from the naked-eye appearance of the sections, but, if there is any doubt, one of them may be taken out and examined under the microscope. When the desired effect is produced, the oxalic acid solution is poured off, and the sections washed in several changes of water. They must not, however, be allowed to soak in water for any length of time, or the bright-scarlet color produced by the action of the acid will fade to a dingy purple.[2] If intended only for examination, the sections, after rinsing in water, are to be soaked in alcohol for a few minutes, then in absolute alcohol for another few minutes, then in turpentine (best slightly warm) till the alcohol is displaced and the fragments of wax

[1] Carmine, half a drachm; borax, two drachms; water, four fluidounces.

[2] The usual process is, after staining, to wash off the excess of the staining-fluid with alcohol, then treat with a saturated solution of oxalic acid in alcohol, and then wash from this again in fresh alcohol. From the great amount of alcohol thus consumed, I was led to try the water-process detailed above, and from comparative experiments I find it gives identical results with the alcohol process, and is, it is needless to remark, infinitely cheaper.

or paraffine still clinging to the sections are dissolved, when they may be examined either in turpentine or oil of cloves. If intended for permanent preservation, it is safest to let the sections, after the rinsing in water, soak for a few hours at least in alcohol, to thoroughly remove all traces of oxalic acid. Then, after passing through absolute alcohol and turpentine, they are ready for mounting in Canada balsam, or dammar, or other turpentine varnish, as may be preferred.

Such is the process to be followed in preparing sections with the use of the section-cutter, when the sections are intended to be examined in oil of cloves, or mounted in a turpentine menstruum. But it must not be understood as implied that this tedious process is to be followed as a matter of routine in all examinations of tissues where sections are required. Such is far from being the case, but to detail the various processes used in histological microscopy is not within the scope of this paper.

The woodcut represents two accessory pieces of apparatus that have not be enalluded to. These do not come into play in using the section-cutter for cutting eyes, but, as they make the instrument complete for other purposes, it is well to describe them here. Fig. 3 represents a secondary barrel with a half-inch bore, which can be screwed into the bottom-piece of the main barrel to diminish its size when any small pieces of tissue are to be embedded. It has a plug made to fit it similar to the large plug of the main barrel. Fig. 2 is a simple and ingenious contrivance, devised by Mr. Wale, the maker of the instrument, for holding hard substances which will bear squeezing, and which, therefore, it is not necessary or desirable to embed, such as cartilage, horn, wood, etc. It consists simply of a brass plug, made to fit the barrel of the section-cutter, hollow, but with the bore slightly conical, and with a screw-thread cut on its face. A few wedge-shaped pieces of soft wood of different sizes, roughly whittled out, complete the apparatus. Supposing a stick of wood is to be operated on, it is grasped between two of the wedges of the right size, being allowed to project somewhat above their tops, the whole pressed firmly into the conical bore of the plug, and with a turn or two the soft wood of the wedges is

tightly grasped by the screw-thread of the plug, and the object to be cut, tightly jammed between the wedges, is immovably fixed. Sections can then be cut from the projecting portion in the usual way. It may be remarked, in passing, that the cutter for anatomical tissues must not be used for hard substances. For these a strong, heavy knife or chisel of less brittle temper is to be employed.

In conclusion, it may not be amiss to state that the section-cutter and accessories can be obtained (to order) of the makers, Messrs. Hawkins and Wale, physical-instrument makers, Stevens Institute of Technology, Hoboken, New Jersey. Price $30.00, or, without the knife-frame, $20.00. The knife is a simple affair and can be made by any first-class manufacturing cutler from the dimensions given above. Mine was made by Mr. A. Eickhoff, 381 Broome Street, New York, price $3.00.

27 Washington Place, New York, *September*, 1871.

GENERAL SYPHILITIC INFLAMMATION OF THE EYE. By Francis Delafield, M. D., of New York.

It is well known that the introduction of the syphilitic virus into the system is frequently followed by inflammation of different portions of the body. The inflammations due to this cause are simple, hyperplastic, or produce a cellular new growth, to which the name of gummy tumor is usually given.

The eye is very frequently the seat of these various forms of inflammation. The iris and choroid are the portions which are most frequently attacked. The inflammation is simple, or forms small cellular new growths.

In rare cases, however, the inflammation becomes general; iris, choroid, ciliary body, retina, sclera, and cornea, are involved, and the production of new cells is so great that staphylomatous tumors of large size are formed.

The literature of such cases is scanty.

Arlt describes two cases of anterior staphyloma produced by syphilitic new growths from the edge of the iris and ciliary body; but no anatomical examination of the eyes was made.

Von Hippel (Graefe's Arch., XIII., 1) gives a full description of a case in which the iris, choroid, sclera, cornea, and retina, were involved, and a large staphyloma formed.

Two cases of this character have come under my observation:

Case I.—A negro, aged twenty-two, was treated in February, 1866, for primary and secondary syphilis. In the following April, his left eye became inflamed, red, with an abundant catarrhal, but not purulent, secretion. The sight of the eye, after this, became gradually worse and worse. In June, severe pains in the eye and temple supervened, increasing at

night. These pains continued up to the time of extirpation. In October the eye projected so much that the lids could not be closed. The conjunctiva was much thickened, and the cornea could hardly be distinguished from it. The eye looked as if it were the seat of an intraocular growth, which was pushing the cornea forward.

On October 20, 1866, the eye was removed by Dr. H. D. Noyes. It had been kept for several days in glycerine before I received it.

There was an annular staphyloma at the junction of the cornea and sclerotic around the entire circumference of the cornea. The sclera preserved its proper shape up to the edge of the staphyloma. The edges of the cornea were carried out with the staphyloma so that the anterior surface of the cornea was nearly flat.

The staphyloma was filled with a new growth, partly white and partly black, which also extended backward a short distance into the cavity of the globe.

The iris had disappeared in the new growth. The lens also could not be seen.

The choroid was thickened throughout, especially anteriorly by an increase of its normal pigment-cells.

The ciliary body was much thickened. It consisted of fibres, small round, oval and fusiform cells, and pigment cells; its anterior portion was continuous with the growth filling the anterior chamber. This growth near its attachment to the ciliary body was firm and composed of fibres, with round, and fusiform cells; near its centre it was softer, the cells more numerous, and many of them broken down.

The retina was detached in a funnel shape; its anterior edge was attached at the ora serrata, but was involved in the new growth. It was too much altered by the glycerine for minute examination. The retina was pressed together by a firm, hard clot situated just behind the tumor.

The cornea was infiltrated with great numbers of lymphoid cells. The anterior elastic lamina was intact and the anterior epithelium but little changed. The posterior elastic lamina had disappeared, and the posterior portion of the cornea was ragged and irregular, composed entirely of cells. Although

the growth in the anterior chamber was in apposition with the posterior surface of the cornea, it was not continuous with it.

The conjunctiva around the cornea was thickened by lymphoid cells beneath the epithelium.

So much of the sclera as formed the wall of the staphyloma was infiltrated with cells.

Case II.—The eye was removed by Dr. H. D. Noyes from a negro, aged twenty-four. In the spring of 1869 the patient contracted a chancre, which was followed, in two months, by secondary symptoms. He was first seen in November, 1869. At that time there was a large ulcer on the penis. He said that, twenty-five days before, a piece of his finger-nail accidentally got into his left eye and remained there about two minutes. A week after this the eye became painful and red, and a week later the right eye also became inflamed. When he presented himself, in the left eye the cornea was hazy; at the lower and inner margin of the cornea there was a staphyloma of the sclera; there was complete posterior synechia of the iris, with exudation in the anterior chamber; the conjunctiva and sclera were hyperæmic; tension was normal; there was bare perception of light.

In the right eye, the cornea was hazy; there were posterior synechiæ at the lower and outer edge of the pupil; the anterior chamber contained exudation; the conjunctiva was hyperæmic; he could count fingers. February 15, 1870, the right eye had improved. The left eye became more painful and began to protrude, until the lids could hardly be closed.

March 2d.—The left eye was removed.

The eye was divided by a section passing through the apex of the staphyloma.

The staphyloma was situated in the sclera opposite the junction of the ciliary body and choroid. The staphyloma and the anterior half of the globe were filled with a white mass. The sclera as it approached the staphyloma was pushed outward, thinned, and finally lost in the new growth. That portion of it which formed the staphyloma contained many lymphoid cells between its fibres, and at the apex of the staphyloma the fibres disappeared, and nothing but cells could be seen.

The conjunctival epithelium was but little altered. Around the staphyloma the stroma of the conjunctiva was much thickened and infiltrated with cells, its vessels were distended with blood.

The anterior chamber was filled with a blood-clot.

The iris was thickened; in its stroma were lymphoid cells and coagulated fibrine; the pupil was closed.

The choroid over the fundus was normal. As it approached the staphyloma it became thick and of a gray color. The thickening was due to the presence of lymphoid cells and coagulated fibrine. Near the apex of the staphyloma all the normal elements of the choroid disappeared, and nothing but round cells could be seen. No changes could be seen in the pigmented cells of the choroid, except that they had disappeared.

The ciliary body was everywhere thickened and filled with cells. Its periphery extended into the staphyloma, and was continuous with the new growth there.

The lens was small. Its capsule remained, partly filled with broken lens-fibres.

The retina was detached in a funnel shape; its anterior portion was lost in the new growth.

Of the white mass, which filled the anterior portion of the globe and the staphyloma, the anterior portions were composed of lymphoid cells, with a scanty stroma of connective tissue, the posterior portions of coagulated fibrine entangling cells.

These two cases differ both in the situation and character of the lesion. In the first case, the new growth has more of the character of a permanent new growth than of an inflammatory product. It is composed entirely of cells, in some places arranged in a thick fibrous stroma. The new growth originates in the iris and ciliary body, and fills up the space formed by the protrusion of the cornea. At the edge of the cornea the sclera is infiltrated and softened with cells so as to form an annular staphyloma.

In the second case, on the other hand, the growth is more distinctly inflammatory. The new cells are mixed with a plentiful exudation of fibrine. The iris and ciliary body are but little affected, while the choroid is involved over a considerable area.

12 West Thirty-second Street.

THE HALO ROUND THE MACULA LUTEA. By EDWARD G. LORING, M. D., New York.

THE actual demonstration of any new physiological or anatomical fact, however trifling, is, of a necessity, both of interest and value. Any sincere attempt to make such a demonstration, even if unsuccessful, may be of some future if not present advantage. It is with this hope, at least, that I now offer the following remarks:

The explanations of the glittering ring seen round the region of the yellow spot with the ophthalmoscope, as given by Liebreich, Schweigger, Schirmir, and others, have never been accepted by physiologists as conclusive; and Mauthner, in his recent work on the ophthalmoscope, brings an exhaustive review, of the many attempts to solve the problem, to a close, with the assertion that the phenomenon cannot be accounted for on anatomical grounds with the knowledge of the part now in our possession.



FIG. 1.

On looking at some drawings of the region of the macula, by Max Schultze, one of which I now reproduce in a diagrammatic form[1] (Taf. vi., Fig. 1), it occurred to me that the

[1] The outlines and curvature of the different layers are fac-similes of Schultze's original drawing. The scale is here, however, reduced one-half; *p* represents the pigment epithelium, and *i* the nerve-fibre layer.

effect in question might be produced by the same causes within the eye that often produce it in other places in nature, or, in other words, that it might be the products of reflexion and refraction from the combination of curved surfaces which enter into the construction of this portion of the retina.

As you will see, this region, as figured in the diagram (Fig. 1), bears in its formation a strong resemblance to a shallow cup, of which the rim is represented by a convex and the bowl by a concave surface. If we look upon these curved surfaces as mirrors, they would each have their foci, one lying behind the other in front according to their respective degrees of curvature. And if light should be thrown perpendicularly against such a combination of curves, the apex of the outside rim or convex surface would, from well-known optical laws, appear illuminated, while the inside or concave surface would appear more or less in shadow. Thus we should have the effect of a darker centre, surrounded by an illuminated edge.

In order to demonstrate this in its application to the retina, two eye-phantoms or cameras were made, precisely alike in every respect. At the bottom of one a concave metal mirror, belonging to an ophthalmoscope, was placed to represent the retinal surface. Another mirror, precisely like the first, was then taken, and a very slight depression made in it by carefully pounding down the region immediately about the hole in the centre, with a rounded chisel-handle. As the implement was made of wood, a shallow indentation was made without cutting into the substance of the mirror. This was placed at the bottom of the second camera, and represented, in a rough but sufficiently exact way, the cup-like cavity shown in the drawing, as belonging to the yellow spot. The two cameras were then examined with the ophthalmoscope.

The first gave a perfectly distinct image of the mirror at its bottom, exactly as we should expect to see it, with the hole in the centre, with clearly-defined edges; but in the second camera the hole was surrounded by a brilliant circle, corresponding exactly to the limits of the depression, while the central portion seemed to be somewhat in shadow. An idea, although a very rough one, of the effect can be formed from the

following diagram, in which *A* represents the camera, in which the mirror had been left in its natural condition, and *B* the one in which the slight central depression had been made.

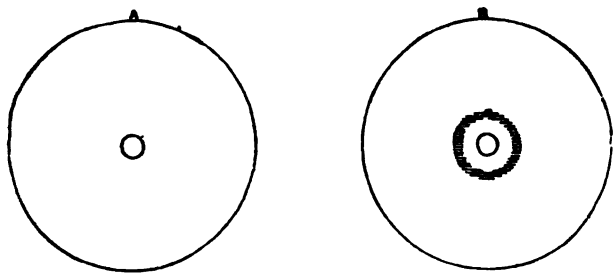

Fig. 2.

In showing this experiment to a *confrère*, I was told that, striking as it was, it could not embody the right explanation of the affair, inasmuch as there was, in fact, no such depression of the entire region of the macula as I had been led to suppose from Schultze's diagram; that the only depression in the whole surface of the retina was confined to the fovea itself; and that this, as was self-evident, was entirely too small to give so extensive a reflex; and, finally, that Schultze's figure was merely a diagrammatic representation of the fovea very much enlarged.

If this is true, then, of course the experiment, and with it the explanation, falls to the ground; and it cannot be denied but that Henle distinctly states that the only depression in the whole surface of the retina is just at the fovea centralis itself. But it is by no means so certain that the excavation pictured by Schultze is meant to represent only that of the fovea, or that it is an exaggerated and diagrammatic representation for the mere purposes of explanation. On the contrary, he states distinctly that "all the layers, excepting the rods and cones, are copied exactly from a section through a normal human retina; the drawing, as here represented, shows the macula lutea without plica, *consequently as it actually is in life*" (*loc. cit.*, p. 109).

Schultze has given, too, the scale on which the drawing was made, namely, an enlargement of one hundred and ten times. If we now measure, in his diagram, the extent of sur-

face on the retina which is stained yellow, and which it is to be supposed was meant to represent the extent of the region of the macula lutea, we find it is 158 millimetres. This, reduced to the normal size, would give for the measurement of this region 1.4 millimetre, which corresponds to the average dimension, as determined by the majority of observers. Again, if we suppose that Schultze meant the depression to be confined solely to the fovea, and under this supposition we measure the distance across the actual mouth of the cavity as figured in the diagram, we find it is equal to 110 millimetres, which, reduced, gives an actual size of 1.0 millimetre, which is five or six times as large as it is in the normal eye, so that it is not possible that the cup-shaped depression is meant to represent nothing but the fovea. There can, indeed, be no doubt but that Schultze meant to give in his picture an exact counterpart of this region of the retina as it really is in nature, and, if so, there is no reason why the conditions represented in the experiment should not be a sufficiently exact imitation of those in the actual eye.

It must be conceded, however, that Schultze's views and Henle's are diametrically opposed. Can it be that this cup-like depression varies in different eyes, both as to extent and depth, so that in some it shall be limited to the fovea alone, and in others extend, getting shallower as it goes, even up to or near the boundary-line of the entire macula? This would account for the presence of the ring in some eyes, and its absence in others, and its frequent and not inconsiderable variation when present in size and shape.

Bearing in mind that at the macula lutea the nerve-fibre layer ceases to exist as such, and that the nerve-fibres make a peculiar bend here, it occurred to me that a difference in level might be occasioned, which, varying in different cases, might still be sufficiently marked in many eyes to give the effect in question.

In order to show how slight an inequality in surface would produce the phenomenon, and to determine whether it could be possibly produced by the above condition, the following experiment was made:

A piece of thin and perfectly pure tin-foil, such as dentists use, was selected, and its thickness carefully measured

under the microscope; this was found to be only $\frac{1}{700}$ of an English line. A flat, circular disk of plane glass was then prepared. A small, circular hole was next cut in the centre of a piece of the foil, which was left somewhat larger than the disk of glass. This latter was then covered with the foil by carefully folding the surplus quantity over the edges of the glass till the surface of the foil was gradually worked perfectly tight and smooth, so as to give finally much the appearance of a flat, thin button, covered with silver, and having in its centre a circular hole, through which the glass was visible. As the thickness of the foil was $\frac{1}{700}$ of a line, the depth of the hole in the centre must be the same.

A second piece of foil, having, however, no hole in its centre, was now stretched as above, over the first covering, and the surface was then gently rubbed till the upper covering had moulded itself under the pressure into the hole in the covering beneath.

The effect of this was to give a perfectly smooth surface, with a very slight depression in the centre. The depth of this depression, even if it was equal to that of the hole itself before the second covering was put on, could not be more than $\frac{1}{700}$ of a line, but it must be in fact much less, as it is evident that the depth must decrease with each covering. The disk was then fitted to a camera and observed with the ophthalmoscope just as in the former experiment, and with precisely the same result. The glittering ring, marking the boundary of the depressed region, was present in a marked degree, and showed a very striking resemblance, both in size and appearance, to that seen in the actual eye.

We have taken, it must be borne in mind, the depth of the depression as $\frac{1}{700}$ of a line, a difference in level which seems almost inappreciable, and which is, in fact, three times less than the thickness of the single layer of epithelial cells between the retina and choroid. Now, as the nerve-fibre layer is, at the distance from the optic disk, corresponding to that of the macula, $\frac{1}{50}$ of a line thick,[1] we should, even if we took the lowest estimate, have tissue enough in the thickness

[1] Ritter. Wecker's Études, t. ii., premier fascicule, p. 51.

of the nerve-layer alone to make a depression fourteen times as deep as that which produced the effect in the phantom.

And, if for any reason whatever, such as the bending or overlapping of some of the fibres as they enclosed the macula, and the ending of others concentrically around it, a difference of level of even the slightest degree was formed, then the effect might be produced through the nerve-fibre layer alone, without taking into consideration the thinning of the other layers of the retina at this place.

But it may be said that if this difference of level did exist, it ought, however slight it might be, to be seen with the microscope. This we readily admit ought to be the case if we could get sections of the part as it really exists in nature, but it must be borne in mind that it is almost hopeless to do this, on account of the distortion of the part by the formation of the so-called plica at almost the very moment the eye is opened, and this too, letting alone the disturbance of the tissue which would necessarily follow by even the most delicate manipulation, and letting alone, too, the minor difficulty of even getting a section directly through this region.

It must, too, be admitted that, with all the labor and talent which have been expended on the anatomy of the retina, we still know little about that of the nerve-fibre layer in the region of the macula. Under these circumstances may not the ophthalmoscope have a voice in explaining a phenomenon which is in strict accordance with physical laws, and which, outside of the eye, can only be so explained?

How far the peculiar arrangement of the anatomical elements of the different layers which enter into the construction of the part, and which go to make this inequality of level, contributes to the effect, we will not attempt to determine; it is the difference of level itself which we would insist upon as the essential factor in the production of the phenomenon.

There are one or two additional points which go to prove that the effect is due to difference of level, one of which is the fact that we often get a reflex of precisely the same character along the vessels; and we know from the microscope that these often project, though still covered with the nerve-fibres, above the level of the retina.

A second argument in its favor is the peculiar reflex seen at the fovea centralis, with the *upright image*, first pointed out by Coccius, and the usual shape of which, as you are aware, is that of a horseshoe, which changes from side to side according to the movements of the eye.

Now, we know that the fovea is described by most anatomists as a narrow fossa with pretty sharply-descending walls, and the shape of the reflex is just such as would come from a narrow-mouthed pit; for, while one side was turned so as to catch the light and reflect it, the other edge would be turned so that no reflex would come back from it, consequently we should have a crescent or half-moon-shaped reflex, changing its position as it really does with every movement of the eye.

The reflex of the fovea, even when present, is not, however, always of a crescentic shape, for it sometimes has the appearance as if it were only the segment of a small circle which was illuminated, or as if the fossa were a triangular one, and light were reflected from only one side of it, in which case the reflexion streams out something like the tail of a very minute comet; again, it has the appearance of a delicate phantom-like veil stretched, in part, or entirely, across the fovea; and, then again, there is no reflex at all, and the fovea looks like a small yellow dot, varying in size and shape, and has the appearance as if it had been flecked directly on to the surface of the retina with a brush.

May not these differences in effect of the reflexion, when present, be due to variations in anatomical construction of the part, and principally to differences in shape and depth of the excavation; and, when the reflex is absent, may not its absence be due to the want of any difference in level?

These are questions which the anatomists must answer, but one thing is certain: where there are such marked variations in effect, there must be also marked variations in cause.

In regard to the fact which Mauthner emphasizes as so curious and unaccountable, that we only get the halo round the macula with the inverted image, and never, under any circumstances, with the upright, I have only to offer in explanation that we should bear in mind that the apparent diameter of the region of the yellow spot, under the enlarge-

ment of the upright image, would be, on the average, about one inch, which is much too large for the entire circuit to be in view at once; and furthermore that, do what we will, the illumination with the upright image is never so strong, or so concentrated on a small surface, as with the inverted.

But I would add, while admitting Mauthner's statement as almost a law, that occasionally I have got a distinct but very faint segment of reflection which I could make play about in that portion of the retina where I imagined the boundary circle of the yellow spot should be.

A SCHEME TO AID IN EXAMINING AND RECORDING CASES OF FUNCTIONAL TROUBLE OF THE EYE. By Dr. Henry D. Noyes, New York.

For about eight months I have been using a printed form in keeping records of cases of functional troubles of the eye. I found such a device desirable, to insure regularity and completeness in the examination, and for convenience in preserving notes. I have been able to put my records in a form which admits of easy reference and classification, and in doing this have secured the minimum expenditure of time.

In framing a blank for this purpose, I have included only certain classes of cases—viz., those which came under the designation of asthenopia, using the word in its widest and former significance. I thus include errors of refraction and of accommodation, and muscular disturbances.

It may not be deemed needful in every patient to ascertain all the data for which the scheme makes provision; and, on the other hand, there may be many noteworthy facts in addition to what are provided for. In the one case, certain items in the scheme will be left vacant, and, in the other case, the filled-up blank may be used as part of a full account of a case. The plan has commended itself to my use both for utility and convenience, and I venture to explain it for the benefit of any who may choose to adopt it, or may find it suggestive of some more perfect form.

I may remark that I have kept notes of one hundred cases by this method.

The blank form[1] is as follows:

Diagnosis.

.....18.....

M.....

Refraction.	R.	V. =	*Both.*	=
	L.	V. =		

Accom. =	Relative A. at....in. =	±		
Muscles. *Adduct.* at.....in. =	°: with v. d.	at...in. =	°	
" with....at....in. =	°: with v. d. and...at...in. =	°		
Abduct. at.....in. =	°: with.....at...ft. =	°		
" with....at....in. =	°: with v. d. and...at...ft. =	°		
Linear deviation at....in. =	: at.....ft. =			

Ophthalmoscope.

History and Treatment.

The explanation of the above is as follows:

I put the diagnosis at the top to serve as a title for reference; then comes the date, and then the patient's name, occupation, age, nativity, and I often add weight.

The first inquiry respects the state of refraction in each eye singly, the letters R and L standing for right and left, and the space beyond serving to record the number of the glass needed to correct distant vision, if any be required. This applies to astigmatism as well as to other errors. The letter V designates the visual acuteness conferred by the glass. I sometimes find the sight, with both eyes together, sensibly more acute than with one alone, and indicate it after the word "both." As a sample of this kind, I quote the following:

R. = — 8 spherical—48 cylind. axis 155° v = $\frac{20}{30}$ Both = $\frac{20}{30}$?

L. = — 8 spherical—48 cylind. axis 155° v = $\frac{20}{30}$

The last interrogation-mark shows that, while with both eyes vision was better than with one, the difference was not

[1] The actual schedule occupies a larger sheet than is allowed by the size of this page, and a copy is enclosed for trial; more may be obtained from the publishers.

equal to one gradation of Snellen's test-type; patient could read some letters of Snellen xx at 20 feet, but not all of them. A patient who needed no correcting-glass would be marked E. for emmetropia. If, in making this examination, a solution of atropia has been used, the letters *atr* may be put into the space.

The next step in the inquiry relates to the capacity for near vision, in other words, the function of accommodation—which is indicated by an abbreviation of the word. The relative accommodation may also be subject of examination, and the blank means what positive and negative glasses can be worn in reading Snellen $1\frac{1}{3}$ at a certain number of inches. Thus, for a given case, a patient of seventeen years old, the record stands: Accom. = $\frac{1}{4}$. Relative A at 8 inches = $\frac{+20}{-18}$. He has myopia $\frac{1}{36}$, and the test of accommodation is for both eyes together.

I take up next in order the function of the muscles of the eyes—the power of adduction and abduction—as tested by prisms.

Beginning with adduction, the first point is, what is the strongest prism, with horizontal axis and angle inward, which the interni can overcome, the test-object being at a specified number of inches distant? The next line below provides for a few cases in which a positive or negative glass may be requisite in testing the adduction.

On the right half of the line may be recorded what happens when a prism with vertical axis causing "vertical diplopia" (v. d.) is placed before one eye and the test-object at a specified distance. In such a case, a patient may be able to overcome a prism with its angle inward, and keep the two images perpendicularly over each other. The fact and the number of the prism are stated by putting down the number of the prism with the positive sign + prefixed to it; thus, adduction with v. d. (vertical diplopia) at 14 inches = + 8°. If unable to overcome any prism with vertical diplopia, but simply preserving equilibrium of the muscles, it is stated by writing = 0°. But, if the vertical diplopia is likewise crossed diplopia, and, to bring the images to perpendicularity, requires a prism before one or both eyes, with its angle outward, this fact is denoted by writing = − 10°. This

means that, for the distance of the test object, there is a degree of *insufficiency* of the interni, expressed by a prism of 10 degrees. By using the sign + to express positive power, and the sign — to denote defect of power, the long word "insufficiency" may be avoided, while the fact can be clearly expressed. Sometimes positive or negative glasses may be added in making this test, and that the line beneath provides for, viz., adduction with v. d. and (— 12 or + 16, for instance) at 12 inches = — 6°, which means that, when these glasses are worn, there appears an insufficient adduction of 6 degrees.

It may be well here to describe the way which I have found most convenient for making these examinations. I have had a light frame or apparatus of wood made, whose plan was adopted from one of the simple forms of stereoscope. If one of these stereoscopes, which carries the picture in a transverse bar, sliding up and down a central stem, should be supplied, in addition to its prisms, with receptacles for slipping in two pairs of glasses, the thing I use in examining the function of adduction would be made. The stem on which the test-object slides is eighteen inches long, and is marked off in inches and half-inches, the measurement being from the face of the patient. There are slits, or pockets, for two pairs of glasses, besides the prisms. Two pairs of glasses are provided for, so as to permit the use of a colored glass, and also of a positive or negative glass. The prisms are held by little brass catches, and easily slip in and out. The whole is held by a knob underneath the stem. I find this frame more convenient than any spectacle-frame. It is available for testing the accommodation as well as the muscular power by putting on the sliding bar a card, on which type from Snellen's book has been pasted. It is very easy to slide this up and down the stem to any point, and the distance at which the print stands from the eye is at once read off on the scale. The test-object for adductive power, which has in my practice displaced others, is a white dot and line painted on a black card. The dot and line are of this form: I prefer this to either the dot alone or to the dot with a line both above and below. The line, as I make it, enables a patient to tell

whether the false and true images are really perpendicular; by having it only on one side and short, the prism being 10° or 12°, the images are always apart from each other, and the patient is not tempted to put forth efforts at fusion of the images, which I have noticed to occur when the prolonged line of one image overlaps the other. A white image on a black surface is more conspicuous than black on white, and, when a red glass is put before one eye, the difference in the two images is instantly recognized. A case illustrating the points above set forth as to the adductive power is the following:

Mr. C. B., twenty-nine, farmer, Red Bank, N. J.:

R. +12 spherical—48 cylind. axis 70° v=$\frac{20}{20}$.

L. +12 spherical—36 cylind. axis 90° v=$\frac{20}{20}$.

Adduct. at 14 inches=36° : with v. d. at 14 inches=0°.

Adduct. at 14 inches with +7=8° : with v. d. and +12 at 14 inches =—4°.

Adduct. with v. d. and +7 at 14 inches =—16°.

The employment of convex glasses, which neutralized his hypermetropia, elicited a slight amount of muscular insufficiency, which remained latent to trials by prisms without glasses; furthermore, by strengthening the glasses so as to suspend accommodation, the relaxation of muscular energy became still more remarkable. In treating the case, glasses which corrected the refractive error relieved the pain, and have been satisfactory for six months. In cases of myopia and muscular insufficiency, it is often needful to learn the state of adduction with concave glasses as well as without them.

Investigating *abduction:* the first inquiry is simply its amount at the usual reading distance without glasses, then its amount with glasses at the same distance. The next is abduction with parallel visual lines, that is, at twenty feet, and after this at the same distance when vertical diplopia is produced. These inquiries furnish a full exhibit of the state of adduction and abduction from which to draw suitable therapeutic deductions.

"*Linear deviation*" at a short distance—three or four inches—is obtained by concealing one eye while the other

fixes on an object at the given distance in the median line, and, after removing the screen, by measuring in the lower lid the number of lines which the previously-covered eye has turned away from the proper line of convergence. If the object fixed upon be at some feet distance, and one eye deviates, the case becomes one of actual diverging strabismus.

In the above schedule I have not thought it worth while to consider the degree to which each eye may be implicated in the defect. If an operation is to be performed, each eye must be tested, so that, if but one muscle is to be operated on, the proper eye may be selected in case there should be a choice. Very often it is of little moment which eye should be chosen.

For ophthalmoscopic appearances no large space is designated, because usually there is not much to be described. Finally, the history of the case, other symptoms, and the treatment, may be recorded.

I file away the loose sheets in pigeon-holes, and, when they accumulate inconveniently, paste them into a letter-file with an index.

I do not pretend to submit every case of functional trouble of the eye to the minute investigation which is here laid out; such labor is impracticable, and many times unnecessary. But, when a thorough examination is to be given, a proper method is observed, and full notes are quickly taken.

73 Madison Avenue.

ON THE TABLES GIVEN BY LORING AND KNAPP TO SHOW THE DISPLACEMENT OF THE RETINA IN AMETROPIA. By Dr. O. F. WADSWORTH, Boston, Mass.

IN a "Report on Ophthalmology for 1870," which appeared in the *New York Medical Journal*, February, 1871, the writer, in the course of a notice of Knapp's paper, "The Influence of Spectacles on the Optical Constants and Visual Acuteness of the Eye" (Arch. of Ophthal. and Otology, vol. i., No. 2), called attention to an apparent discrepancy between the table given by Knapp[1] to show the amount of displacement of the retina in given degrees of ametropia, and a table which had been given by Loring for the same purpose (*American Journal of Medical Sciences*, April, 1870, p. 335).

These tables may be of practical importance, as enabling us to determine with some accuracy the amount of elevation or depression of different portions of the fundus, and so assisting us in diagnosis, in cases of intra-ocular tumors, for instance. It seemed worth while, then, to determine whether any real discrepancy between them existed or not.

Loring, following Mauthner[2] in the use of a formula given by Helmholtz,[3] shows in his table the amount of displacement in certain degrees of ametropia. Knapp, using another formula given by Helmholtz,[4] shows the amount of displacement in degrees of ametropia which are corrected by a lens of a certain number of inches focal distance (positive or negative), placed at the anterior principal focus of the eye. The ante-

[1] *Loc. cit.*, p. 397. [2] Lehrbuch der Ophthalmoscopie, pp. 67, 226, 227.
[3] Handbuch der Physiologischen Optik, p. 54. [4] *Loc. cit.*, p. 56.

rior principal focus of the eye being 20.29 mm., almost exactly $\frac{3}{4}''$, in front of the second nodal point, we must therefore subtract $\frac{3}{4}$ from the number of the glasses given by Knapp to obtain the degrees of hypermetropia, and add $\frac{3}{4}$ to obtain the degrees of myopia referred to in his table. This change having been made, it is seen, on comparing the two tables, that the degrees of hypermetropia and myopia for which the calculations were made are, except in one instance, different, and the amount of the displacement given varies not more than this difference might perhaps account for, if both methods of calculation be correct. In the one instance in which the displacement for the same degree of ametropia is given in both tables; viz., M.$\frac{1}{2}$, the tables do not agree. This is, however, not the fault of the formulæ. Loring gives the displacement as 8.6 mm., and Knapp as 8.26 mm. There is here an error in Knapp's table; instead of 8.26 mm., it should be 8.72 mm. This still gives a slight difference, but it is due to the fact that Mauthner, and after him Loring, estimated degrees of M. from the first nodal point, and degrees of H. from the second nodal point; while Knapp estimated degrees both of M. and H. from the second nodal point. If the calculation be made with the formula used by Loring, estimating the M. from the second nodal point, there is no disagreement.[1]

Pursuing the investigation still further, an examination of the formulæ used by Knapp and Loring shows that they are convertible, and must, therefore, with the same premises, give the same results.

Knapp, by means of the formula—

$$a_{,} t_{,} = \frac{(d - f_{,})\, \phi_{,}}{d - \phi_{,} - f_{,}}, \text{ calculates } a_{,}\, t_{,},$$

the distance of the retina in a given eye from its second principal point.

Loring, from the formula—

$$l_2 = \frac{\phi_{,}\, \phi_{,}}{l_{,}}, \text{ calculates } l_2,$$

the distance of the retina in a given eye from its second principal focus.

[1] There is also an error in Loring's table. The displacement for M.$\frac{1}{11}$ should be 1.06 mm., instead of 1.62 mm. as given.

Both take the schematic eye of Listing as a basis, and assume that the refractive system always remains the same.

l_2, the distance calculated by Loring, is equal to $a_{\prime\prime} t_{\prime\prime}$, the distance calculated by Knapp, less $\phi_{\prime\prime}$, the second focal distance of the eye. Subtracting $\phi_{\prime\prime}$ from both terms of the formula used by Knapp, we have—

$$a_{\prime\prime} t_{\prime\prime} - \phi_{\prime\prime} = \frac{(d - f_{\prime\prime})\,\phi'}{d - \phi_{\prime} - f_{\prime\prime}} - \phi_{\prime\prime} = \frac{\phi_{\prime}\,\phi_{\prime\prime}}{d - \phi_{\prime} - f_{\prime\prime}} = l_2$$

The value of l_2 used by Loring is $\frac{\phi_{\prime}\,\phi_{\prime\prime}}{l_{\prime}}$. $l_{\prime}$ denotes the distance at which the image of the retina of an eye formed by its refractive system stands from its first principal focus. On referring to the definition given by Helmholtz of the terms used by him,[1] we find that d denotes the distance at which the corrective lens[2] (the lens which renders rays coming from the retina parallel) stands from the first principal point of the eye. The image of the retina formed by the refractive system of the eye is the posterior focal distance of the corrective lens ($f_{\prime\prime}$) behind the lens; and the first principal focus of the eye is its anterior focal distance ($\phi_{\prime}$) in front of its first principal point.

Therefore $l_{\prime} = d - \phi_{\prime} - f_{\prime\prime}$, and $a_{\prime\prime} t_{\prime\prime} - \phi_{\prime\prime} = \frac{\phi_{\prime}\,\phi_{\prime\prime}}{d - \phi - f_{\prime\prime}} = \frac{\phi_{\prime}\,\phi_{\prime\prime}}{l_{\prime}} = l_2$.

[1] *Loc. cit.*, p. 56.

[2] We consider, as Mauthner and Knapp have done, that the second principal point of the lens coincides with its centre.

VARIETY OF FORMS OF SMALL PENCILS OF ASTIGMATIC RAYS. By Dr. G. Hay, Boston.

In the accompanying diagram, the lines O X, O Y, and O Z, represent three rectangular coördinate axes. The lines l and l' represent two straight lines intersecting O Z at different distances from O.



Fig. 1.

It is possible to conceive a *small pencil* of rays (straight lines), such that O Z being one in the body of the pencil, or the axis-ray, each ray intersects the coördinate plane Y X, and the two (focal) lines l and l', not only when these are perpendicular to each other and to O Z, but also for other positions of the two lines (not including, however, the case of the two being in one plane; they being supposed to intersect O Z at different points).

We might suppose l and l' each perpendicular to O Z, but not so to each other; or either or both of them might not be perpendicular to O Z. Also, instead of one of them, a curved line might be substituted.

The above appears from the following: Conceive a plane to pass through the straight line l and O Z, so that both these lie in the plane. Rotate this plane *a very little* around the

line l as an axis; it will then intersect the coördinate plane Y X in a line near to O. This line of intersection, a certain point of l', and the line l will then all lie in one plane. Accordingly, a straight line could in general pass from any point of the line of intersection just referred to, through a certain point of l' and some point of l.

By rotating the plane into other positions *quite near* to the first, we see that in general, from any point in the coördinate plane Y X and near to O, a straight line could pass which would intersect both l' and l, and also be quite near to O Z.

It is interesting to compare this conceivable variety of astigmatic pencils with the analysis given by Knapp. (*See* A. f. O., 1862.)

This method contemplates the points in which each ray intersects different planes perpendicular to the axis of the pencil. The axis of the pencil is taken as the coördinate axis O Z. The pencil is supposed infinitely small. The direction of each ray is supposed subject to a certain law, expressed by the following equations:

$$\left.\begin{aligned} x_1 &= Ax_0 + By_0 \\ y_1 &= Cx_0 + Dy_0 \end{aligned}\right\} [1]$$

In these equations x_0 and y_0 are the coördinates of the point of intersection of a ray with the coördinate plane X Y; x_1 and y_1 are the coördinates of the point in which the same ray intersects a plane perpendicular to the axis and at the distance z_1 (=1) from the origin. A, B, C, and D, are constants for any particular case. As the pencil is supposed infinitely small, any higher powers of x_0 and y_0, that might occur in the development of x_1 and y_1, are neglected.

As these equations [1] suppose that a ray which passes through the point (x_0, y_0, 0) also passes through the point (x_1, y_1, 1), and as for any particular x_0 and y_0 the x_1 and y_1 might each, according to the equations, be different for different values of the A, B, C, and D, we should expect that a great variety of pencils might be represented by these equations, and we have seen above that such variety is geometrically conceivable.

Assuming the equations [1], and introducing certain limitations by putting B = 0, and C = 0, it follows that each ray of the infinitely small pencil intersects two straight lines (l and l' of the figure) perpendicular to each other and to the axis; one of them in the coördinate plane Y Z, and the other in the coördinate plane X Z. This form of pencil may, for convenience, be called the typical form.

The conditions B = 0, and C = 0, limit the form of the pencil somewhat, making it like a pencil of normals to a continuous curved surface; since, with these conditions, all the rays of the infinitely small pencil, which intersect the coördinate axis X, would lie in the coördinate plane X Z, and all the rays which intersect the coördinate axis Y would lie in the coördinate plane Y Z. (For this and the preceding paragraph, *see* Knapp's Archives, vol. ii., No. 1, pp. 82–85.)

The form called above *the typical one* is also, at least approximately, the form of an infinitely small *pencil of normals* to a continuous curved surface; and this latter (pencil of normals) is the form which an infinitely small pencil of originally homocentric light has after refraction at one or more continuous curved surfaces. (*See* Helmholtz, "Physiolog. Optik.," pp. 243–247.)

The general equations [1] would be applicable to other forms of pencils of *straight lines* besides the typical one.

The conclusions arrived at by means of the formulæ given by Knapp, that there may be two focal lines *each perpendicular to the axis*, are subject to certain conditions:

1. The algebraic expressions for the distances of these focal lines from the origin must have *real* values, and not be imaginary.

2. The equations [1] must exactly represent the pencil.

These required conditions do not always exist; for, we have seen above, that cases are conceivable in which one or both of the focal lines are not perpendicular to the axis.

THE RETINA AN ASYMMETRICAL SURFACE. By Dr. Russell Murdoch, Baltimore, Md.

Any one, carefully reviewing the accepted theory of the corneal seat and asymmetrical cause of astigmatism, must feel how very inadequate such an explanation is to account for all its varieties, as well as for all the varied phenomena of those varieties. The incongruity of perfectly non-astigmatic vision with the normal asymmetrical cornea is in like manner unsatisfactory. A factor is evidently missing in both these propositions; we believe the same one in both.

The large majority of asymmetrical corneas found in the examination of the anterior surface of that structure with the ophthalmometer, and by different observers, justifies the statements that, as a rule, its form is that of "the top section of an ellipsoid with three unequal axes," and that it has its "two meridia, the vertical and horizontal; the more convex of which is the vertical." From similar numerical evidence we infer that astigmatism, with all its varieties, is the result of a variation in the curvature of those two meridia; thus, from this one phenomenon two distinct results ensue of a totally opposite character, viz., emmetropia, the most perfect vision, and astigmatism, a form of ametropia. We propose to show that, without a modification of the accepted asymmetrical shape of the cornea, these two propositions can be harmonized, by showing that a surface which is capable of compensating for the corneal asymmetry will not interfere with the known phenomenon of astigmatism, but will even supply the missing factor in the tables where the asymmetry and astigmatism are compared.

The factor we are in search of is not the lens, for the following reasons: first, the asymmetry is not described as existing in the lens in the normal eye; and even when it is present in the abnormal eye, and has been measured, it is of the irregular sort; and, second, Javal has proved that the lenticular surface is incapable of answering the requirements of a case of regular astigmatism, whence, we argue *a fortiori*, still less so as a corrective surface in emmetropia. The argument need not be repeated here; it is familiar to all. The other dioptric surfaces are all those of rotation; and an asymmetry capable of correcting that of the cornea would not have escaped notice, because, from their nature, having but comparatively slight indices of refraction, these surfaces would then have to be pronouncedly asymmetrical.

On examining the retina closely, it will be found that its internal surface is an asymmetrical one, similar and opposed to that of the cornea: a concavity where the other is convex. And here attention must be called to the stationary nature of this surface, which, therefore, is not open to the objection urged in reference to the lens; and also to its equal importance, as a factor, with that of the cornea, because situated at the opposite pole. Looking at the structure of the retina, we discover the optic nerve entering eccentrically and sending its fibres through the retina in a horizontal direction, and by two bundles, which, on separating, leave a horizontal sulcus. It is plain that these optic nerve-fibres must cause an encroachment on the vertical meridian of the ball.

It is hardly required of us to prove that the inner surface is the one which is rendered asymmetrical by the optic nerve-fibres, since it is universally conceded that the external layer is spherical. The conclusion that this surface is asymmetrical gathers weight, when we consider the function and notice the unequal distribution and irregular lengths of the nerve-fibres of Müller: they connect the inner and outer surfaces of the retina, are absent when the nerve-fibres are absent, or where the surfaces, as it were, come together, and are in greatest number and length where the nerve-fibres are thickest. The link supplied by Müller's fibres is all that is wanting to convey a non-astigmatic image (formed on the

compensating inner surface of the retina, and formed there by virtue of its corresponding asymmetry to that of the cornea) to the spherical layer of rods and cones. It would be easy, but is not necessary in this presence, to show that the retina is the first to depart from the sphere, and that the cornea is a mechanical contrivance, a sphere and cylinder combined, to correct the effects of its aberration: its greater relative functional importance is a sufficient argument. What we have undertaken to show is, that the surface which corrects the asymmetry of the cornea and produces emmetropic vision will aid in explaining many phenomena of astigmatism. The first is that, where the asymmetry at the anterior pole has been measured and compared with the total astigmatism, they did not agree; a factor, and by no means a uniform one, was found to be wanting; such a one as would be supplied by a varying asymmetrical surface corresponding to the cornea itself. Again, it is a singular fact that, although we now know that the ametropias are produced by a change of position in the posterior pole of the eye, and although we know there is a peculiar and intimate connection between different varieties of the ametropias and astigmatism, yet nothing has been as yet advanced to explain the connection. To be more explicit, the smaller amounts of ametropia are, as a rule, complicated with astigmatism; while, with the greater, such is not the rule. An explanation for these phenomena, we think, is to be found short of the poles: we believe the same surface produces both; not always, nor necessarily to the entire amount in any given case; but the above connection, which has been dignified as the rule, can only meet with an adequate explanation when the two, astigmatism and ametropia, have their origin in the same surface and are produced by the same cause.

There are six varieties of astigmatism, four of which can be explained without supposing a change of curve; merely supposing a change in position of the posterior pole. Now, by this hypothesis, emmetropia with non-astigmatic vision exists when the two asymmetrical surfaces are at focal distances. But suppose the retina is separated, so that the vertical meridian occupies the place of the horizontal one, this

latter is entirely out of focus, and we have produced the first Am. A little further extension of the ball, and we have M + Am. The other two may be produced in like manner by an approach of the retina to the cornea; first Ah and then H + Ah. It is worthy of remark that this hypothesis presumes the most distinct meridian to be the rule in all these cases, and departure from rule to be due to an exceptional cause. Our hypothesis does not ignore variation in the meridia, but makes it of secondary importance, and presumes that the variation of these is less in any given case, because two meridia are added together.

There are two other classes with their varieties—the mixed astigmatisms, M + Ah, and H + Am. With, however, two surfaces to account for these mixed astigmatisms, a certain amount of corneal curvature without deformity is presumable; but not so if it all is produced at the anterior pole. A natural division of the astigmatisms is made by some: those having a general cause and connected with a facial distortion, and those confined to the eye. Possibly it will be found that the former are more intimately connected with the change of the retinal plane, as occurs in the ametropias, while the others have the variation of curves in one or both poles of the eye, as their most important factor.

Without enlarging—and these remarks are capable of greater extension—we turn to some phenomena that admit of no other explanation than a purely retinal seat. Sometimes in testing astigmatism two equally defined and very distinct lines are seen (we do not now refer to cases where there is but one meridian); these the corneal surface alone cannot possibly produce, and, moreover, the lens is excluded because they continue during accommodation. We believe that, of these two lines, the one in rule, i. e., either the vertical or horizontal one, as the case may be, is due to the cornea, while the other, the slanting one, is produced by the retina. This phenomenon of orientation of a meridian occurs generally in slight ametropias, and, consequently, in looking for a cause, that fact must be held in view. In slight ametropias, whether H or M, the plane of the retina is on a level with the optic papilla, but with the more extensive ones the plane of the retina at

the macula is far removed. This answers as nothing else does; and we offer therefore the following explanation of the process occurring in the departures of the eyeball from the normal: The retina revolves in its plane around the eccentric optic nerve as a pivot, and consequently a meridian in focus does not remain either vertical or horizontal, but tilts.

An evanescent astigmatism, noticed by Dr. E. G. Loring, must have its seat solely at the back of the eye, because it occurs during diseases of the retina and choroid, and disappears when the disease passes away.

It is well known that all explanations which have designated the cornea as the seat of the astigmatism connected with strabismus, which passes away with the removal of the defect, have signally failed, because any explanation must consider that they are in rule. We do not claim originality in considering them as produced at the posterior pole, but we offer an explanation which we think has not before appeared, and has the advantage of an agreement with rule. For example, in internal strabismus, the internal muscle, pulling the cornea inward, stretches the external muscle which hugs the whole of the outside of the eye; the optic nerve, rigid and unyielding on the other side, forms at the posterior pole a vertical sulcus; and a vertical sulcus behind corresponds with a short vertical meridian in front, i. e., a meridian in rule.

It may be urged that, in any case, if the ophthalmometer shows that a spherical cornea is connected with non-astigmatic vision, our hypothesis is overturned. We reply, not so, unless enough spherical corneas are found to prove it the rule; as an exceptional cornea may very naturally be connected with an abnormal retina.

NOTE A.—An asymmetry of the cornea amounting to $\frac{1}{18}$ cyl. lens would only require an advance of .158 mm. of the vertical meridian of retina to produce E.

NOTE B.—A species of orientation in which the optic nerve revolves around the macula, instead of the macula around the nerve, can be seen by comparing the eyes of the sheep, cat, and man. This revolution is, moreover, connected in the two first-named animals with the well-known change of direction of the stenopacic pupils, while in man, where the optic papilla holds an intermediate position, the pupil is round; but the cornea, as I think I have shown, accomplishes by its asymmetrical nature the same connective agency, but with a better cosmetic effect.

LETTER FROM DR. G. HAY, OF BOSTON.

In conformity with the vote of the Ophthalmological Society, I beg leave to send to you the following, which I also send to Dr. Murdoch.

What I objected to was the view that an astigmatism, caused by an asymmetrical cornea, could be corrected by an asymmetrical retina.

According to my notion of the matter, if an astigmatism existed in consequence of an asymmetry of the cornea, then a pencil of rays proceeding from a *single point* of the object, say the point looked at, would, when arrived in the vitreous, be an astigmatic pencil.

From such an astigmatic pencil, which has no point-focus, the retina could not receive a point-impression, but only an impression extending over a certain surface, or a linear-shaped impression; and this, although the pencil proceeded from a single point of the object.

This being the case, even if the retina became asymmetrical, it could not reduce to a point-impression the surface-impression or line-impression made by the astigmatic pencil, that is, it could not correct the astigmatism. The impression on the retina would not be materially altered by the proposed change of shape of the retina.

This is the essence of what I intended to say at the meeting.

Very respectfully, G. Hay.

Dr. Noyes, Secretary American Ophthalmological Society.

DR. MURDOCH TO DR. HAY.

Dear Doctor: In reply to your much-esteemed favor of the 27th ult., I beg to say that we do not differ in that "a pencil of rays proceeding from a *single point* of the object, say the point looked at, would, when arrived in the vitreous, be an astigmatic pencil." Yet I cannot see that my position is altered by limiting the extent of surface, as you propose, for we are dealing with a pencil in either case, and, as long as we are so obliged to do, we obtain extension in two directions, and consequently have neither point nor line.

The most important position is your second, and there I entirely dissent from you, because a linear-shaped impression can only be formed by a purely cylindrical surface, and the cornea is a combination of sphere and cylinder, the former in much greater proportion (an asymmetrical cornea, you will grant me, differs from our sphero-cylindrical combinations only in having them both on one surface). Now, as, in the perfect camera, we oppose a convex sphere with a concave, and thereby correct spherical aberration, so I conceive that an analogous correction is effected in the eye by the opposition of a concave cylindrical element to the convex.

I am, etc., Russell Murdoch.

DR. HAY TO DR. MURDOCH.

Dear Doctor: I beg leave to acknowledge the favor of yours of the 3d ult. It is rather difficult to compare views by writing, but I should like to add a few words in explanation of my first note.

In the first place: I took up the case of a single pencil from a single point, thinking in that way to simplify the matter, because what we have to deal with is, I suppose, a collection of such pencils; one from each point of the object. And my idea was, that, if a proposed remedy would not correct a single astigmatic pencil, the same remedy would not correct a collection of such pencils.

Again: You write, a "linear-shaped impression can only be formed by a purely cylindrical surface, and the cornea is a combination of sphere and cylinder," etc. If we combine a plano-convex lens about $\frac{1}{8}$ $\frac{8}{4}$, with a simple concave cylindrical $-\frac{1}{8}$, putting the two plane surfaces together, and placing the combination at about eight feet from an Argand gas-burner, burning rather low, we can get a linear-shaped illumination on a card placed at right angles to the course of the rays of light, the lenses being also similarly placed.

At one distance of the (white) card from the lenses we get a linear illumination in one direction; and at another distance of the card, a linear illumination at right angles to the first.

The linear character of the illumination may be made more marked, as follows: Let the light burn higher; put a screen before it, with a small hole, about $1\frac{1}{2}$ or 2 lines in diameter, placed opposite the brightest part of the flame; bring up the lenses to about four feet from the light.

I think the experiment is quite *à propos* to the question at issue. I shall be glad to know how it appears to you. Yours, etc. G. HAY.

DR. MURDOCH TO DR. HAY.

DEAR DOCTOR: The combination you suggest is equivalent to two cylindrical lenses of unequal foci ($\frac{1}{8}$ $\frac{8}{4}$ C ⌊ + $\frac{1}{4}$ $\frac{1}{4}$ C nearly) at right angles to each other.

The foci appear straight, because they fall on a plane surface, and are seen *en face;* but are arched, both in the direction of their long and short diameters: thus ◡, ◡.

I do not think that the experiment is appropriate, nor can I in its place suggest a spectral one, on account of the impossibility of grinding an asymmetrical surface which can oppose such a combination as that of the normal cornea. I can only suggest a subjective experiment, which to my mind is equally convincing: please make yourself slightly As., say Am. by $\frac{1}{24}$ cyl., and observe either Green's test-plates, or a candle-flame, placed at 20′, and ask yourself what surface will *passively* correct the As. Will it not be a similar one in kind to that which would *actively* correct the astigmatic rays before they enter the vitreous? To me the impression is that of an undulating surface, requiring an undulating or *cylindrical* surface to produce a uniformly distinct image, etc.

Yours, etc. RUSSELL MURDOCH.

AN ADDITIONAL METHOD FOR THE DETERMINATION OF ASTIGMATISM. By Dr. George Strawbridge, of Philadelphia.

I think it will be readily admitted that a simple, quick method for the determination of astigmatism is something very much to be wished for, but as yet not reached; and, with this end in view, I submit the following method, based on an experiment described in "Helmholtz's Optics," page 107, to wit:

"If the light from a gas-lamp, or from the sky, be allowed to pass through a small round opening in a screen, such a light will appear, to an eye not exactly accommodated for it, as a star, with light radiation proceeding from it in various directions; now, if a diaphragm is pushed slowly from the side so as to pass gradually in front of the eye, it will be observed that this 'light figure' begins to be *shaded*, and on the *same* side *from which the diaphragm was moved*, if the object is *farther* removed than the *point* for which the eye is *accommodated*, but from the *opposite* side, if the object is *nearer* than the point for which the eye is accommodated."

The reason of this will be readily seen by examination of the figure on the following page.

Rays of light proceeding from point a, after passing through lens b, will unite at point C, and on the retina $E\,E'$ a sharp image of the object will be thrown. But, suppose the eye to be hypermetropic, and the retina to be at $H\,H'$, then, instead of a sharp image, circles of dispersion will be formed of a diameter represented by $p\,q$. If in this circle we individualize the two points, $p\,q$, which are met by the light proceeding from a, as a result, the individual, under these cir-

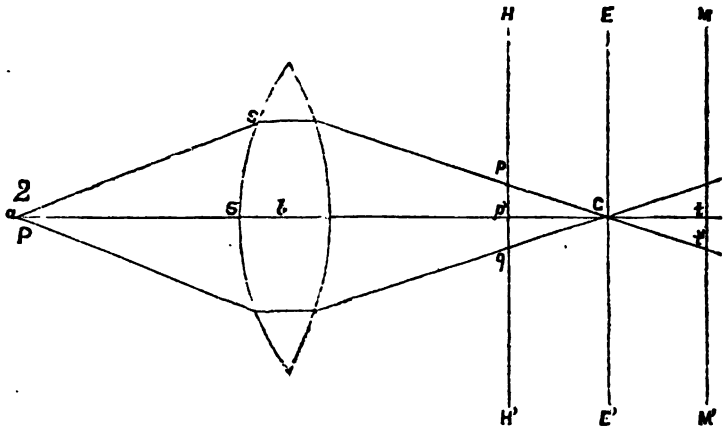

FIG. 1.

a, Light-point in space; *b*, Refractive media of eyeball; *C*, Focus of lens, *b*; *E E'*, Position of retina in emmetropic eye; *H H'*, Position of retina in hypermetropic eye; *M M'*, Position of retina in myopic eye.

cumstances, will consider that the upper point *p* in the retina represents the image of an object situated in the field of vision below the real light-point *a* (as *P* in diagram), and the lower point *q*, of an object *above* the real light-point (as *Q* in diagram); following the rule that images on the retina are inverted, and a lower-situated object corresponds to a higher-situated image on the retina.

Now, it will be readily understood that, by cutting off the rays of light as in the section *S S'* by a diaphragm, if the eye is *hypermetropic*, the semicircle of light-dispersion, *p p'*, on the retina *H H'*, will be intercepted; while, if the eye is *myopic*, the semicircle of light-dispersion, *t t'* on retina *M M'*, will be intercepted, and to the observer the effect will be, if hypermetropia exist, that the lower half of the light-circle at *a* will first vanish; while, if myopia exist, the upper half of the light-circle will first disappear as a consequence of the position of the images on the retina.

With these preliminary remarks, I proceed to describe the method of examination:

In the centre of a Bristol-board, a round aperture of thirteen millimetres diameter is cut, and at a distance from the aperture of six centimetres radiate bars, cut in the Bristol-board, having a length of nine centimetres, and width of five

millimetres, and forming an angle with each other of ten degrees. Over this figure, white gauze paper is passed, and a lamp, placed behind, illuminates it in its entire extent.

The patient is placed at a distance of twenty feet from the figure, and requested to observe the round central opening, and to notice in what direction it is most elongated. This is readily determined by observing to which of the bars in the figure the light-prolongation most closely corresponds in its direction, and the result will be controlled, as to its accuracy, by also finding which of the bars are most distinctly seen. For example, in a case of myopic astigmatism in the vertical meridian, it would be found that the light-elongation would be upward and downward, and at the same time the vertical bar would be most distinctly seen.

By this procedure the *direction* of the meridian is discovered. The next step is to determine the *refraction* of the *meridian.*

To this end a diaphragm is advanced in the direction of the greatest elongation of the round light (suppose it to be vertical, and that the diaphragm moves from above downward), and the patient is requested to notice whether the upper half of the round light first disappears or the lower half, as the diaphragm moves downward; if the upper half is first gone, the meridian is shown to be so curved as to cause a *myopia* to *exist.*

While, if the lower half of the round light is the first to disappear, we conclude that a hypermetropia exists.

If the entire round light is found to disappear at once, it may be concluded that very little astigmatism exists.

The direction of the meridians being now known, as well as their refraction, whether normal or so curved as to cause a myopia or hypermetropia, the next step would be to determine exactly the *amount* of *abnormality.*

To this end we proceed with spherical glasses, determining the exact one necessary to see distinctly the proper bar, as in the method laid down by Snellen.

Advantages of this method:

1. Simplicity. The usual methods are, as a rule, so complicated that the patient often becomes confused in the ex-

amination, and an error can easily result; but to this new procedure no such objection can be made.

2. Accuracy, which results from the extreme delicacy of the test formed by illuminated bar.

3. The great saving of time, arising from the fact that the mode of examination can be conducted so much more quickly than by the ordinary methods.

4. This method allows of examination being made entirely independent of daylight, and so obviating any inconvenience arising from defective illumination found in cloudy weather, etc.

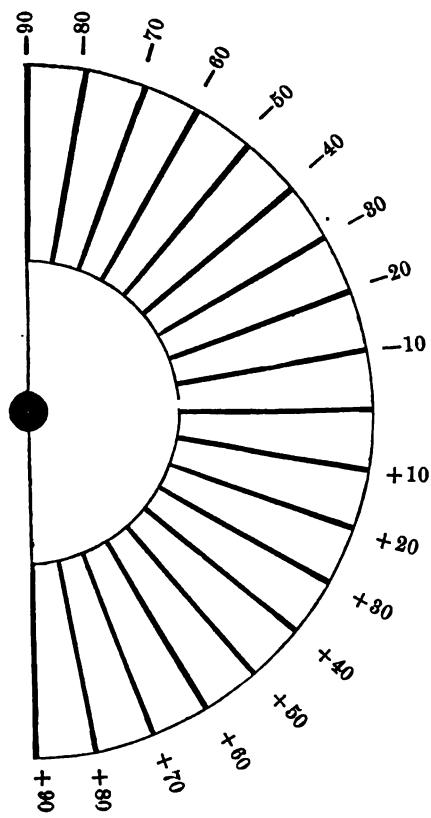

Fig 1

The above represents the figure used in this method of examination. The black circle and broad lines represent the central round aperture and bars, which are illuminated by a light placed behind. To Dr. John Green, of St. Louis, I am indebted for the idea of arranging the bars, as radii of a circle.

ON ASTIGMATISM AS AN ACTIVE CAUSE OF MYOPIA. By JOHN GREEN, M. D., St. Louis, Mo.

IN a paper published in the *American Journal of the Medical Sciences*, for January, 1867, I called attention to the fact that persons known to be myopes prove, upon careful examination, to be in a large proportion of cases also the subjects of astigmatism, a fact which suggested to me the possibility that, in many of these cases, the astigmatism stood to the myopia in the relation of cause to effect. I purpose now to study this relation in the light of recently-published statistics of astigmatism, taking for comparison my own series of cases, reported to the American Ophthalmological Society in June, 1867, and July, 1868,[1] and the much larger series published by Snellen, in connection with the Tenth Annual Report of the Netherlands Ophthalmic Hospital, in 1869.[2]

Snellen's tables comprise all the cases of astigmatism which occurred in the Utrecht clinic and consultation rooms during the years 1864–'68; 278 patients are enrolled, presenting 498 astigmatic eyes, 18 myopic, 8 hypermetropic, 9 emmetropic, and 23 blind or very imperfect eyes. My own cases, as published, include 48 patients with 84 astigmatic eyes, 4 myopic, 4 hypermetropic, 2 emmetropic, and two imperfect or blind eyes, making, with Snellen's cases, a total of 316 patients with 582 astigmatic eyes.

Of these 582 astigmatic eyes, in 318, or 54.6 per cent., the refractive anomaly was by excess (myopic astigmatism), and

[1] Transactions of the American Ophthalmological Society, Fourth and Fifth Annual Meetings, Niagara, June, 1867, and Newport, July, 1868.

[2] Het tienjarig bestaan van het Nederlandsch gasthuis voor ooglijders. Met wetenschappelijke bijbladen. Utrecht, 1869. Also, Archiv. für Ophthalmologie, Band XV., Abtg. 2.

in 264, or 45.4 per cent. by deficiency (hypermetropic astigmatism), the percentage being almost exactly the same in the two series of observations. Both Snellen's and my own measurements were made, for the most part, without using atropia, and must be taken as showing the manifest rather than the total refractive defect; in many instances, therefore, we may assume that the accommodation was but partially relaxed, and that some cases really of Ah. or of Ahm. have been recorded as Am., or possibly even as M+Am. But, applying an approximate correction for this defect in the observations, we may still conclude, with a good degree of probability, that the cases of Am. and M+Am. are not less numerous than those of Ah. and H+Ah.

When we analyze the statistics of compound astigmatism we find the proportion of myopic to hypermetropic eyes much greater than in the aggregate of all the forms of astigmatism, while the source of error just noticed is almost if not quite eliminated. Thus we have from Snellen's tables, of—

M.+Am.	128 cases, or	61 per cent.
H.+Ah.	81 " "	39 " "
	209	100

From my own list we have, of—

M.+Am.	39 cases, or	53 per cent.
H.+Ah.	33 " "	47 " "
	72	100

Combining the two tables we have, of—

M.+Am.	167 cases, or	59.4 per cent.
H.+Ah.	114 " "	40.6 " "
	281	100

These data would seem to afford a fair basis for the assumption that there is more than an accidental connection between myopia and astigmatism. That such connection should exist is, moreover, not only quite probable, but the opposite condition would seem to be, on the whole, improbable.

Admitting, with Donders, that hypermetropia is the expression of an inherited conformation of the eye, while myopia is ordinarily the result of a pathological distention of the globe, we are irresistibly led to the conclusion that most of the cases of M.+Am. may have been originally cases of sim-

ple or possibly of mixed astigmatism. So also some of the cases of Am. and Amh. may be only instances of myopia superinduced upon Ahm. or Ah.[1]

To deny this is to assume that astigmatism when conjoined with myopia is to be considered as acquired, while we regard simple astigmatism and astigmatism conjoined with hypermetropia as congenital.

It only remains to point out how astigmatism can act as a cause of myopia, and this seems sufficiently obvious. The effect of reading and study of books, in originating as well as in aggravating the grade of myopia, has been clearly pointed out by Cohn, of Breslau, who has called attention to two very important elements of mischief in schools, viz., insufficient or badly-arranged illumination, and bad construction of desks, compelling the scholars to bend their heads over their books.

Exactly analogous to the effect of insufficient light, in compelling the child to hold his book nearer than would otherwise be necessary, is the operation of any other cause which tends to impair the distinctness of vision. Such a cause, and a most efficient one, we have in astigmatism, and we need but reflect upon the amount and kind of book-work which is demanded of our school-children, to find in even moderate grades of astigmatism an almost irresistible incentive to read under high degrees of convergence and with strong exercise of the accommodation. In astigmatism the injurious effect of insufficient illumination, too, must be far greater than in emmetropia, inasmuch as the normal compensation in the enlargement of the pupils is rendered unavailing through the consequent diminution in the distinctness of the retinal images.

Researches undertaken upon large numbers of myopes, with a view to establishing the degree of frequency with which astigmatism is present as a complication, are, so far as I know, still wanting.

[1] The recent careful investigations of F. Erismann, upon 4,358 school-children of St. Petersburg, seem to prove, beyond a doubt, that large numbers of eyes originally hypermetropic pass through the stage of emmetropia, finally to become myopic—and this as a direct result of long-continued straining of the accommodation and convergence in study. (Archiv. für Ophthalmologie, xvii., i.)

REMARKS ON CATARACT. By Edward G Loring, M. D., New York.

Mr. President: As you are well aware, it has long been recognized that astigmatism often occurs as a disturbing element in the vision of patients who have been operated upon for cataract. Thus, Dr. Knapp, in Graefe's *Archives* for 1867, observes, that "we should not neglect to test eyes, which have been operated on for cataract, with cylindric glasses, to see if vision is not thereby improved. This is found to be the case in a marked degree, where the result has been a good one, in about one-fourth of the cases. Thus, I have found, where V. = $\frac{1}{4}$, corrected it will be $\frac{1}{2}$, and V. $\frac{1}{3}$ will become $\frac{2}{3}$, and so on."

But notwithstanding this knowledge of its existence, very little has been done by the majority of operators in determining the degree of the error in refraction when making out their statistics of vision, and still less has the attempt been made to remedy the defect by prescribing suitable glasses.

This latter is no doubt due to the fact that the necessary sphero-cylindric glass is so heavy and of so awkward a shape as only to be worn with great discomfort to the patient. Thus, if we wished to give a spherical glass, for example + $\frac{1}{4}$ combined with a cylindric glass, the spherical surface, inasmuch as it would have to be put all on one side, would have to be ground on a radius of two inches. This degree of curvature would, in order to fill the eye of the spectacle-frame, require the glass to be very thick in the centre, the apex of which would consequently project a good deal from the plane of the rim of the spectacle, while the slight curvature of the cylindric surface would hardly project at all. Such a glass as this is necessarily very heavy, clumsy, and uncomfortable.

With the hope of remedying these objections, so as to allow us to give astigmatic glasses to cataract-patients, I have contrived the glass which I now present to the Society, and which is made in the following manner:

A simple cylindric glass of the required strength is first set in the spectacle-frame in the usual way, the axis of the glass of course running in the required direction. A thin plano-convex glass is then ground, and, taking advantage of the fact that lenses can be cemented together by Canada balsam, this is firmly fixed by its plane surface to the back, or plane surface of the cylindric glass.

As the diameter of the plano-convex is made only equal to the vertical diameter of the spectacle-frame, and not to the longitudinal one, it follows that a large quantity of glass is thus dispensed with, and the weight of the glass is thereby much lessened, the two combined lenses being in fact, when nicely made, only one-fourth of the common spherical cataract-glass as found in the shops.

In the figure, *A* gives a longitudinal section of the glass, the dotted line marking the line of union between the two

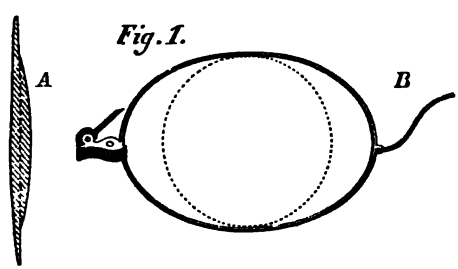

lenses, while *B* shows the front view of the glass as it appears in the frame, the dotted line here showing the circumference of the plano-convex glass. As you will observe, the edge of the convex lens is so delicately ground and so perfectly fitted to the cylindric glass that the point of union is barely perceptible when the glass is worn, and the peculiarity of its construction would escape the notice of any but a very observant eye.

The pair which I now offer as a sample has a spherical surface of $+\frac{1}{2}$ (really equal to a biconvex $+\frac{1}{4}$), and a cylin-

dric surface $+\frac{1}{12}$ C, the patient being astigmatic to that degree in the vertical meridian. With the best correction with spherical glasses, vision equalled $\frac{1}{4}$; with this glass it rose to $\frac{1}{2}$.

The chief objection which would be raised against glasses made in this manner would, in all probability, be on account of their liability to come apart. Whether this is a valid objection remains to be proved. I would say that this pair has been in constant use for four months, and in that time they have been dropped twice; once in a crowd, from which they were only rescued after the frames had been considerably bent. They certainly show no signs of separation between the two lenses, and we know that the lenses of telescopes and opera-glasses are subjected, oftentimes for years, to the extremes of temperature and hard usage, without showing such a tendency, and, even if the glasses should occasionally separate, it is certainly a simple matter to recement them.

This slight inconvenience would be more than compensated, it seems to me, by the increased amount of vision gained, especially when, as in the present case, it is doubled.

In this connection I would remark that it seems to me that a want of uniformity now exists among operators in regard to testing the vision of cataract-patients, which has a tendency, to say the least, to create confusion not only as to the results of different operators which is of comparatively small importance, but also as to the merits of the method of operating itself, which is of vast importance.

It is almost universally considered now, after the so-called peripheric linear has been in vogue for the past eight years, and after it has been consequently thoroughly tried, that it is far superior to the old flap-operation, and this opinion purports to be founded—not as many medical opinions are—on unsupported convictions of its great originator, and a few of his most skilful disciples, but on carefully-prepared statistics, which, as they are based on mathematical principles, are of almost mathematical exactness. It is alleged that, as the basis upon which the statistics for both operations were compiled was the same, namely, Snellen's method, it follows that the comparison must be a just one, and, as the peripheric linear yielded more favorable results, this was the better operation.

From this opinion, prevalent as it is, we demur, and believe that, although the method of testing was the same, yet the standard used was different, and that, consequently, the conclusions drawn are not only unreliable but even erroneous, and that, so far as statistics go, it is at least still a question whether the old flap, and not the new peripheric linear, does not give the best results.

To show that this is the case, reference must be made to the statistics themselves.

In 1863 Graefe published the results of 1,500 cases of flap-extraction.[1] Out of these he got 65 per cent. of immediate good results, with 15 per cent. additional after a secondary operation, making 80 per cent. as a grand total of perfect success. In these cases, "vision of at least $\frac{1}{4}$" is taken as the standard necessary for a good result. In patients over seventy-five years, however, $V=\frac{1}{6}$ is allowed. There was a total loss of from 5 to 8 per cent.

In a later paper, however,[2] Graefe gives another series of cases, in which he gets 84 per cent. of perfect results, 11 per cent. of half successes, and a total loss of 5 per cent., and he then states that, in his private practice, the results were even better than this, namely, 91 per cent. of perfect results, 6 per cent. of half successes, and only 3 per cent. of absolute loss. Ninety-one per cent. of patients, with vision $\frac{1}{4}$ and over, and only 3 per cent. of total loss, is a result which we venture to say has never been equalled by any other method.

If we now turn to the peripheric linear, we find at the outset that "Graefe, as Dr. Norris says,[3] has not given us so extended and full an analytical report of his cases as would be desirable," but he did publish 300 cases (*Archiv.*, xii., part i., p. 151), in which he got 90 per cent. of perfect immediate good results. But here, instead of taking vision $\frac{1}{4}$ as a standard, he took $\frac{1}{6}$, and we have no means of knowing how many cases were included between $V = \frac{1}{4}$ and $V\ \frac{1}{6}$. But, if, for the sake of calculation, we take the differ-

[1] Zehender, Klin. Monatsblät., p. 146, 1863.
[2] Archiv. für Ophthal., vol. xi., part iii., p. 7, 1865.
[3] Hay's Journal, January, 1871, p. 243.

ence between $\frac{1}{4}$ and $\frac{1}{6}$, we must then subtract 9 per cent., which would leave 81 per cent. of cases with vision $\frac{1}{4}$. Graefe then goes on to state that, out of the 10 per cent. which comprises total failures and imperfect successes, enough would have been benefited by secondary operations to have given a grand total of 94 per cent. of perfect results. Admitting that this "would have been" the case, we must still take, in order to make the comparison a just one, 9 per cent. away, which would leave a grand total of 84.6 per cent. of perfect results against 84 of the second, and 91 of the third series of flap-operations. Thus we see that the balance swings, if any thing, a little in favor of the flap-operation. Whether this may be accounted for in the difference between strictly private and a mixed series of patients, it is hard to say. But what is plain is, that, even in Graefe's hands, the results of each method are so nearly equal, that it is still an open question which is the better; or, to say the least, there is no sufficient cause, so far as statistics are concerned, for the now almost universal belief that the linear is so much superior to the flap.

Were this prevalent opinion, however, founded upon Graefe's results alone, little more would need to be said; but, inasmuch as it has apparently been confirmed by those of others hardly less skilful than he, it may not be without interest to look at the statistics of these operators, scanty though they be, which have gone so far to produce this general opinion.

Thus Dr. Knapp, who is an ardent supporter of the new operation, has published three series of cases of 100 each, which are exceedingly interesting and instructive on account of their fulness of detail in regard to the amount of vision obtained.

In his first series (*Archiv.*, xiii., vol. i., p. 120), Dr. Knapp claims 62 per cent. perfect results. Here he uses, however, vision $\frac{1}{6}$ as a standard of success. If we apply that used in the flap, we find, on looking at the table, that out of the 100 cases he got only 39 perfect results, against Graefe's first and worst series of flaps, which gave 65 per cent. of *immediate* perfect successes; $V = \frac{1}{4}$.

Dr. Knapp remarks that among these cases there is 14 per cent. in which vision ranges from $\frac{1}{40}$ to $\frac{1}{200}$, and which are capable of being improved by a secondary operation. Admitting that one-half are so improved thereby as to obtain vision equal to $\frac{1}{4}$, and this is a large proportion, we then get as a final result $39+7=46$ with vision $\frac{1}{4}$ and over.

In making out his second series (*Archiv.*, xiv., vol. i., p. 316) Dr. Knapp says that "he, as Graefe, and others have done," divides his cases into three classes, which, with their respective numbers in each are, as follows:

Failures 2.
Imperfect results ($V=\frac{1}{12}-\frac{1}{100}$) 12.
Perfect " ($V=\frac{1}{2}-\frac{1}{10}$) 86.

It will be seen from this that Dr. Knapp claims 86 cases out of the 100 of immediate good results; but here another change takes place, and, instead of taking V $\frac{1}{4}$ or even $\frac{1}{6}$ as a standard, he takes $\frac{1}{10}$, and apparently on the authority of Graefe. This may be the case, but I can nowhere find it stated in Graefe's writings that he has ever used a scale of vision lower than $\frac{1}{6}$ as a perfect result, though it is undoubtedly true, as will be seen a little later, that others have done so, and it strikes me as manifestly unjust and unscientific to maintain the superiority of one operation by statistics in which the standard of excellence used is *two and one-half times less* than in the other.

If we look at the table of specific results from which the above classification was made, we see that, out of the 100 cases, there are only 40 in which the vision is $\frac{1}{4}$ and over. That is to say, only 40 per cent. of immediate successes according to the scale for the flap-operation.

We also see that there are 12 imperfect results. Now, supposing we admit with Dr. Knapp that one-half of these imperfect results can be made perfect ones, and that, in all of these, vision can be made, not, as he says, $\frac{1}{10}$, but even $\frac{1}{4}$, and supposing we add these cases to the 40 already perfect, we get as a final result $40+6=46$ cases out of the 100 with $\frac{1}{4}$ and over.

With $V=\frac{1}{10}$ Dr. Knapp makes the final result 93 successes.

In his third series Dr. Knapp has (*Knapp's Archiv.*, vol. i., p. 130):

Failures		3
Imperfect	($S < \frac{1}{10}$)	15
Perfect	($S > \frac{1}{11}$)	82

By looking at the table of specific results, we find 50 cases of immediate good results, $V = \frac{1}{4}$ and over. Admitting with Dr. Knapp that 9 out of the 15 imperfect could be made perfect, and allowing to these cases, as before, $V = \frac{1}{4}$, not $\frac{1}{10}$, which is all that Dr. Knapp claims, we get as a final result $50+9=59$ cases with $V\,\frac{1}{4}$ and over.

Making, now, a comparison between the final results of Dr. Knapp's series of cases by peripheric linear and Graefe's by the flap, we have, arranged in tabular form, something like the following:

Knapp Linear.		Graefe Flap.	
1st series	46	against	80
2d "	46	"	84
3d "	59	"	91

This averaged gives 35 *per cent.* in favor of the flap with vision $\frac{1}{4}$ taken as a standard in each case.

It may be objected that in the above calculation we have taken even a higher scale than did Graefe himself in applying vision $\frac{1}{4}$ to all cases, inasmuch as Graefe made an exception of such as were over seventy-five years of age, reckoning in these cases $V\,\frac{1}{6}$ as a perfect result.

As an offset to this, it must be remembered that we have allowed to Dr. Knapp 8 cases in each 100 with $V\,\frac{1}{4}$, when in the first series $V\,\frac{1}{6}$, and in the remaining two only $V\,\frac{1}{10}$, was claimed.

It might also be objected to as hardly fair to contrast any other operator, however skilful, with the great father of modern ophthalmology; and the above figures would go a good way toward making such an objection valid, especially as Graefe was working under the disadvantage of what is supposed to be an inferior operation. This impression will, however, be corrected, to a degree at least, when we call to mind that it has always been the custom, especially latterly, to look upon Graefe as a great medical philosopher rather

than a skilful and delicate operator, though it would certainly strike one, judging simply from the results which he obtained, that he was in this, as in all other clinical branches of our specialty, immensely superior to any one of this or any other generation.

Becker published (*Zehender*, vol. v., p. 279, 1867) the statistics of 217 cases (150 operated upon by Prof. Arlt), in which V $\frac{1}{10}$ was also taken as a perfect result; inasmuch, however, as no specific details are given as to vision, no satisfactory comparison can be made from them, except that the final result obtained was only 83 per cent. with V $\frac{1}{10}$, and over.

Dr. Derby, of Boston, a warm advocate of the new operation, has given, in an analysis (*Boston Medical and Surgical Journal*, June 8, 1871) of 61 cases of linear extraction, a tabular statement of the vision of 49 patients. Dr. Derby also reckons V $\frac{1}{10}$ and over as a perfect result, and sums up the cases as follows:

Failures	3
Partial success (V $\frac{1}{11}$ to $\frac{1}{20}$)	6
Entire success (V $\frac{1}{2}$ to $\frac{1}{10}$)	43

If, however, we reckon an "entire success" $\frac{1}{4}$ instead of $\frac{1}{10}$, we find, by referring to the table, that there are only 19 such cases, instead of 49.

If of the 9 additional unrecorded cases we assume that 5 will have vision of $\frac{1}{4}$ and over, we get as a final result 24 cases of perfect result out of 61, or 39 per cent.

There are, indeed, other statistics by different operators, all of which, however, are compiled with so little exactness, or founded upon such various and indefinite scales of measurement, as to be of little value for the purposes of comparison. Still, those which have been cited here are enough to show that the want of uniformity in the standard is a serious embarrassment in our making a just comparison, not only between the results obtained by various operators, but even of the true merits of the two methods, and this is the object which we had in view.

And in this connection I would say that I can easily understand how the younger and rising school of ophthalmologists, after having gained their experience in the old meth-

od, with all the numerous mistakes and failures incident to beginners in this difficult and exacting technic, should now obtain, after they have become proficients, better results with the linear than they did at the outset with the flap. For it is certainly easier for a practised hand to change slightly the method of operating, than for a novice to learn how to operate.

What we should like to see done would be, for those who are skilled in both methods, and who have plenty of material, to try them side by side under the same influences and with the same tests. It is only in this way that the two operations can be justly compared. But, if these conditions are too hard to fulfil, we might at any rate expect that the advocates of each method might conform to the very simple condition of using the same standard of measurement, be this what it may.

It may be said that the one originally taken by Graefe, namely, $\frac{1}{4}$, is too high, and that it was probably for this reason that he himself changed it in the linear method. Admitting that this is true, and that $V\frac{1}{6}$ is nearer the mark, the question at once arises, What are we to do, for the sake of study and comparison, with the immense number of cases carefully recorded by Graefe and tabulated under the scale of $V = \frac{1}{4}$ —cases which, from their great number and from the vast amount of instruction which they embody, form one of the most brilliant pages in the whole annals of modern ophthalmology? And, if, to suit the progressive spirit of the age in its craving for "perfect results," we go successively from $\frac{1}{4}$ to $\frac{1}{6}$, and to $\frac{1}{10}$, where, may we ask, shall the end be?

I would say, further, Mr. President, that these remarks are not in any way meant as a criticism on either operation. Had they been so, reference would have been made to many things which have not even been mentioned, and certainly to the change instituted by Graefe himself, from a wound which was entirely in the sclera to one which is two-thirds or more in the cornea, and from the slight arc latterly sanctioned by Graefe to a gradual increase in the curvature of the section, till, in the hands of many operators, both in Europe and this country, the only appreciable difference between the new operation and the

flap with a concurrent iridectomy is the difference between the old and the new knife.

The discussion of these points, as well as the final decision as to the merits of the respective operations, I feel had much better be left to those of my colleagues whose experience is richer and whose judgment riper than my own.

AN APPARATUS FOR TESTING THE PERCEPTION OF COLOR. By Henry D. Noyes, M. D., New York.

The examination of a patient's ability to discriminate colors I have found to be a time-consuming proceeding, and have been at a loss how to register the results of the examination in a graphic and satisfactory manner. To obviate in some measure these difficulties, and because I appreciate the importance of making these investigations, I have adopted some simple contrivances which I beg leave to describe.

I paste upon a circular piece of card-board the slips of colored paper which I use as tests. They are put on in sectors of the circle, and may be as numerous as is thought needful. I have divided the circle into ten sectors, and have put on it two shades of five colors, viz., red, blue, yellow, green, and purple.

This disk is covered by another whose surface is black, and whose diameter is half an inch smaller. In this top disk a notch is cut, corresponding to the size of one of the colored sectors of the other disk.

The covering disk or screen is attached to a handle, and is pierced through its centre by a pivot on which the colored disk is to rotate. The latter, moreover, has broad notches cut into its rim, like teeth in a cog-wheel, which correspond in number to the colored sectors, and are so placed as to give ready hold for the forefinger or thumb to rotate it. The whole affair looks something like a palm-leaf fan. In examining a patient, he is placed before a black-board and told to fix one eye upon a distinct mark near its centre. The color-test is presented to his view in different parts of the field just as is done usually with a bit of white chalk. The disk is held in

one hand, and by the finger or thumb of the same hand rotating the outer disk a succession of colors is presented to the patient's notice. To register the findings of the examination upon the black-board, it is needful simply to select

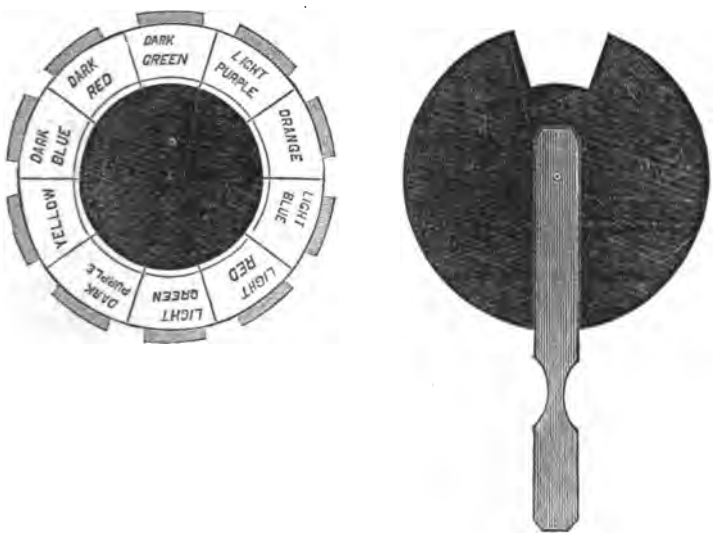

FIG. 1.

crayons corresponding in tint to the colors employed, and, with the proper chalk, mark upon the board the place where each color is perceived. The usual way of getting the visual field with white chalk is thus applied to color-tests. The method being simply to employ colored chalk in one hand to mark upon the board the spots where the colors successively exposed to his view upon the disk in the other hand are recognized. When the examination is complete, a number of colored tracings are upon the black-board, which may be transferred to a note-book, on a reduced scale, with precisely the same crayons.

DESCRIPTION OF A JAEGER OPHTHALMOSCOPE, AS MODIFIED. By Dr. George Strawbridge, Philadelphia.

The apparatus can briefly be described as follows: The body of the instrument consists of a short cylindrical tube fitted into a ring, and so arranged as to permit of rotation on its axis. At its anterior extremity, it is so cut away as to cause its anterior surface to form with the cylindrical axis an angle of 60°; on the anterior border of the tube are found two notches made to hold the arms of the reflector, and on the side of the notch is placed a small spring for fixation of the reflector. The longest side-wall of the cylinder has a length of one inch, while its shortest side has a length of two lines. The posterior end of the tube is closed by a diaphragm, having a central opening of three lines diameter; and on its posterior surface are fastened a spring-catch and axle for holding a disk in position and permitting of its rotation. To the ring, grasping the cylinder, is fitted a handle made to close in itself (as the blade and handle of a knife), and so economizing room. The ophthalmoscope contains a "strong light" and "soft light" reflector. The first is a concave glass reflector of seven inches focus. The latter consists of three plane, parallel, transparent, thin glass plates, fitted in a metal frame and so fastened that they can be easily taken apart and cleaned; between each of these glass plates is placed a thin metal ring for the purpose of preserving an intermediate thin layer of air. The apparatus contains, in addition, a convex lens of two and a half inches focal distance, fastened in a ring for convenience in holding; and, finally, twenty correction-glasses placed in three metal disks; each disk having seven openings for this purpose' The first disk, which may be called the "the working-disk,'

is divided as follows: First, an opening for observation of the eye with the reflector alone. Secondly, a convex eight glass for examination of the inverted image; and, finally, concave glasses Nos. 10, 8, 6, 4, 3, for examination of the erect image. For an ordinary examination this disk alone will generally suffice.

The second disk contains convex glasses Nos. 48, 30, 24, 16, 12, 10, 7. The third disk contains concave glasses Nos. 30, 24, 16, 12, 7, 5, 2; and it is believed that this collection of glasses will be found sufficient to determine the greater number of refraction anomalies.

The disk rotates behind the opening in the diaphragm, and by means of the spring-catch each glass as it rotates is caused to stop exactly behind the centre of the opening, and at the same time the arrangement allows of the disk being quickly removed and another substituted—on the same principle as Dr. E. G. Loring, of New York, has made use of in the construction of his ophthalmoscope, and from whom the idea was derived. The entire apparatus is contained in a box $4\frac{3}{8}$ inches long and $1\frac{7}{8}$ inch wide.

The chief advantages of this form of ophthalmoscope consist in the fact that it has the "weak light" reflector as well as the "strong light" reflector. Also, that these reflectors have two motions, one on their own axis and one on the axis of the cylinder, and so permit of great variety of position, while at the same time the correction-glasses remain stationary, thus avoiding any prismatic effect from the correction-glass. Finally, the arrangement of the correction-glasses in a disk avoids the trouble which is occasioned by adjusting each glass separately, and at the same time the collection of glasses is sufficiently large to admit of the determination of a refraction anomaly in a case where a box of glasses is not attainable.

GUNSHOT-WOUND OF THE BRAIN, FOLLOWED BY FUNGUS CEREBRI, AND RECOVERY WITH HEMIOPSIA.[1] By W. W. Keen, M. D., and William Thomson, M. D.

Case I.—Patrick Hughes, late private of Company K, Fourth Regiment, New York Volunteers; born in 1839, in Ireland; puddler both before and since enlistment; wounded at Antietam, September 17, 1862. Wound of entrance in the middle line, one and a quarter inch above external occipital protuberance—a small, depressed wound; wound of exit two by two and a half inches, its centre being two inches to the left of middle line, and three inches above wound of entrance. He fell, did not lose consciousness, but, blinded by blood, crept toward the enemy till warned by his comrades, when he crawled behind the ranks, and was carried, when faint, to an old barn, where he remained nine days. While here, his eyesight, he thinks, was poor. He was then taken to Mount Pleasant Hospital, Washington, D. C., where he lost his consciousness, and was more or less paralyzed in both right arm and right leg—whether slowly or suddenly, and whether it extended to the face, he does not remember. The paralysis and unconsciousness lasted some two or three months. He remembers having had fungus cerebri as large as his fist, which was shaved off some five or six times. When he tried to think, he often used to become almost "out of his head." His memory was so bad that, between calling the doctor and his turning to hear the question, he would forget what he desired to say. He had no aphasia. In four and a half

[1] Extracted from the Photographic Review of Medicine and Surgery for February, 1871.

months he was able to come to Philadelphia. In walking he was very giddy; noise and laughter used to hurt him badly. His mental and physical power gradually grew better, and in one year his paralysis had almost disappeared.

Present Condition, December 20, 1870.—His memory is quite good, but by no means so good as before the injury. He is rather easily bothered and confused, and more irritable than formerly. The sight of his right eye, he thinks, is poor. Whiskey affects him as usual. Sexual power undiminished. He has no paralysis. The wound of entrance (see photograph—the head was shaved in order to have the photograph taken) is marked by a slight depression in the bone, the wound of exit by a hollow two and a half by two inches, and one inch deep. No bone has closed this opening, but the scalp and hair dip down into the hollow. The arterial pulsations are barely perceptible. When recumbent, the hollow is gradually obliterated and replaced in about one minute by a rounded protuberance. To prevent pain during this change, he supports the parts with his hand. When he coughs, even with moderate force, the depressed scalp instantly bulges up in a cone, which nearly reaches the general level of the skull and obliterates the depression, and then as suddenly subsides.

The eyes, upon examination, present the following conditions: There is no ptosis on either side; entire mobility of the eyes under direction of the will; both pupils normal in size, and responsive to light. Upon the left cornea is to be seen a slight leucoma, the result of a burn from a piece of metal, received two years since. In all other respects both eyes are, in appearance, perfectly normal. Refraction of each eye is found to be emmetropic. The acuteness of vision is for the right $\frac{1}{1}$, and for the left $\frac{1}{1.5}$; the slight impairment of vision being due to the result of the burn, which caused not only slight opacity of the cornea, but also irregular astigmatism. The power of accommodation is for each eye $\frac{1}{4.5}$. There is no diplopia, and no insufficiency of either internus.

Upon testing the field of vision, it is found to be divided for each eye by a line passing through its centre, in the vertical direction—total blindness existing to the right, and per-

fect vision to the left, of this line. When, for example, the right eye is fixed upon a point of light eight feet distant, a second point of light is lost to view when it is moved one inch and a half toward the right in a horizontal line; and precisely the same condition exists for the left eye—i. e., the light is lost one inch and a half to the right of the median line. With the *right* eye it is not possible to determine the spot of Mariotte —that is, the blind spot in the field corresponding to the entrance of the optic nerve (*see* the diagram, p. 29)—since the insensitiveness of the retina in that eye commences at the inner margin of the macula lutea, and extends to the entire inner half of the retina. With the *left* eye, that portion of the retina between the optic-nerve entrance and the macula is found normal in sensitiveness; since, when at four feet the left eye is fixed upon a point of light, a second light is clearly perceived as it is moved toward the left until it has reached a point about nine inches to the left, where it is lost, to reappear at a point about thirteen inches from the first light. Beyond this point the field has its normal extent.

By ophthalmoscopic examination no pathological appearances whatever could be observed, either in the retina or at either optic papilla, beyond the distortion caused in the left eye by the astigmatism, probably of traumatic origin, as mentioned above.

Remarks.—I. This case is briefly referred to in Circular No. 6, S. G. O., 1865, at the bottom of page 15; and Dr. Otis writes us that it will be fully related in the first volume of the "Surgical History of the War," with the chromo-lithograph of the fungus cerebri. As it must first be presented to Congress and published by the Department, no opportunity was presented us of correcting the history by these notes. The history here presented, therefore, as derived from the patient, must be taken with some caution, since the wound has so severely injured his cerebrum. On all points, however, he gave very clear statements.

II. The complete recovery from paralysis (as evinced by his subseqent severe labor), and the almost entire restoration of his mental faculties, are remarkable, especially in view of the probable deep lesion of the brain, both by the primary injury and the subsequent fungus cerebri.

III. The astonishing and rapid changes in the state of the cranial contents, due to any change in position, to coughing, etc., as evinced by the effacement of the depression at the wound of exit, are worthy of note. Whether due to a flow of cerebro-spinal fluid (which would be the principal agent in a change of posture), or to venous congestion (as in coughing), the case shows that our attention has been far too slightly fixed on the medical bearings of such facts in all cases of severe cough, and on their surgical bearings in operations for cataract, etc., during the existence of bronchitis.

IV. The light thrown on the probable anatomy of the optic commissure is also worth our notice.

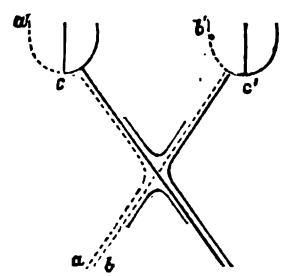

Diagram of the optic commissure and the two retinæ.—*a*, *b*, the fibres of the left optic tract supplying, respectively, the left halves of the two retinæ *a' b'*; *c*, *c'*, the maculæ luteæ.

The inter-retinal and inter-cerebral fibres are merely indicated.

Wollaston (Phil. Trans., 1824, p. 222), reasoning from two attacks of transient hemiopsia, occurring in himself, and other cases in friends, appears to have been the first to point out the semi-decussation of the optic nerves at the chiasm. Longet ("Traité de Phys.," 2d ed., ii., 476) seems to assent to the explanation, though he refers to cases of perfect sight in which, it is asserted, no chiasm existed; and in his "Traité d'Anat. et de Phys. du Syst. Nerv.," p. 666, he gives cases of perfect sight in both eyes, in spite of unilateral cerebral atrophy or traumatic lesion. Von Graefe (*Archiv.*, ii., 286) assents cordially to Wollaston's view, admitting that he proposes nothing new, but that it is far too little known.

Hubert Airy (On a Distinct Form of Transient Hemiopsia, Proc. Roy. Soc., February 17, 1870, in *Nature*, i., 444), after a careful examination of preceding writers, also supports it; and the experiments of Laborde and Leven (*Med. Gaz.*, November 5, 1870; from *Gaz. Méd. de Paris*), who found atrophy of the right optic nerve following the removal of the superficial right cerebral convolutions, and without any apparent irritative processes, would also point in the same direction.

In our own case the point to which we desire to call special attention is the rigid optical examination of the region between the porus opticus and the macula lutea. The semi-decussation of the nerves at the chiasm being admitted, it would naturally be supposed that the fibres *a* from the left tract would supply the left retina from the porus opticus toward *a′*; but our examination shows that it supplies *less* than this, viz., only that part of the retina from *c* to *a′*; while in the right eye the fibres *b*, instead of supplying the retina from the porus opticus to *b′*, supply *more* than this, viz., that part of the retina from *c′* to *b′*. In other words, the fibres *a* and *b* of the left optic tract supply mathematically the left halves of the two retinæ from *c* to *a′* and *c′* to *b′*, and the right tract the right halves.

V. As to the cerebral seat of the sense of vision, the amount and depth of the injury to the brain are too uncertain, perhaps, to warrant us in venturing on any speculations as to its locality.

Note to Case I.—These examinations were made in the usual manner, with a black-board and chalk, with two bright points of light, and with Förster's apparatus. The man was intelligent, possessed normal acuteness of vision, and became well trained in the methods of investigation employed, and these considerations give interest to the fact that, *at the point*

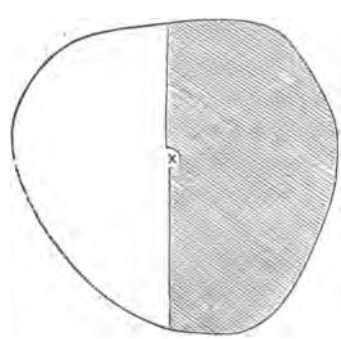

Field of right eye.

of fixation, the vertical line which bisected the field seemed to deviate slightly toward the defective side. Above and below a horizontal line through the field at the point of fixation, the

limitation was strictly vertical, while in the horizontal line, at a distance of eight feet, a moving light could be carried for one and a half inch from the fixed one before being lost to view. Due allowance must be made for the possible eccentric fixation of the patient, and for his having inadvertently *followed* the moving light for this short distance.

Case II.—Reported to the Society by Dr. W. Thomson. Joseph Rowan, aged fifty-five, disabled by partial paralysis of motion of left side, states that he had a sunstroke seven years since, and a second one three years ago. His hemiplegia is now of two years' standing. Sensation on both sides is unimpaired.

Vision. R. $\frac{1}{4}$ L. $\frac{1}{2}$ Refraction Hy. $= \frac{1}{20}$ with $+\frac{1}{20}$ Vision. R. $\frac{1}{2}$ L. $\frac{1}{2}$ $A = \frac{1}{14}$

No ptosis, nor muscular insufficiency. Right pupil slightly larger than left. By ophthalmoscope, both eyes are normal in appearance.

The field of vision of each eye is bisected by a vertical line, to the left of which there is entire blindness, as tested by the black-board and chalk, as well as by two bright points of light.

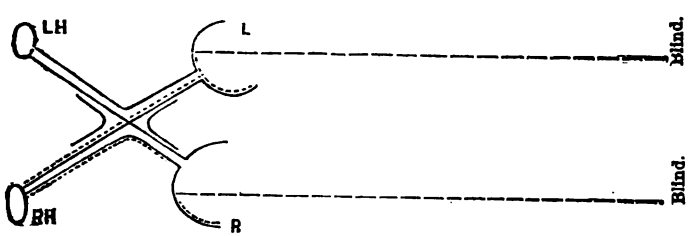

No effort was made in this instance to ascertain whether the field was limited strictly by the vertical line at the point of fixation, since the intellection of this patient seemed so far impaired as to render it impossible for him to sustain the mental effort requisite to complete so refined a subjective examination.[1]

[1] Confirmed by Dr. C. A. McCall, U. S. A., who had him in charge at the time.

DETACHMENT OF THE RETINA, WITH LACERATION AT THE MACULA LUTEA. By Henry D. Noyes, M. D., New York.

Miss Carrie S., aged thirteen, New York, was struck in the left eye, three years ago, by a cork which popped from an ale-bottle; sight was lost immediately. When the stinging pain of the blow subsided, she experienced no suffering, and no inflammation ensued. The eye has remained in the same condition, with the exception of slight divergence. There is now obtuse perception of light; pupil contracts as usual. After using atropia, ophthalmoscopic examination showed the following appearances:

The optic nerve clearly defined and normal. The retina lifted up by a stratum of fluid, which is most abundant below and to the outer side. In every part of the fundus this effusion can be discerned, but nowhere is it in considerable quantity. It is almost transparent. The detached retina can be sharply defined in the upright image by aid of a convex 10 glass, the observer being accustomed to complete relaxation of accommodation. This would give about one millimetre as the thickness of the fluid. The retinal vessels have the customary dark color and tortuousness which belong to this lesion. At the middle of the fundus the retina becomes of grayish-white color, and at the macula lutea is a round red spot of about half the diameter of the optic disk. When observing the contiguous retina with +10, its texture is clearly seen, and, besides having a slightly-granular look, it is marked by fine streaks or plaits, which radiate from the red spot. Under this inspection the red spot shows no detail, although its edge is sharply defined. But, when the red spot is scrutinized without a glass, it no longer appears as a blur, but exhibits a distinct, reddish, granular

look, and it is evident that one is looking at the epithelium of the choroid. At the same time the adjacent retina assumes a blurred appearance, because not in focus; the radiating striæ are not to be seen.

The difference in depth of these two surfaces at once suggested the idea of a laceration of the retina at the macula lutea, and that the red spot was simply a hole through which one could look upon the choroid.

Further and undeniable proof of this explanation of the lesion was found in the phenomena of parallax which were detected by slightly changing one's point of observation. In making such slight movements from side to side, the edge of the opening could be made to conceal and disclose a definite point at the margin of the bottom of the red spot. The edge of the spot was not tremulous, nor was it ragged, nor was there any tissue sloping down from it toward the spot. Critical inspection made it evident that one could look under the retina. I have no explanation to offer of the mechanism of this peculiar rupture of the retina. It is the only instance of this kind which I have ever seen or read of. This much may, however, be suggested, that at the macula the retina is thinner and necessarily weaker than at any other part, and it has a faint amount of coherence with the choroid. The perfect transparency of the vitreous forbids the idea that the retina became detached by adhesion to a shrinking corpus vitreum, and hence we must admit that the effusion was the direct result of the blow. Doubtless this fluid, which now is almost entirely transparent, was at first more or less bloody. It does not at present appear to be perfectly limpid, and Dr. F. Delafield suggested that it might be somewhat gelatinous. The doctor was kind enough to examine the eye, and was able to verify the appearances described, and could suggest no other diagnosis than that this was in truth a hole torn through the middle of the retina. So regular is it in outline, so free from traces of shreds or fringe on the edge, that it might have been cut out with scissors or made with a punch.

In no case of tearing of the retina from bursting of fluid through it have I ever seen any approximation to this shape. The rents have been linear, or curved, or tongue-like. They have usually been near the equator of the globe.

REPORT OF PASSAVANT OPERATIONS WITH AND WITHOUT ETHER, AND ALSO UNDER NITROUS OXIDE. By B. Joy Jeffries, M. D., Boston.

Since my report last year to the Society of the results of thirteen Passavant operations for breaking up posterior synechiæ or attachments of the iris to the capsule, I have successfully employed it in the following cases:

A woman has had chronic irido-choroiditis, and, as sequelæ, some four or five attachments of the iris to the capsule. Around these the pupil dilates, showing the iris-tissue to be still good. There is constant trouble from the eye, aggravated, I judge, by the dragging of these posterior synechiæ. Therefore, under ether, I broke away two that were close together at the upper side. After breaking one, and the aqueous had escaped, I found no great difficulty in pushing the point of my closed forceps between the iris and the cornea, against which it of course laid, to reach the next one close beside it. In a few days I broke another at the opposite side of the pupil, also under ether. The patient was rendered quite sick and uncomfortable by the ether, so much so that I proposed to her trying to break the next without anæsthetic. This she consented to, and I succeeded without difficulty. She did not complain of the pain as being very great, the dragging on the iris seeming to be the most painful part. That it was not severe was certainly proved by her preferring to have the fourth and last operation also done without anæsthetic. With a little care and command over the patient, I had no difficulty in holding the eye sufficiently steady. A compressive bandage was each time left on overnight. The aqueous humor is,

however, much sooner resecreted, and corneal wound closed. The patient went back to her occupation in a store, within forty-eight hours after the last operation, the eye now being hardly, if any, troublesome.

Another case was that of a man injured by the premature discharge of a blast. The face and eyes were full of powder. He had had traumatic iritis in the left eye, and atropine showed three broad posterior synechiæ. Both corneæ were so filled with powder, and the eyes in such a bad condition, that I judged it best to remove as many of the grains of powder as possible, and for that purpose kept him under ether some time, since he could not have held the globe still enough to work without. He was miserably sick from the ether, and dreaded taking it again. I therefore very gladly availed myself of the kindness of Dr. Robert Amory in offering to give the patient nitrous-oxide gas. As he has reported on the special method of administering this anæsthetic, I omit speaking of it here, except to say that, after the mouth-piece was removed, I had more than ample time to carry out my operation—time enough to have performed an iridectomy, or even a longer operation. For such short operations, not followed by pain, I regard the nitrous oxide as invaluable. Passavant's operation has to be repeated as many times as there are widely-separated attachments, and, although I persuaded one patient to submit to it seven times under ether, we shall not always be so fortunate. The posterior synechiæ were so broad in this case, and the iris poseibly friable, that I did not like to attempt to break them away without an anæsthetic, for fear of the pain. The patient was perfectly satisfied with the gas, experiencing no pain whatever. A compressive bandage was kept on a few hours after each operation. The three operations have resulted in leaving a free movable iris. Spots of pigment, where the attachments were, are seen on the capsule. To what extent they will disappear I will not attempt to say. Judging from previous cases, I think all lymph will be gradually absorbed.

A man, aged sixty, has had granulations, ulcers of the corneæ, etc. The results are, central corneal opacity in the right eye, with anterior synechia, and a single posterior synechia downward in the left eye.

May 23, 1871.—An iridectomy for artificial pupil was done on the right eye, and a Passavant on the left, perfectly freeing the pupillary edge of the iris.

A man, aged twenty-three, has run through with a fearful attack of syphilis, leaving, as sequelæ, total posterior synechia and closed pupil in the left eye, and three or more attachments in the right.

May 6, 1871.—Iridectomy downward for artificial pupil was done on the left eye, and by a Passavant the attachment below broken in the right eye. Atropine now keeps *this clear* of the capsule, although there are still two attachments above.

May 30*th*.—I made two corneal openings with a broad needle opposite the two attachments, and broke them both, one after the other. The flowing off of aqueous did not prevent my sliding the forceps between the cornea and iris without injuring the capsule. The two punctures did not cause the loss of a whole drop of aqueous fluid. This procedure, of course, saved one additional operation.

A man, aged thirty-two, has in the right eye total posterior synechia, lens opaque, iris discolored, globe soft, vision gone—the result, seemingly, of old irido-choroiditis. In the left eye there have lately been slight irido-choroiditis, and a resulting rather broad synechia downward, which was broken May 30, 1871, and the released iris gave a circular pupil. I looked upon this attachment, perhaps of old date, as a readily-exciting cause of fresh inflammation.

In these seven, and the thirteen operations previously reported, I did no harm to the capsule, and certainly improved the condition of the eye. In the second operation in the last case, owing either to the close and broad attachment, or my not grasping the iris deeply and firmly enough, it was a little torn, and a filament dragged into the wound. It, however, entirely replaced itself before the eye was bandaged, and no traces are now seen.

With Dr. Passavant, as with me, this operation has always been successful; I therefore think it proper to quote the following, from the *Medical Times and Gazette* of May 29, 1870, by Dr. Alex. Ogston, of Aberdeen, who, in referring to Dr. Passavant's article, says: "This paper of Dr. Passavant

appeared so honestly written that a trial of his method was instituted in the next case that presented itself in the Aberdeen Hospital. In this case, as in all the cases where I have tried it, the operation was followed by no bad results as regards the iris; but, though the adhesion was seen to tear, the contraction of the pupil, which invariably followed on the escape of the aqueous humor, allowed the two ends of the adhesion to lie so close to each other that they united again in spite of the free use of atropine, and by the time the corneal wound was healed the same state of matters existed as before the operation, only the adhesion was not so broad as before."

As Dr. Ogston does not minutely describe his method of operating, I can only imagine his results were due to having made a larger and more peripheric wound in the cornea than was necessary, whereby the aqueous chamber was not quickly enough reëstablished. I found no such trouble as he describes. He now operates in a different, and, as I contend, much more dangerous method, namely, he passes a not too sharp needle into the aqueous chamber opposite the point of iritic attachment, and, engaging the point of the needle in the iris tissue, forces it away to break the synechia, using the hole in the cornea as a fulcrum. The unnecessary danger of wounding the lens, and thereby producing cataract, which we must run in such a procedure, would be sufficient to induce me to hold to Dr. Passavant's method, which I have so far always found successful, and not so very difficult for those accustomed to ophthalmic operations, especially as I am now convinced it can be readily performed under nitrous oxide, a hundred gallons of which anæsthetic may be carried about with perfect safety in a case twenty inches long and eight square, as Dr. Amory has practically demonstrated.

Instead of an iridectomy-knife, I now use a broad paracentesis-needle. I find no difficulty in manipulating my delicate forceps in the corneal wound this makes, and I lose but little aqueous before the iris is grasped, when the escape of the fluid rather assists in the breaking the attachment. Atropine is continued, and the humor secretes so quickly, that there is no time for the iris to again fasten itself to the capsule. I have occasionally succeeded in not losing all of the aqueous humor during the whole operation.

CASE OF READJUSTMENT OF THE LEVATOR MUSCLE OF THE UPPER LID. By JOHN GREEN, M. D., St. Louis, Mo.

READJUSTMENT of the levator of the upper lid has been but rarely performed, and has still more rarely been followed by restoration of the proper function of the muscle. In fact, the reported cases of this operation have been, for the most part, in paralytic ptosis, where we should, *a priori*, expect least from it. In the following case the ptosis was traumatic, and the indications for operation were substantially the same as in the operation for readjustment of the internal rectus:

—— Williams, five years of age, son of Dr. A. G. Williams, of Dongola, Illinois, was gored over the left eye by a cow, about two years before I saw him. The whole upper lid was torn from its attachments, with the exception of a narrow bridge at the outer end. The wound was dressed by the father, who reunited the severed integument quite accurately by sutures. Complete and accurate union of the skin was obtained, but with considerable irregularity of the conjunctival surface of the lid, and with complete ptosis. The eye was wholly uninjured.

I first saw the boy, in consultation with the father, March 15, 1871. The left upper lid appeared considerably thicker than the right, partially from an overlapping of the tarsal cartilage, which seemed to have been torn across about the middle of its length, and in part from a somewhat excessive quantity of subcutaneous adipose tissue just above the upper border of the cartilage. There was no sign of any action of the levator muscle in any of the movements of the eyes, but the lid hung motionless, except as it was lifted slightly by the contraction

of the occipito-frontal muscle drawing upon the skin. There was no impairment of vision, nor any restriction of any of the movements of the eye. The case was evidently one of complete detachment of the tendon of the levator, without other injury of importance. I decided to make an attempt to find the severed tendon, and reunite it to the tarsal cartilage. The operation was performed March 19th, with the important assistance of Dr. T. F. Prewitt.

An incision, of rather more than an inch in length, was made through the skin along the upper border of the lid, and the dissection extended through the subcutaneous fatty tissue in a direction nearly backward, so as to avoid opening the conjunctival sac. The upper surface of the eyeball was thus reached without having encountered any fibres of the orbicularis muscle, or in fact any other tissue than the subcutaneous fat, which was apparently continuous with the fat of the orbit. A broad, thin tendon was seen spread out over the exposed part of the globe, which proved to be the tendon of the superior rectus. Between this and the roof of the orbit the tendon of the levator was easily discovered, and no difficulty was experienced in attaching it, by three sutures, to the front of the tarsal cartilage. The wound was then closed by three other sutures, leaving the ends of the three deep sutures protruding externally.

The subsequent swelling was very moderate, and the external wound healed promptly without suppuration. The superficial sutures were removed on the fourth day, and the deep sutures left to become detached spontaneously. The boy was allowed to go home on the fifth day, the levator muscle evidently performing its function, although impeded in its action by the swelling of the lid.

Two months later the father wrote to me as follows:

"*May* 22, 1871.—The operation was a perfect success; the muscle united by first intention, and the eye opens and shuts simultaneously with the other."

ADDITIONAL NOTE UPON THE USE OF ATROPIA IN THE TREATMENT OF INCIPIENT STRABISMUS. By John Green, M. D., St. Louis, Mo.

In the Transactions of this Society for 1870, I reported three cases of periodic convergent squint, in which the repeated instillation of atropia constituted an essential part of the treatment. The applicability of the method to the incipient stages of strabismus occurring in young children is my excuse for again briefly calling attention to the subject.

The conclusions at which I have arrived, as the result of another year's experience, may be briefly summed up as follows:

1. In even a very young child (in one case a child of three years), with commencing strabismus dependent on hypermetropia, the repeated instillation of atropia, to the point of completely suppressing accommodation, leads to the speedy abandonment of the habit of squinting, and the substitution for it of a kind of scowl, having for its object the exclusion of peripheric rays of light by the partially-closed lids.

2. The artificial amblyopia resulting from the total suspension of accommodation supplies a needed motive for the acceptance of convex glasses, which, in turn, by relaxing accommodation, tend to postpone the return of the deviation as the effect of the mydriatic passes off.

3. By repeating the instillation of atropia as often as signs of returning deviation appear, the habit of squinting may be effectually broken up, and the case at last brought fully under the control of convex glasses. This result is sometimes attained in the course of a month, but, in one case, of three years' standing, even at the end of eight months it was necessary still to resort to the atropia at intervals of from two to three weeks.

4. These results have been attained in three cases of periodic squint of fully three years' standing.

5. In cases of permanent deviation, in which parallelism of the visual axes no longer occurs even in perfect rest of the eyes, the effect of the treatment (whether atropia alone or atropia conjoined with glasses) has been confined to an improvement in the position of the eyes. In such cases, however, we have in the degree of the remaining squint an important index of the actual shortening of the interni, and a guide to the extent of the correction to be sought from tenotomy.

From these statements it will be seen that the success thus far attained by this plan of treatment is limited to the preservation of binocular vision through the wearing of convex glasses. This is, however, an advantage of no small importance, when we consider how rarely we are able to restore perfect binocular vision, after it has been once positively lost in consequence of the complete development of a squint. I am convinced that it is far better to arrest the deviation, and at the same time preserve binocular vision, than to sacrifice binocular vision and trust to a future tenotomy to cure the deformity. The danger of accidental injury from the wearing of glasses by a young child may be reduced to a minimum by making the frames strong, and of a somewhat flexible metal, like silver, and choosing the lenses of extra thickness as a safeguard against breaking.

PARALYSIS OF THE TRIGEMINUS, FOLLOWED BY SLOUGHING OF THE CORNEA. By Wm. F. Norris, M. D., Philadelphia.

W. McC., aged forty-two, horse-jockey, came to the clinic of the University of Pennsylvania, September 11, 1871, complaining of an inflammation of the left eye. The patient is pale and emaciated, and has a large epitheliomatous growth at the left angle of the mouth, which he says has existed for several months.

The left eye has been sore only one week, and the conjunctiva now presents a bright-red hue, but remains transparent and without granulations. There is slight bulbar chemosis and a punctated keratitis, most marked at the centre of the cornea, which renders it difficult to see the iris except at its periphery. It appears, however, to respond to the stimulus of light, and certainly dilates under atropine.

There is a slight drooping of the eyelid. The eye is mobile in all directions, but has lost its sensibility, and the cornea and conjunctiva may be touched without his evincing any consciousness of it. There is also impaired sensibility both in the skin and mucous membrane of the left side of the nose. The sense of taste seems also impaired, and salt placed on the left side of the tongue is much less promptly recognized than on the right. There is slight paresis of the left facial nerve, and marked deafness on the same side—does not hear a watch on contact, and a tuning-fork held at the vertex is heard only on the right side.

A solution of atropine was instilled into the eye, and a compress bandage applied so as completely to close the lids. This was removed twice daily, to cleanse the eye, and immediately reapplied to prevent the ingress of dust or other foreign

bodies. Notwithstanding these precautions, the inflammation of the cornea progressed, and a small slough formed at its centre, and separated. The minute aperture thus caused was blocked up by the iris, and subsequently showed as a central black spot.

September 20th.—He for the first time experienced a sensation of dizziness, and found that he could with difficulty walk straight. This feeling however, soon passed off, and up to date he has driven a pair of horses daily in the park.

October 15th.—He has been absent from the clinic and confined to the house for the last two weeks, owing to the tumor at the angle of the mouth becoming inflamed and ulcerated. During this interval he has had repeated attacks of dizziness, usually occurring in the afternoon, and causing him to stagger in walking. His gait is now habitually unsteady.

The limbus cornea above and below has become vascular, and next to it is a comparatively clear rim of corneal tissue, which is separated by a sharply-cut groove from the opaque central portion.

The right eye is healthy and emmetropic, $V=\frac{20}{XX}$.

October 15th.—The eye is more inflamed, and there is marked hypopyon.

October 20th.—There is less inflammation, and the pus in the anterior chamber has been absorbed.

On this day Dr. Garretson removed the epithelioma at the angle of the mouth, and the patient passed from my observation. Through his kindness I learn that on the 24th and 25th there was violent pain in the head, the patient crying out that "it would kill him." On the 26th the pain was still severe, but was more in the neck and cheek. From this date, although the attacks of pain were much less frequent, and his mind, which had been wandering, became more clear, the patient gradually grew weaker, and on the 21st November died. No autopsy was allowed.

The interest of the above-detailed case centres in the fact that, although the patient was seen at an early stage of the inflammation of the cornea, the most sedulous care in cleansing the eye and protecting it from external irritants, did not prevent the necrosis and perforation of the central portion of the cornea.

Inasmuch as the views of physiologists as to the influence of the trigeminus in the nutrition of the cornea are so diverse, it may be of interest to recapitulate the results of a few of the more prominent experimenters. Herbert Mayo [1] showed that section of the fifth nerve within the cranium produced insensibility of the eye. Charles Bell [2] recognized the fact that the sensibility of the eyeball was due to the fifth nerve, and maintained "that, when that sensibility is destroyed, although the motions of the eyelids remain, they are not made to close the eye, to wash and clear it, and, consequently, inflammation and destruction of that organ follow." Magendie [3] showed that section of the nerve in rabbits produced anæsthesia of the eye and inflammation and sloughing of the cornea. He, and after him, Longet, found that section of the nerve anterior to the ganglion of Gasser was more likely to produce this effect than section posterior to it. The latter [4] attributes the changes which take place in the eye to impaired nutrition, and argues that they cannot be due either to diminished secretion of tears or to the insensibility of the eye, because neither the more complete dryness of the ball, after extirpation of the lachrymal gland, nor the prolonged contact of the air in paralysis of the facial nerve, produces the same effects.

Graefe [5] experimented on rabbits, and found that intracranial section of the trigeminus caused insensibility of the ball, and complete opacity of the cornea, which in his experiments never went on to perforation. He maintained that the trigeminus is in part a trophic nerve, and that the destructive changes ensuing in the eye are not alone due to insensibility to external irritants, because extirpation of the tear-gland and cutting off both eyelids do not produce the same effect—the cornea remaining transparent. He also adduces pathological cases (in man) in which perforation of the cornea occurred.

Snellen [6] cut the trigeminus in rabbits, and found that, when he protected the eye, by sewing the yet sensitive ear

[1] Anatomical and Physiological Commentaries, Lond., 1822, No. II., p. 5.
[2] Nervous System of the Human Body, London, 1830, p. 207.
[3] Journal de Physiologie expérimentale, tome iv., pp. 176–183, 1824.
[4] Anatomie et Physiologie du Système Nerveux, t. ii., p. 161, Paris, 1842.
[5] Archiv. für Ophthalmologie, Band I., Abth. I., S. 306–315.
[6] Virchow's Archiv., 13 Bd., S. 107, 1858.

over it, the cornea remained intact for ten days, but that without this precaution it rapidly clouded. He has since published a case in a middle-aged man, where the eye improved when placed under a stenopaic shell, and the acuity of vision rose from $\frac{20}{CC}$ to $\frac{20}{XX}$. When the protection was removed it again sank to $\frac{20}{C}$, and immediately improved on its reapplication. He therefore argues that the changes in the cornea are traumatic, and not due to any trophic influence of the ganglion of Gasser.

Meisner[1] holds that the inner fibres of the nerve are more important than the outer for the preservation of the cornea, because, if the nerve be only partially divided and the former left intact, the cornea, although insensible, does not become opaque.

Schiff[2] arrived at much the same conclusions.

Finally, Sinitzin,[3] from experiments on rabbits, advances the following views:

1. That extirpation of the superior cervical ganglion of the sympathetic caused congestion of the choroid, and increased the temperature of the eye.

2. That the cornea in the operated side became more capable of resisting external irritants.

3. That, after cutting the trigeminus in front of the ganglion of Gasser, neuroparalytic affection of the cornea does not ensue, if the superior cervical ganglion of the sympathetic be at the same time extirpated.

4. That, after such changes have set in, they become retrograde, and disappear after extirpation of the ganglion.

5. That this is possible, so long as the cornea has not become dry and horny, and that even at this period it arrests further destruction.

6. That ulcerations of the lips and lids also disappear, and that, to allow repair to take place, it is not at all necessary to protect the eye.

[1] Henle and Pfeuffer's Zeitschrift (3), xxix., p. 96 (quoted by Wells).
[2] Ibidem, p. 217 (quoted by Wells).
[3] Centralblatt für Medicinischen Wissenschaften, No. 11, March 18, 1871.

A CASE OF CONGENITAL FISSURE OF THE LIDS. By W. W. Seely, M. D., Cincinnati.

Freaks in embryological development are interesting as curiosities, and instructive when studied in connection with the normal growth.

The case I have met with presented abnormalities in both lids, and also in the ball.

Beginning at the outer angle and following the lower lid toward the inner, we found the development perfect for about three-fourths of the length of the normal lid. Then, by a pretty steep angle of declension, the lid terminated with a channel, through which the tears flowed upon the cheek. The remaining fourth of the lid was found as a piece of skin, of an irregular, inverted V-shape, closely attached to the globe, extending to near the sclero-corneal junction.

The upper lid extended, with perfect development, to a point corresponding to the beginning of the defect in the lower. Here there was a slight notch; then the free margin was continued on to the inner angle, but without cilia, or Meibomian glands, so far as I could discover. There were, also, no cilia on the angle of termination in the lower lid, none upon the fold of skin attached to the globe. Nor were there any Meibomian glands in this attached portion, and no cartilage. There was likewise no trace of the inferior canaliculus.

Dr. Wecker has given a description of a case of congenital fissure of the lid (see *Arch. für Ophthal. und Otol.*, vol. i.), and has referred to nine others.

So far as I can discover, the case I have described is peculiar in this, that there was a very large portion of skin attached to the globe. This portion, however, did not fill up the defect

when the lids were closed, for a space was still left between the lid proper and the adherent portion. With the exception of this adhering part, the eyeball was perfect.

I have seen one case of slight notching of the upper lid, occurring in a child affected with single harelip. Also a dermoid tumor about the sclero-corneal junction, without any coloboma of the lids.

The child whose case I have described had a suspicion of defect in the upper lip, and also of the alveolar process. The lip seemed to be thinned in front of each nostril, the fact becoming quite apparent when the child cried and the lip was stretched.

According to Kölliker (*see* "Entwickelungs Geschichte des Menschen und der Höheren Thiere"), we have the sclerotic and cornea appearing in the latter part of the second and first part of the third months. The eyelids begin, as small folds of skin, about the first of the third month; come into contact and unite in the fourth.

It would seem, according to the pointing of some of these cases of defects, that, along with the formation of the lids, there must also take place a histological transformation of the skin covering the eyeball, into two layers of mucous membrane; the one, the palpebral, the other, the ocular conjunctiva.

Continuing our reasoning with this view, we are of course forced to regard these colobomata as simply arrests of histological transformation.

As regards the operative interference, I would simply add that the first step was to free the movements of the ball, which of course were very much restricted by the cuticular attachment. To accomplish this, I dissected the attached portion loose, down to a level with the *cul-de-sac*, and snipped it off. Then, by loosening the conjunctiva a little, and making two incisions along the *cul-de-sac*, on either side, it was readily brought together over the denuded spot and held by two sutures.

Two weeks later, I prepared the parts, denuding them up to the inner angle, also the lid, and, by making an incision horizontal to its free margin, carried it forward and fastened it.

It fitted nicely, and remained three days, when the mother brought the child in, saying she had torn the parts loose. Subsequent attempts failed to keep them together.

CONGENITAL ABSENCE OF BOTH EYEBALLS.

Two Cases. Reported by Dr. George Strawbridge, Philadelphia.

Through the kindness of Dr. George D. Townsend, of Norfolk, Virginia, I have in my possession a specimen, which is curious from the fact of there being complete absence of both eyeballs. The child lived thirty-eight days, and seemed in other respects to be a finely-developed child; its death resulted from an attack of cholera infantum, after a sickness of thirty-six hours. An examination of the specimen shows the lids to be well developed; but, instead of enclosing the eyeball, they end, as it were, in a *cul-de-sac*, which extends inwardly about $\frac{1}{8}''$, and terminates without a trace of the optic nerve being evident at its inner extremity. The lachrymal gland is found to be largely developed, while the bony depression for its reception is perhaps abnormally large. I am not able to find the presence of the puncta lachrymalia, or the canaliculi, although there would seem to have been an effort made toward the formation of a nasal duct.

There is a second case of similar character occurring in a boy living near Philadelphia, who is now seven years of age, and in other respects finely developed.

A third case, occurring in a child now three months old, which I, through the kindness of Dr. Levis, of Philadelphia, had the opportunity of seeing, showed congenital absence of one eyeball, while in other a large coloboma of the iris and choroid was found. The sources of information on this subject, so far as I have been able to obtain them, furnish very little light, either as to the probable cause, or as to the number of such cases on record.

How far maternal impressions may be relied on, as an influencing cause, in the creation of such monstrosities, I leave to other authorities better able than I to decide. In the third case, the mother attributed the misfortune to the fact that, during her fifth month of pregnancy, while engaged in chopping wood, a splinter struck her in the right eye with great force, producing a severe contusion, the effect of which lasted several weeks, and in her child at birth was found an entire absence of right eyeball.

ERRATA.

Transactions for 1870, p. 86, last line, for *image*, read *lens*,

Transactions for 1866, p. 25, tenth line from the bottom, for *the object*, read *this image considered as an object.*

TRANSACTIONS

OF THE

AMERICAN

OPHTHALMOLOGICAL SOCIETY.

NINTH ANNUAL MEETING.

NEWPORT, JULY. 1873.

NEW-YORK:
WILLIAM WOOD & CO., 27 GREAT JONES STREET.
—
1873.

TRANSACTIONS

OF THE

AMERICAN

OPHTHALMOLOGICAL SOCIETY.

NINTH ANNUAL MEETING.

NEWPORT, JULY, 1873.

NEW-YORK:
WILLIAM WOOD & CO., 27 GREAT JONES STREET.

1873.

CONTENTS.

PAGE

Members of the Society 5

Minutes of Ninth Annual Meeting 7

A Case of intra-ocular Glioma, in which the Disease remained latent for twenty Months after Perforation of the Cornea. By O. F. WADSWORTH, M.D., Boston 11

White sarcomatous intra-ocular Tumor. Enucleation. By B. JOY JEFFRIES, M.D., Boston 24

Intra-ocular Tumor. White fusiformed-cell Sarcoma. Enucleation. By B. JOY JEFFRIES, M.D., Boston 26

Cancerous Ulceration of the Surface of the Globe. By Dr. HENRY D. NOYES, New-York 28

Demonstration of pathological Specimens. By H. KNAPP, M.D., New-York 31

Sclerotitis depending on gouty or rheumatic Diathesis. By HENRY D. NOYES, M.D., New-York 34

A Case of Wound of the Sclera treated by Suture, with Remarks. By THOMAS R. POOLEY, M.D., New-York 43

Report of One Hundred and Fourteen Extractions of Cataract. By H. KNAPP, M.D., New-York 50

Report of Twenty-five Cases of median Flap Extraction. By HENRY W. WILLIAMS, M.D., Boston 55

On the Importance of an accurate Record of all Operations for Cataract and the Results of the same, with some practical Suggestions. By HASKET DERBY, M.D., Boston 58

Remarks on Cataract Extraction—Suggestions for securing greater Precision in reporting Operations and Results—Form of the corneal Section. By JOHN GREEN, M.D., St. Louis 65

Liebreich's Extraction of Cataract.—Dislocation of Lens, and Failure to Escape.—Reopening of Wound nine Days after. —Extraction of Lens.—Good Result. By D. B. ST. JOHN ROOSA, M.D. 69

PAGE

Herpes Zoster Ophthalmicus of the left Side, causing loss of the corresponding Eye, and subsequent loss of the opposite Eye. By H. D. NOYES, M.D., New-York 71

Two Cases of Herpes Zoster Ophthalmicus destroying the Eye. By B. JOY JEFFRIES, M.D., Boston 73

Traumatic Rupture of the Choroid, without direct Injury of the Eye. By B. JOY JEFFRIES, M.D., Boston 79

The Camera Lucida applied to the Ophthalmoscope. By HENRY D. NOYES, M.D. 80

An Instrument for the Diagnosis of Refraction. By Dr. W. THOMSON 83

An Instrument for Tattooing the Cornea. By Dr. WILLIAM THOMSON 86

The Light-streak in the Centre of retinal Vessels. By EDWARD G. LORING, M.D. 87

A Case of sparkling Bodies in the Retina. By GEORGE T. STEVENS, M.D., Albany 105

Demonstration of some new Instruments. By H. KNAPP, M.D., New-York 107

MEMBERS

OF THE

American Ophthalmological Society.

ACTIVE MEMBERS.

Dr. C. R. Agnew	New-York,	New-York.
Dr. Charles M. Allin	"	"
Dr. H. Althof	"	"
Dr. Joseph Aub	Cincinnati,	Ohio.
Dr. Charles S. Bull	St. Louis,	Missouri.
Dr. F. J. Bumstead	New-York,	New-York.
Dr. W. F. Carmalt	"	"
Dr. Edward Curtis	"	"
Dr. Edward M. Curtis	Sacramento,	California.
Dr. Edward Delafield	New-York,	New-York.
Dr. Francis Delafield	"	"
Dr. Hasket Derby	Boston,	Massachusetts.
Dr. R. H. Derby	New-York,	New-York.
Dr. John H. Dix	Boston,	Massachusetts.
Dr. Abram Du Bois	New-York,	New-York.
Dr. E. Dyer	Pittsburg,	Pennsylvania.
Dr. Henry C. Eno	New-York,	New-York.
Dr. John Green	St. Louis,	Missouri.
Dr. A. D. Hall	Philadelphia,	Pennsylvania.
Dr. George C. Harlan	"	"
Dr. Gustavus Hay	Boston,	Massachusetts.
Dr. Edward L. Holmes	Chicago,	Illinois.
Dr. Edwin Hutchinson	Utica,	New-York.
Dr. B. Joy Jeffries	Boston,	Massachusetts.
Dr. Samuel J. Jones	Chicago,	Illinois.
Dr. Charles J. Kipp	Newark,	New-Jersey.

Dr. H. Knapp	New-York,	New-York.
Dr. Edward G. Loring	"	"
Dr. Arthur Matthewson	Brooklyn,	"
Dr. R. J. McKay	New-York,	"
Dr. H. G. Miller	Providence,	Rhode Island.
Dr. T. G. Morton	Philadelphia,	Pennsylvania.
Dr. Russell Murdoch	Baltimore,	Maryland.
Dr. Homer G. Newton	Brooklyn,	New-York.
Dr. William F. Norris	Philadelphia,	Pennsylvania.
Dr. Henry D. Noyes	New-York,	New-York.
Dr. J. F. Noyes	Detroit,	Michigan.
Dr. Charles J. Pardee	New-York,	New-York.
Dr. O. D. Pomeroy	"	"
Dr. Thomas R. Pooley	"	"
Dr. J. S. Prout	Brooklyn,	"
Dr. Charles E. Rider	Rochester,	"
Dr. C. A. Robertson	Albany,	"
Dr. D. B. St. John Roosa	New-York,	"
Dr. W. W. Seely	Cincinnati,	Ohio.
Dr. Henry L. Shaw	Boston,	Massachusetts.
Dr. Francis Simrock	New-York,	New-York.
Dr. George T. Stevens	Albany,	"
Dr. Francis P. Sprague	Boston,	Massachusetts.
Dr. George Strawbridge	Philadelphia,	Pennsylvania.
Dr. William F. Thomson	"	"
Dr. J. J. Vermyne	New-Bedford,	Massachusetts.
Dr. O. F. Wadsworth	Boston,	"
Dr. David Webster	New-York,	New-York.
Dr. Robert Willard	Boston,	Massachusetts.
Dr. E. Williams	Cincinnati,	Ohio.
Dr. Henry W. Williams	Boston,	Massachusetts.

Total.....57.

HONORARY MEMBERS.

Dr. G. A. Bethune	Boston,	Massachusetts.
Dr. Isaac Hays	Philadelphia,	Pennsylvania.
Dr. R. Hooper	Boston,	Massachusetts.
Dr. John Jeffries	"	"
Dr. E. Reynolds	"	"
Dr. C. Schweigger	Berlin,	Prussia.
Dr. George Wilkes	New-York,	New-York.

Total..... 7.

Whole Number.....64.

AMERICAN

Ophthalmological Society.

NEWPORT, *July* 17, 1873.

The Society met at the rooms of the Newport Exchange, 197 Thames Street, at 11 A.M.

The President, with a few introductory remarks, took the chair, and made allusion to the omission of the meeting in 1872, which was given up that the members might attend the session of the International Ophthalmological Congress in London, and alluded also to the fact that the next regular meeting of the Congress would occur in New-York in 1876.—Present:

The President, Dr. HENRY W. WILLIAMS,	Boston.
Dr. C. R. AGNEW, Vice-President, .	New-York.
" ALTHOF, ...	"
" KNAPP, ...	"
" LORING, ...	"
" NOYES, ...	"
" POMEROY, ...	"
" DERBY, ...	Boston.
" HAY, ...	"
" WADSWORTH, ...	"
" DYER, ...	Philadelphia.
" THOMSON, ...	"
" STRAWBRIDGE, ...	"

Dr. Miller, ...	Providence.
" Rider, ...	Rochester, N. Y.
" Green, ...	St. Louis.
" Roosa, ...	New-York.
" John Jeffries, Honorary Member,	Boston.

The President appointed a committee whose duties should be to receive applications for membership, to nominate officers for next year, and to choose the next place of meeting, namely, Drs. Roosa, Althof, Hay, Thomson, and Green.

Also a committee to prepare a bulletin, namely, Drs. Wadsworth and Rider.

The resignation of Dr. J. H. Hinton, of New-York, was received and accepted; also the resignation of Dr. A. D. Williams was confirmed.

The Treasurer read his report, which was referred to Dr. Dyer to be audited, and afterward reported to be correct and to be properly vouched for. The report was thereupon accepted and ordered on file.

The Nominating Committee recommended the following persons for membership:

Dr. R. J. McKay, . . .	New-York.
" David Webster, . .	"
" Charles J. Kipp, . . .	Newark.
" Charles J. Pardee, . .	New-York.
" George C. Harlan, . .	Philadelphia.

They were all duly balloted for and declared elected.

The Business Committee presented a bulletin of papers, of which eight were read; and at 2 P.M. the society adjourned to reassemble at 8 P.M.

At the evening session, the minutes of the morning were read and approved.

The bulletin was taken up, and upon the reading of the sixteenth paper, by Dr. H. Derby, "on the Importance of a Record of all Operations for Extraction of Cataract, with some practical Suggestions," its subject matter was referred to a committee, consisting of Drs. Williams, Derby, Agnew, Knapp, and Noyes, to take action as they should deem fit, and report to the next session of the society.

The Nominating Committee reported the names of

Dr. George T. Stevens, . Albany,
" J. J. B. Vermyne, . . New-Bedford, Mass.,

who were duly balloted for and elected.

Dr. Althof made a communication on the proposed monument to be erected in Berlin to the late Professor Von Graefe. A subscription was taken up and handed to the President for transmission to the Berlin Committee.

After reading three more papers, and having referred all papers presented, to the Business Committee, the Society at 10 P.M. adjourned.

July 18, 1873.

Society met at 10.30 A.M. The minutes of the previous meeting read and approved.

The Nominating Committee then reported the following persons for officers for the ensuing year:

President, Dr. C. R. Agnew, of New-York.
Vice-President, Dr. G. Hay, of Boston.
Recording Secretary, Dr. Henry D. Noyes, of New-York.
Corresponding Secretary, Dr. H. Althof, of New-York.
All of whom were on ballot elected.

They also recommended not to appoint a Committee on the Progress of Ophthalmology; that the place of meeting next year be Newport, on the third Thursday of July, as fixed by the By-Laws, at 10 A.M. These recommendations were adopted.

It was resolved that the Publishing Committee be composed of Drs. Roosa, Loring, and the Recording Secretary; and that the assessment for the next year be $10; and that papers intended for publication must be put into the hands of the committee by September 1st.

The President elect made some remarks in accepting the office, and by the courtesy of the retiring President Dr. Williams, the Vice-President elect, Dr. Hay, then took the chair.

The Committee upon Tabulating the Records of Cataract Extractions reported that they had agreed upon a form, which was read and accepted, and they were authorized to have them printed and prepared for sale.

The bulletin was then resumed until it was completed, and all papers were referred to the Publishing Committee.

The choice of the rooms to be occupied by the Society at the next meeting was left for the Secretary to decide between the Newport Exchange and the Acquidneck House.

Minutes read and approved, and at 1 P.M. the Society adjourned.

HENRY D. NOYES, M.D.,
Recording Secretary.

As a supplement to the minutes, and giving official account of the American movement in aid of the Graefe monument, the following letter is inserted:

(Copy.)

15 ARLINGTON STREET, BOSTON, U. S. A.,
September 19, 1873.

Comité für das Gräfe-Denkmal, Berlin:

GENTLEMEN: The friends of the late Professor Von Gräfe having done me the honor of making me the American member of the Committee appointed to obtain a subscription for a statue to be erected to his memory at Berlin, I asked the assistance of several gentlemen residing in other American cities, and of the American Ophthalmological Society.

As the result of our efforts I have the pleasure of inclosing a draft on the Hamburg-Berliner Bank for two thousand two hundred and fifty Reichs-Marks, (about six hundred and twenty dollars.)

A list of the names of all who have subscribed is also inclosed; but we do not affix the amounts paid by each; as we wish that those who have given larger or smaller sums may have equal honor, as having contributed according to their ability.

Please to receive the assurance of my highest consideration.

HENRY W. WILLIAMS, M.D.

A CASE OF INTRA-OCULAR GLIOMA, IN WHICH THE DISEASE REMAINED LATENT FOR TWENTY MONTHS AFTER PERFORATION OF THE CORNEA. By O. F. Wadsworth, M.D., Boston.

T. F., 2 years and 11 months old, was brought to me at the City Hospital, August 2d, 1871. His mother stated that the left eye had been lost by inflammation some months previously, but had since remained quiet till ten days before. Then it began to be reddened, painful, and prominent, and the child had since refused food, slept little, and was rapidly losing flesh and strength. The lids were now swollen and reddened, the conjunctiva congested and somewhat chemosed, the bulb prominent. The cornea was small and completely leucomatous. The resistance felt on pressure seemed perhaps a little more tense than is usually the case in panophthalmitis, and the congestion and chemosis of the conjunctiva rather less than was to be expected if the quite considerable prominence of the globe were due to that affection; still the rapidity with which the symptoms had appeared, and the severity of the constitutional disturbance, served to make the diagnosis of panophthalmitis the most probable one.

With the object of diminishing tension and relieving pain, an incision with a Beer's knife was made across the cornea in the horizontal meridian, the wound being about ½″ long, and ⅓′ deep in the centre. The feel on cutting was that of a solid body, and nothing escaped from the wound. The probability of the presence of a tumor was at once evident, and the mother was advised that the eye should in such case be removed. For the next two days, she was to apply warm fomentations.

It may be as well to give here the more exact previous history of the case which was afterward obtained from the mother. The boy had been generally healthy. When he was six months old, the mother noticed a "speck on the sight of the left eye the size of a pin's head." No preceding inflammation had been observed. This "speck" remained about the same till he was fourteen months old; then the eye inflamed. He was then in a country town in New-York, and by the advice of a physician, alum curd and white of egg was applied for some four weeks. There was great swelling and much discharge, which gradually diminished. Not long after, he was brought home to Boston, and the eye, except for slight passing attacks of inflammation, remained quiet until ten days before I saw him. Confirmatory of this account is the fact that, on October 17th, 1870, he was seen by an oculist of this city, who diagnosed "atrophy of the globe," and again, November 30th, 1870, by another oculist, who found "chemosis of the conjunctiva of the left eye, the cornea barely visible and hazy." The chemosis was incised and a borax lotion ordered.

Two days after the first visit, the swelling and redness of lids and congestion of conjunctiva were much less; the globe was, however, quite as prominent and offered as much resistance to pressure, but it followed slightly the movements of the other eye. There had been no discharge from the wound. The pain, etc., continued.

Immediate removal was advised and acceded to. The patient was etherized, and conjunctiva and recti tendons divided as for enucleation; but before cutting the nerve, the finger was passed backward between Tenon's capsule and globe, and a tumor, posterior to the eye and attached to it, was felt. The tissues were then divided from the outer canthus to the edge of the orbit, and the whole mass of the tumor, so far as it could be made out, removed entire, the finger serving as a guide for curved scissors. The extra-ocular portion of the tumor was attached to the posterior third of the bulb, and seemed nearly as large as the bulb itself. It was enveloped in fatty tissue, and portions of the muscles were removed with it. The nerve was divided about $\frac{3}{4}''$ behind the globe; its cut surface was rather whitish, fatty looking, about normal size.

On examination of the orbit with the finger, a flattened oval nodule was felt under the outer portion of the roof, apparently encapsuled. This was supposed to be the lachrymal gland, and was not removed. Nowhere else in the orbit was any nodule to be felt, and the tissues appeared to the touch normal. The bleeding was not excessive and was readily controlled by ice. A sponge compress was applied over the lids.

The boy had a good night, and the next morning was sitting up in bed enjoying a picture-book, and quite free from pain. In the afternoon he was taken home. The parents were warned of the likelihood of a recurrence of the tumor, and asked to inform me if any symptoms appeared. The wound healed readily, and for eight or nine days following the operation, the child seemed quite well and had a good appetite. Then he began to complain of headache, had anorexia, nausea, and vomiting. August 16th, two weeks after the operation, he was brought again to the hospital. There was no swelling of the lids, the wound was healed, the orbit seemed rather full. The headache, etc., persisted.

On August 28th, the father brought him to my office in the evening. The three days previous, his appetite had been fair, and he had vomited but once, but he had seemed dull for several days, and especially on that day, and had kept his hand to his head much of the time, though not complaining of pain. The father had noticed also that the sight of the right eye seemed growing dim, and that there was some prominence of the left lids. The left eyelids were slightly pushed forward and the orbit was filled with an elastic mass. The conjunctival surface was unbroken. The right pupil was dilated, as in paralysis of the sphincter, and reacted very little to light. The child was a little uneasy and frightened, and ophthalmoscopic examination was difficult. A few glances at different parts of the fundus were, however, obtained, but revealed nothing abnormal. Going out of the room and through the front door, holding his father's hand, he walked rather hesitatingly, and put out his other hand, as if groping to assist his vision.

The next ten days he had more or less vomiting, his appetite was poor, and he took little but milk. During the first part of this time he moved about the room only by groping ;

later, lay still most of the time and rarely spoke unless spoken to. When he did speak, he appeared sensible. He became peevish, complained two or three times of dizziness, and had a few slight "spasms," "stiffening himself out," sometimes after such an attack complaining of pain in his head for a few moments; at night he was restless.

By September 7th, the eyelids were pushed forward by the tumor of the orbit so as to reach a little beyond the level of the brow, and formed a rounded projection below it about the size and shape of the larger end of a hen's egg; the superficial veins in the upper lid enlarged. The right pupil was large and immovable, and vision wanting entirely.

The tumor increased in size, the lids became more distended, and fleshy granulations appeared between them, bleeding at rare intervals, but never to large amount. He ate scarcely any thing, but drank a variable amount of milk, and some days he was free from vomiting. September 16th, there was a small movable swelling over the posterior edge of the ramus of left lower jaw, a little above the angle. He had had no dejection for several days, and, his mother thought, did not pass his urine. The descending colon was found filled with hard rounded masses, and the bladder distended almost to the umbilicus, but there was no tenderness on pressure and no complaint of pain. A hot bath followed by hot fomentations relieved the bladder, and he afterward passed his urine pretty well, but only when he was held up; otherwise, he would go the whole day without micturition. Enemata were ordered, but only one was given, which had no effect, and as he complained of its paining him, his mother did not repeat it. For two weeks longer the constipation continued, and the whole colon became filled with hard masses; then spontaneous daily dejections took place for a while and the distention of colon much diminished. Toward the end of September he seemed rather brighter and stronger, occasionally asked to be taken up and sung to, and often hummed to himself while lying on the lounge. Rarely he complained of pain in the brow over the tumor. He answered clearly when spoken to, but was peevish and unwilling to be touched, and sometimes cried out at night as if in pain, though generally sleeping pretty well.

By the 7th of October, he had become more listless and did not mind touching and washing as before; but he was still sensible when he spoke, and strong enough to sit up in his father's lap. The vomiting had increased, with some retching, appetite failed more, and he was much emaciated. He was more restless at night, now singing, then crying out with pain, and had occasional slight convulsive movements of the limbs. At this time, the tumor of the orbit formed a rounded projection some 2″ in diameter, its summit projecting $1\frac{1}{4}''$ beyond the brow, over which the lids were stretched and elongated, their free edges $\frac{1}{2}''$ longer than natural, and separated some $\frac{3}{4}''$ in the centre; the space between them closed by a dark-red granulating surface, from which there was very little secretion. The enlarged gland over the ramus of the left jaw had attained the size of a filbert, and there was another swelling over the coronal suture on the right side, rather nearer the zygoma than the vertex, $\frac{3}{4}''$ in diameter and $\frac{1}{3}''$ high. The right pupil had within two or three days returned to the normal size, and now reacted well to light, and the boy said he could see again; but on testing him with a lamp, there was apparently no perception of light.

The next few days he gradually failed, and died on the morning of October 12th. No autopsy could be obtained.

The tumor was placed for some three weeks in Müller's fluid, and afterward in dilute alcohol. A horizontal section was made through the wound in the cornea and passing through the optic nerve. The globe was nearly of normal size, very little flattened from before backward, but at the same time presenting some projection of the most anterior portion. It was completely filled by a dense, faintly yellowish-gray mass, varying in shade in different parts, through which ran branching and anastomosing lines of dark brown, orange-yellow, and bluish gray, the latter resembling somewhat in color the cut surface of nerve-sheath and sclera; while in the posterior portion, to the temporal side of the insertion of the nerve and near the sclera, were several irregular, ill-defined, darkish-brown patches. The cornea was of nearly normal thickness. The sclera was everywhere thinned, but this was especially the case around the entrance of the nerve, where it

was pushed backward so as to form a sort of irregular staphyloma, in the midst of which the nerve projected somewhat into the cavity of the globe. Here the scleral tissue was extremely thin, and appeared frayed on the outer surface, sending short outshoots into the mass of the extra-bulbar growth. Except in the posterior portion of the globe, a narrow, irregular, light-brownish line separated the sclera from the mass within, and from this, brownish lines extended here and there into the mass to join the other lines running through it. The portion of nerve removed was 8''' in length. The outer nerve-sheath was thinned, the nerve itself a little larger than normal; nerve and sheath were closely united, and no trace of the interval between inner and outer sheath to be seen. The space within the sheath, through the whole length, was filled with a dense mass, resembling in color and appearance that filling the bulb. Nearly everywhere a brown streak, of varying width, ran along the inner surface of the sheath, and a few brown dots or faint short streaks appeared in the midst of the mass which filled it. To the temporal side of the nerve, about 1''' removed from its outer edge, was a bluntly conical mass, resembling that filling the bulb and nerve-sheath, running outward and backward, its base 3''' in width, its height about 3½.''' The base of this mass rested against and was united with the thinned sclera, its sides appeared bounded by a thin layer of fibrous tissue; at its edges and within its substance were irregular, ill-defined brown spots.

The remaining extra-bulbar portion of the tumor presented a sharply defined contrast to that which has been described. It inclosed the posterior third of the globe and the conical mass mentioned; its greatest width was nearly on a level with the insertion of the nerve in the sclera, where it was 2''' or 3''' wider than the globe at the equator, and it extended backward nearly to the divided end of the nerve. Its cut surface was generally of a faint greenish-gray color, variegated by curving streaks of a yellowish gray and faint lines of fibrous tissue, which gave it a somewhat lobulated appearance. The boundary between it and the fatty tissue surrounding it was irregular; in some parts pretty distinctly defined, in others not; and here and there short, pointed outshoots into the fatty

tissue appeared. Outwardly and anteriorly, a portion of the external rectus muscle lay along its edge, separated from it by a layer of fibrous tissue. The portion of this muscle which had been removed was divided longitudinally by the section made, and showed to the naked eye nothing abnormal.

Microscopic examination of the extra-ocular tumor showed that it was mainly made up of a closely aggregated mass of small cells, not much larger than white blood-corpuscles, with little intercellular substance. The cells were generally round, often with slightly irregular contour, occasionally with one or two short fibres projecting from the periphery, while some had the form of short spindles. In most of them, a faintly granular round nucleus appeared, nearly filling the cell, and surrounded only by a narrow zone of pale protoplasm; in others, no protoplasm surrounding the nucleus could be made out. Some of the spindle-cells were pointed only at one end, the other rounded and entirely filled by the nucleus; others pointed at both ends with the nucleus in the centre filling the whole breadth; in these cells, the protoplasm of the extremities was pale and faintly granular. The intercellular substance was finely granular, often having the appearance of a pale network of granular fibres, and easily broken.

Numerous capillary vessels, and many of much larger size with thick adventitia, and scattered curving bands of pale fibrous tissue, more or less infiltrated with small cells, ran through the growth. Small portions of the tissue in the more yellowish-colored streaks were degenerated, showing shrunken cells, free nuclei, granular matter, and diffused hemorrhages. Toward the borders of the growth, traces of fatty tissue could be seen, the fat-cells surrounded, separated, and compressed by the small cells of the tumor, and, proceeding farther outward, the gradual infiltration of small cells between the fat-cells could be clearly followed.

The fibres of the external rectus muscle seemed unchanged; the transverse striation and the nuclei of the sheaths were plainly visible. Between the bundles of fibres, however, the growth had penetrated, presenting in the sections small round or oval groups of cells, or narrow bands two or three cells in width, surrounded by connective tissue, and recalling strongly

some of the appearances seen in the small cell variety of epithelioma. The individual fibres of the bundles were, for the most part at least, not separated by the disease, but scattered cells appeared here and there between them.

Sections of the optic nerve showed, under a low power, traces of the normal arrangement of the connective tissue bands surrounding the nerve-bundles. Higher powers showed that this tissue was pale, degenerated, infiltrated with granular matter and *débris* of small cells, but still contained traces of blood-vessels. The spaces between these bands, normally occupied by the nerve-fibres, presented little but granular matter and *débris* of cells and fibres. The central vessels of the nerve could generally be traced, though their walls were everywhere much degenerated: portions of them contained blood-corpuscles, and often were surrounded by hemorrhages; others contained a partly granular, partly amorphous mass, and still others were filled with a homogeneous substance, strongly refracting light and readily absorbing coloring matter. Neither the inner sheath of the nerve nor the characteristic tissue in the space between the sheaths could be anywhere made out. The brownish line which macroscopically lined the inner surface of the outer sheath was made up of irregularly dilated blood-vessels and hemorrhages, with here and there a few scattered dots or clumps of orange-yellow hæmatine. The inner layers of the outer sheath were separated from each other by rows and groups of small cells, and a few well-formed cells were scattered in the hemorrhagic district and edges of the nerve. The outermost layers of the sheath were pushed apart by the growth external to it in the same way; its central portion was little changed, but here and there a few small rounded or spindle-shaped cells were evident, and along some of its blood-vessels similar cells were found in rows. Beside these cells, resembling in every respect those of the tumor, other cells lay here and there in the tissue of the sheath or along the side of the separated fibres. These latter were three or four times as long as the glioma cells, narrow and pointed, and contained a pale, elongated oval nucleus, in which one, two, or more nucleoli could be seen.

The intra-ocular mass and that forming the conical projec-

tion outward and backward were made up mainly of granular matter, and more or less degenerated small cells. The conical projection showed a pretty uniform degree of degeneration throughout, though much less in amount than existed in many parts within the globe. It contained some hemorrhages, but consisted mostly of irregular masses of partially shrunken cells grouped about small blood-vessels, interspersed in nearly equal amount with districts of granular *débris*.

Through the intra-ocular mass irregular bands of pale fibrous tissue passed. Some of these bands ran forward from the entrance of the nerve, and probably were formed of the altered connective tissue of the separated retina and the vessels which had supplied the growth; others, more anteriorly situated, may have arisen from alteration and displacement of the iris and ciliary body, or from fibrous changes of the vitreous. Blood-vessels, some still containing well-formed corpuscles, were frequently seen. The amount of the degeneration varied very considerably in different parts. Toward the inner (nasal) side of the globe, numerous groups of tolerably well-formed cells, mingled with some *débris*, were clustered around a central vessel, and entirely surrounded by greatly altered elements. Many parts contained fat-granules; and in the most degenerated district, rather anterior to the centre of the globe, were very numerous fat-globules of large size. The colored portions were made up of hemorrhages and dots and clumps of orange-yellow hæmatine, and, in the more anterior parts, of granules and masses of dark-brown pigment, a portion of the latter contained in round or oval cells two or three times the diameter of the cells of the growth. The brown pigment and most of the yellow was situated in the fibrous-tissue bands, as were also many of the blood-vessels. Anterior to the equator of the globe, quite near the sclera, and especially at the inner (nasal) side, where the degeneration was less complete, a number of round or oval cells, two or three times the diameter of the glioma-cells, and containing fat-granules and a nearly circular nucleus, were found. Besides these, there were a few large, pale cells, with generally one or two, rarely three long processes, the nucleus large and elongated, strongly resembling the branching cells of the choroid. Both these varieties of

cells must without doubt be regarded as remaining choroidal cells; the large proportion of round and oval cells and the want of pigment in them is readily explained by the early age of the patient, since at birth the choroid proper contains no pigment and no branching cells. The dark-brown pigment referred to above was probably derived from the uvea.

The innermost layers of the sclera were everywhere pushed apart by an infiltration of small cells, and in many places rows of cells were found in most of the spaces between the layers through its whole thickness; in the ciliary region, the cell-growth surrounded the perforating vessels, and occasionally in great part displaced the scleral tissue. The layers of the cornea were more fibrillar and less transparent than normal, interlaced more, and often ran at a considerable angle with its surface. They were nearly everywhere separated by rows and groups of small cells, and in some parts red blood-corpuscles were scattered in the interstices of the posterior layers. The more peripheral parts of the cornea contained many blood-vessels, often of large calibre, and situated at various depths below its surface. In the cornea, as also in the sclera, were here and there isolated, elongated, pointed cells, with long nucleus and one to three or four nucleoli, like those described in the nerve-sheath; the normal scleral and corneal corpuscles. The membrane of Descemet was almost universally detached from the cornea, and lay in wavy folds, the space between it and the cornea filled with a growth of often perfectly formed cells, while on the posterior side of it the cells were much degenerated. The corneal epithelium was wanting except toward the sclero-corneal border; there it was generally thicker than the normal; most of the cells appeared spinous. No trace of the lens was seen.

There are some features of the case just reported which are of sufficient interest to call for special remark. A consideration of the clinical history and the condition of the contents of the globe revealed by microscopic examination, in connection with the facts already known as to the development and course of intra-ocular glioma, can scarcely leave a doubt that the inflammation which occurred when the child was fourteen months old was excited by a previously existing intra-ocular

tumor, and that the growth did not arise secondarily after the eye had been lost. It has indeed been shown in rare instances, (Graefe,[1] Lawson,[2]) that a sarcomatous tumor has originated in an eye after it has been lost by injury, and certainly the possibility of origin of either glioma or sarcoma in an eye the seat of former destructive disease must be granted. No authentic case of the sort has, however, thus far been observed. On the other hand, it is not very infrequent that an intra-ocular tumor (either sarcoma or glioma) causes an inflammation of the globe which, with or without perforation of the cornea, is followed by a period of atrophy before the growth becomes extra-ocular. That perforation of the cornea had taken place in this case is probable from the absence of any trace of the lens. Knapp[3] has reported a case in which the sequence of inflammation, perforation, closure, and shrinking occurred a second time after an interval of three months, the glioma finally becoming extra-ocular some nine months after it was first observed. Hirschberg[4] quotes five cases (inclusive of Knapp's) in which temporary atrophy occurred; and v. Graefe[5] even described the symptoms which should distinguish an atrophy due to an intra-ocular tumor from one excited by other causes. Whether the symptoms which v. Graefe considered characteristic were present in the case under discussion, the history is not sufficiently complete to decide. The total disappearance of all elements of the normal intra-ocular tissues, (if we except the few remaining cells of the choroid seen in the least degenerated part,) and the advanced degree of degeneration, shown by the abundance of hæmatine and large fat-globules, is evidence that the growth within the globe must have been of considerable age. Finally, the clinical history, while entirely compatible with the theory of previously existing tumor, offers no other explanation as to the cause of the original inflammation. The "speck on the sight," noticed by the mother when the child was six months old, I am inclined to regard as an opacity of the cornea due to ulceration, and as having no connection with the tumor.

[1] Archiv für Ophthalmologie, xiv. 2. [2] Ophthal. Hosp. Reports, vii. 3.
[3] Die Intraoculären Geschwülste. [4] Markschwamm der Netzhaut.
[5] Archiv für Ophthalmologie, xiv. 2.

The length of time the period of atrophy of the globe and latency of the disease continued is nearly double that in any hitherto published case. The longest period of atrophy I have been able to find recorded, viz., ten months, was in a case reported by Hayes and quoted by Wardrop;[1] there the cornea was not perforated. In the case above related, twenty months elapsed from the date of perforation before the eye began visibly to protrude. In this respect, then, the case may be considered not without importance as a contribution to the literature of intra-ocular glioma.

Another point of interest concerns the conical mass attached to the posterior part of the globe. It seemed at first, from the position of this mass, its sharply defined outline, and the marked degree of degeneration which existed throughout it, as if the growth of the tumor had ceased for a while after it had passed through the sclera and invaded the orbital tissues. That the growth should temporarily cease after involving so vascular a tissue as is there present, was certainly remarkable. Examination showed, however, that the sides of the cone were entirely surrounded and inclosed by a dense layer of fibrous tissue, and that this layer was in intimate union with the sclera at the base of the cone. From the base of the cone forward, for a distance of 1''' to 3''', Tenon's capsule was also found intimately united with the sclera. It is probable, therefore, that here a development of the glioma had occurred between the sclera and Tenon's capsule; that firm, inflammatory adhesions between capsule and sclera had prevented its spreading laterally, and it had enlarged in a backward direction, bulging the capsule before it. The resistance offered to its progress by the firm capsule served to render its increase slow, and gave time for the degeneration to take place.

There is one other peculiarity of the case worthy of note: the behavior of the iris of the right eye. About three weeks after removal of the left eye, the pupil of the right became large, as in paralysis of the sphincter, and remained in this condition for some five weeks, responding scarcely or not at all to light, vision being at the same time wanting. The movements of extra-ocular muscles supplied by the third pair were

[1] Fungus Hæmatodes, p. 55.

apparently unaffected. Then, while the boy's general condition grew worse, and vision did not return, the pupil for some days before his death returned to its normal size and reacted to the stimulus of light. Progression of the disease along the left optic nerve to the chiasma readily explains the loss of sight; but the return of reflex action in the iris after it had been so long wanting, and while the disease must have been continually progressing, seems wholly inexplicable. Possibly an autopsy might have thrown some light on the mechanism of this phenomenon.

WHITE SARCOMATOUS INTRA-OCULAR TUMOR. ENUCLEATION. By B. Joy Jeffries, M.D., Boston, Mass.

February 5th, 1873, a woman, aged 40, applied to me, having V.O.D.=$\frac{20}{30}$, V.O.S. Jäger No. 16, with some portions of the field. At twenty feet can see my arm or hand moving over some parts of the retina. The visual field was taken on the register. Ophthalmoscopic examination shows a pinkish nerve and clear media. From close against the nerve, up and in, is a growth pushing forward, the retinal vessels running smoothly over it. The end against the nerve is oval. The whole, as seen, seems the size of a small almond. It has a whitish-gray color. Only within a week, the patient says she has noticed her *present* loss of sight; but, upon close questioning, her vision in this left eye has failed for some months back. There is no pain in the eye, but, as she expresses it, a sensation of "heaviness" and "fatigue." The patient did not exhibit any other sign of morbid growth. The tumor was decided to be most probably sarcoma, and an enucleation strongly advised. This was finally consented to and done under ether, February 19th, 1873. To satisfy the friends of the existence of a tumor, the globe was necessarily opened at once. The vitreous was of normal consistency, but had a yellowish tinge. The retina became readily detached from over the tumor, with retinal pigment adhering to it. The tumor was of the size above mentioned. The specimen was put in Müller's fluid till March 13th, 1873, when it was again carefully examined, and all the internal structures found good. The growth was not wholly attached to the sclerotic. The line of demarkation was also perfectly distinct. It belonged to and occupied

the place of the choroid, reaching as far as this encircles the optic-nerve entrance. The nerve, on section, seemed healthy. The tumor may have *pressed* the nerve, but it did not involve it. The tumor was something over half an inch in length, reaching farther forward than the ophthalmoscope showed. Its thickness was about one third of its length. Section of the tumor showed it to be non-vascular, yellowish white, homogeneous, pretty firm, distinct from the sclerotic, occupying the space and place of the choroid, up to but not involving the nerve. A layer of retina with pigment, or a layer of choroidal pigment, peeled off the surface of the tumor. Under the microscope it was found to be spindle-cell, and round, and ovoid white sarcoma. The cells as broad and three times the length of a blood-corpuscle. There was no pigment. For quite similar case, *vide* Knapp, "Intra-ocular Tumors," Tab. XIII., Fig. 58.

INTRA-OCULAR TUMOR. WHITE FUSIFORMED-CELL SARCOMA. ENUCLEATION. By B. Joy Jeffries, M.D., Boston, Mass.

A man, aged 60, came to me April 1st, 1873, complaining of pain over left side of head and in the left eye. Vision was reduced to the perception of light eccentrically. The pupil was dilated with atropine, and with the ophthalmoscope the fundus was blurry, the nerve dimly seen. A tumor was noticed on the inner side, in the ciliary region, just reaching into the dilated pupil. It reached backward beyond the middle of the globe, and the retinal vessels were seen running over it. It was thought to be sarcomatous, and enucleation advised and performed under ether, April 3d, 1873. The globe was at once opened and the tumor found as above. The preparation placed in Müller's fluid.

The man looked in fair health and had been a hard worker. He however complained of some head symptoms, such as "uneasiness" in head and ear. This last Dr. H. L. Shaw examined and reported "slight chronic difficulty." These very slight cerebral symptoms were not thought to militate against good hopes from immediate enucleation. April 11th, 1873, the patient for the first time complained of some pain just in front of left ear, or rather tenderness on pressure. A small gland here was slightly swollen. The lids had puffed more than usual after enucleation, giving a thought of impending erysipelas. All these symptoms, however, passed off within a few days.

June 24th, 1873, the specimen was taken from the preserving fluid, and a section made through the centre of the tumor horizontally, and through iris, lens, and cornea, all in natural

position. The substance of the tumor was firm, homogeneous, whitish, and no pigment was seen. It was attached to the sclerotic, about the size of a small filbert, reaching forward to the insertion of the iris, and backward beyond the median line. It touched the back of the lens, pressing forward the ciliary muscle and processes. The sclerotic lying against it was perfect. It occupied the place of the choroid, pushing the retina inward on its surface. The rest of the globe and optic nerve seemed perfectly normal. The microscope showed it to be a fusiformed-cell white sarcoma, such as Knapp gives in Tab. XII., Figs. 50–53, in his monograph on intra-ocular tumors.

CANCEROUS ULCERATION OF THE SURFACE OF THE GLOBE. By Dr. Henry D. Noyes, New-York.

Miss A. B., æt. 16, living in Western Massachusetts, was brought to me by her family physician, Dr. Collins, in April, 1872. She was of delicate appearance, thin, complexion pale and sallow, strength feeble, appetite poor, no cough, and had been losing health for many months.

About fifteen months ago, a small red spot appeared on the right eyeball, just below the cornea. It was painless and was not attended with secretion or photophobia. It resisted simple measures of treatment, and by and by developed into a "pimple." Three times this elevated tissue has "broken' and given vent to discharge, but never has it caused pain or general inflammation of the eye. The patient lived several miles from a physician and seldom called for his services. No important treatment has ever been adopted.

The appearances which I find are as follows: When the lids are separated by the fingers and the globe directed upward and outward, an irregular and deep ulcer occupies the inner and lower part of the sclera and cornea, nearly to its middle. Its outline is ellipsoidal. Its extreme horizontal length is about one inch, and its vertical breadth about half an inch. Its edges are elevated and somewhat papilliform. A thin fluid oozes from it. The surface consists of bosselated, warty masses, with intersecting fissures and depressions, the little masses being in their greatest development as large as hemp-seeds, the smallest of inappreciable size. The color and texture of these masses is peculiar. Unlike ordinary granulations, they are gray and translucent, mingled with a pinkish tint. They have

the look of grains of boiled tapioca scattered over a reddish ground and separated from each other by deep clefts. There has been no tendency to hemorrhage from the sore. It gives little or no pain. The ulcerating surface does not lie below, but considerably above, the level of the surrounding tissues, and this is especially marked at the edges. The encroachment upon the cornea reaches to the border of the pupil, while a margin of opacity extends about a line farther. The tension of the globe is —1.

There is considerable hyperæmia in the neighborhood of the sore, but this does not extend over the rest of the globe in a decided degree.

The lower part of the ocular conjunctiva is thickened as in papillary trachoma, but the palpebral conjunctiva presents no hypertrophy. Below the ulcer, nearly at the level of the *cul de sac*, is a deep furrow, and then a ridge of neoplastic tissue similar to that of the principal mass. The surface of the growth may be touched with impunity.

Vision is $\frac{20}{20}$. The interior of the eye can be seen with the ophthalmoscope, and no signs of any new growth can be discovered. Even when the eye is turned far downward, the interior looks normal. The nerve is congested, its vessels rather full, both arteries and veins; lens and vitreous clear. The pre-auricular lymphatic gland is not enlarged, but a much enlarged gland is found under and in front of the angle of the jaw. It is as large as a hickory-nut. It has been in this condition for weeks, and has been larger and painful.

There has been a decided depreciation of health within a few weeks. She has lost flesh, had diarrhœa and pain in the stomach, and a little cough. Now she feels weak and has a poor appetite.

The diagnosis was a cancerous ulceration of the surface of the globe. Its precise nature was not determined by microscopic examination. Nothing but extirpation could be suggested, and this the parents and the patient were unwilling to have done. My knowledge of the subsequent history of the case is gained from Dr. Collins, who wrote to me that the patient lived about three months longer. He says that the appearance of the eye did not change much, but the tumor under

the jaw continued to enlarge. She died by exhaustion, in the country. No autopsy was made.

Cases like the above are rare, especially that they should arrive at so late a period of development before coming under the eyes of an ophthalmic surgeon. Two cases are recorded by Graefe, in the Archives, of cancroid tumors removed from the surface of the globe, and with no relapse. Wecker[1] quotes these cases, and devotes a chapter to the description of cancerous ulceration. His account resembles pretty closely the clinical features of the above case.

[1] I find a note in Deval, (Paris, 1862,) page 803, which describes in brief a case which seems essentially the same with the above. Sichel, Iconographie, page 598.

DEMONSTRATION OF PATHOLOGICAL SPECIMENS. By H. Knapp, of New-York.

I. *Intra-ocular Enchondroma.*—This specimen has been described in the *Archives of Ophthalmology and Otology*, (III. 1.) As it is the only one of its kind on record, I thought the members of this society might examine it with interest. I shall not enter into a description of it, but confine myself to the remark that I owe the specimen to the kindness of Dr. J. J. Chisolm, of Baltimore, who extirpated the growth after it had existed twenty-two years. The patient died from after-bleeding; for the arrest of which the doctor unsuccessfully ligated the common carotid artery. The growth is made up of hyaline and fibrous cartilage accumulated in nodes, and of connective tissue which, in most places, shows its conversion into cartilage.

II. *Tumor of the Iris.*—Two years ago, I visited Dr. Argyll Roberston's ophthalmic clinic in Edinburgh. A girl of about 18 years of age presented herself with a grayish tumor on the iris the size of a pea. Her sight had been failing for a year. There was distinct cupping of the optic nerve. Dr. R. extirpated the eye, and was kind enough to give it me for examination, with a complete history of the case. As the microscopic appearance of the eye is not without interest, and tumors of the iris are rare, I brought this specimen here for demonstration, before the microscopic examination destroys it.

III. *Choroidal Sarcoma. Infection of the Retina. Dissemination from the Retina to Parts of healthy Choroid.*—I am indebted for this specimen to Dr. E. Williams, of Cincinnati. A sarcomatous growth in the posterior region of the choroid produced episcleral and orbital tumors, and the patient died a few months after the removal of the eye, from meta-

static sarcomata in the inner organs of the body. The remarkable features of the specimen, which I examined carefully, are: the retina lies like an irregular cord, with an uneven, nodular surface, in the centre of the eye. It is completely metamorphosed into round-celled and spindle-celled sarcoma substance. Between it and the choroid there was fluid. On the otherwise healthy choroid a great number of isolated white nodules were seen, more densely strewn on one half of its area than on the other half. They were small sarcomata situated between the pigment epithelium and the hyaline membrane of the choroid. Microscopic clusters of a few cells were also seen upon the epithelium. The larger nodules raised and perforated the epithelial layer. The mode of propagation of the pseudoplasm exemplified by this specimen is highly important. The original choroidal tumor touched and surrounded the optic nerve, its elementary parts invaded the retina, which became detached, and fluid collected between it and the choroid. The disorganized retina ulcerated, and detached particles of the pseudoplasm fell through the subretinal fluid upon the healthy parts of the choroid. Here they took root, pierced the epithelium, were arrested by the hyaline membrane, but were in favorable nutritive conditions on account of the proximity of the chorio-capillaris. The retina in this case was infected by contact, but afterward acted as a seminium strewing the morbid seeds back on healthy portions of the choroid.

IV. *Intra-ocular Hemorrhage. Formation of Amyloid Bodies in the Vitreous. Amyloid Degeneration of the Choroidal Arteries.*—This specimen is taken from a man, 42 years of age, who came to me about six months ago stating that three days previously he had noticed that his left eye had become blind. He experienced only slight pain and some heaviness in the eye. I found very little subconjunctival injection, the pupil somewhat dull, and the fundus completely dark. Perception of light was faint. My diagnosis was: hemorrhage into the vitreous space. Leeches, decubitus, and darkening of room ordered. The upper portion of the fundus, in the course of a week, yielded a faint red reflex, and with oblique light I could see blood at the bottom of the eye. Perception of light very faint and only in lower parts of the field of vision. In

the course of two weeks, the red reflex in the upper part of the eye and the blood in the lower could no longer be seen. The whole vitreous space seemed to be filled with a semi-transparent, finely granular, dark gray-brown substance, in which no details were distinguishable. The eyeball was white and of normal tension. As the case did not assume the course of an idiopathic hemorrhage, I thought that a choroidal melanotic tumor was concealed by the hemorrhage, and was also its cause. Not being able, however, to detect any symptoms of a tumor, I told the patient my opinion, with my doubts, and advised him to have his eye examined by some other eye-surgeons. He consulted Dr. Noyes and Dr. Althof; both declared the difficulty a melanotic tumor, and urged enucleation of the globe. I did this the day after, and opened the eyeball immediately by a meridional section. The vitreous space was completely filled by a very soft, black substance such as I had never seen before. My first impression was, that I had an exceedingly soft melanotic sarcoma before me; but the microscopic examination discovered an entirely different condition: the black substance consisted exclusively of blood-corpuscles and semi-transparent, glassy-looking, homogeneous globules, which in quantity prevailed over the blood-cells. They were not changed by alcohol, ether, and acetic acid, but assumed a beautiful red-brown mahogany color by the addition of tincture of iodine. Sulphuric acid rendered them dark blue. Their amyloid nature being manifest, I examined the membranes of the eye, found them all in their proper position and normal, except the choroid, in which the inner and middle coats of the arteries had undergone extensive amyloid degeneration. Not long ago, that is, seven months after the removal of the eye, I examined the patient's general system, but found no indication of amyloid disease anywhere. His complexion is pale, but he is vigorous and never had a constitutional taint. Amyloid disease, up to this hour, has only been diagnosticated on the post-mortem table. Is it reserved to the ophthalmoscopist first to detect it in the living body? The symptoms of the preceding case appeared to me marked enough to diagnosticate this disease, if I should chance to meet with other cases.

SCLEROTITIS DEPENDING ON GOUTY OR RHEUMATIC DIATHESIS. By Henry D. Noyes, M.D., New-York.

My attention was called last winter to some severe cases of acute scleritis occurring in persons suffering from gouty or rheumatic disease, who had entered Bellevue Hospital on account of ill-health, which was the result of their constitutional dyscrasia. I saw three such subjects, and all of them had, besides other symptoms, evidences of gouty kidney, and I was at first led to associate the acute ocular inflammation with the kidney lesion. But I am more inclined to regard both as manifestations of the general disease.

In one case, which was the most important, the existence of gout was completely concealed during life by other complicating conditions, and was elicited only by the post-mortem examination. In this and in one other case, an iridectomy became necessary to relieve the violent inflammatory action. In another case, an iridectomy was intended, inasmuch as relief was not obtained by medicinal agents, but was not done because the patient feared to have it performed; and then by a change of medication a prompt and complete recovery was brought about.

Other cases show that, while a remedy may act efficiently in some instances, a totally different one must be chosen to do the work in other cases. I am not yet prepared to show what are the indications for the choice of one remedy above another.

Mr. Hutchinson has written an elaborate article in recent numbers of the Ophthalmic Hospital Reports, giving his observations of the influence of gout in causing various kinds of ocular inflammation, namely, of the cornea, iris, sclera, etc.

What I have to relate is a different aspect of the same subject, and corroborates the stress he attaches to an inquiry into this condition. He properly intimates that syphilis has acquired an almost exclusive place in the etiology of the day, and we need to be reminded that other poisons are equally capable of producing severe ocular inflammations.

For the careful and complete notes of the first case I am indebted to the resident physician of Bellevue Hospital, Dr. M. B. Early, who also made the autopsy; and for the microscopic examination of the globes I am under renewed obligation to Dr. Francis Delafield.

The case may have the following title.

No. 1.—Gouty inflammation of the tissues of the orbits and eyeballs requiring iridectomy—relief by the operations—subsequent death, and autopsy.

John Van Stan, 48, M., Ireland, painter, admitted October 26th, 1872. Patient's father and mother are living and healthy. His mother suffers from rheumatism. Several brothers and sisters living and healthy. One brother was killed in a fall. Had gonorrhœa; had a chancroid followed by a suppurating bubo. Patient had lead-colic about twenty years ago; has had several attacks since. In 1863, he had acute articular rheumatism. When in the army, he was a great deal exposed, and suffered from "cold," cough, expectoration of a yellowish matter, sometimes spitting up blood, shortness of breath, palpitation of heart. Since that time he has had occasional attacks of rheumatism. Patient is intemperate. In June last, he had an attack of lead-colic, from which he has been suffering up to the present time. On last Wednesday, he took some anti-bilious pills. He states they were followed by evacuations of blood and matter.

On admission, patient gives the above history, and complains of pain in abdomen, shoulders, arms, knee, and joints of right index-finger and left great toe, the two latter-named points being red, hot, swollen, and painful.

Physical examination: lungs, emphysematous; heart, hypertrophied.

October 30th.—Patient complains of some itching in outer canthus of left eye; some pain and soreness.

October 31*st*, A.M.—Eye is considerably swollen, considerable chemosis; complains of considerable pain; sight is very dim. Patient is able to distinguish the figure, but not the features, or colors; complains of photophobia.

November 1*st*.—Same symptoms as above, but in a more aggravated form; eyeball prominent, cornea clear. Conjunctivæ are pale; discharge thin. Ordered, ℞. Argenti nitratis, gr. v.; Aquæ, ℥ j. The above to be applied by means of a camel's-hair pencil. Ordered also cold applications, iron and quinine.

November 2*d*.—Eye looks better, apparently granular; complains of some pain. He complains this A.M. of some pain in right eye, which is considerably congested. Ordered cold applications. P.M., the left eye looks better, some pain; complains of pain and soreness in the right eye. There is considerable chemosis and congestion of the conjunctivæ. The pain is mostly at the outer part of the upper lids, and in the forehead just above and between the brows. The cornea of the right eye is clear.

November 3*d*, P.M.—Pulse, 90; Resp., 21; Temp., 100¾°. Both eyes are still pressed forward. The right eye is more so than the left. The conjunctiva of right eye swollen to edge of the cornea. The conjunctiva pressed out in a ridge over the lower lid, and covered with a whitish membrane. The discharge from the eye is mucous or slightly purulent. There is very little motion to the eyes. Patient can not look up or down. The eyes seem nearly fixed.

November 4*th*, A.M.—Pulse, 112; Resp., 24; Temp., 102°. Patient's condition unimproved. Complains of pain in the same location as before. P.M., pulse, 135; Resp., 24; Temp., 101¼°. 3.30 P.M., 10 leeches were applied to the temple. Prof. Noyes examined the eye with an ophthalmoscope.

Examination: left eye, cornea is clear; anterior chamber normal; crystalline lens not pushed forward, but has an opacity in its centre in front. The vitreous humor somewhat hazy, but permits an indistinct view of the optic nerve. Patient can distinguish the hand and count the fingers with this eye at the distance of a foot, but can not distinguish the features. The eyeball has but little motion. The swelling of the conjunctivæ is mostly around the equator of the globe and is very

hard, forming a distinct ridge when pressed back from the cornea by the handle of a scalpel. There is considerable tension of the globe.

Right eye, there is marked tension of this eye. The conjunctiva is very much swollen, the eye speculum could not be introduced to hold open the lids. The conjunctiva forms a ridge extending over the lower lid, and has a yellowish membrane over this ridge. The chemosis is very great around the equator of the globe. The cornea is slightly hazy. The anterior chamber is normal. The crystalline lens is not pushed forward and is very clear. The vitreous humor is very opaque and does not permit a view of the optic nerve. Has no sight at all in this eye. There is the appearance of suppuration going on. 4.30 P.M., Prof. Noyes performed iridectomy upward in both eyes and applied a bandage. 8 P.M., ordered Sol. morph. U. S., ʒ ij. 10.15 P.M., was called to stop bleeding from leech-bites. Found considerable arterial flow; applied solid stick of nitrate of silver, which soon checked the hemorrhage; applied compress and bandage. Patient lost two or three ounces of blood, felt comfortable. Ordered Quin. sulph., gr. x. q. 4 h.

November 5th, A.M.—Pulse, 156; Resp., 31; Temp., 102°. Slept very well; no pain during the night. Complains of no pain this morning in his eyes. Complains of some pain in his abdomen. Skin is warm and dry.

Ordered whisky ℥ ss. q. 2 h.

12.30 P.M.—Pulse, 152; Resp., 30. Patient is sleeping quietly. 2 P.M., feels comfortable. Complains of no pain. Pulse, 134; R., 36.

Prof. Noyes came at 3 P.M. He removed the dressings from the eyes. There is much greater freedom of motion in both eyes. The conjunctivæ are more congested, and the chemosis is more marked around the orbit. There is more chemosis and prominence of the right eye than the left. There is great improvement of the right eye as regards the suppurating appearances. The condition of both eyes improved above that of yesterday; can see the hand and count the fingers at distance of one foot. Can not see at all with the right eye. 5 P.M., patient feels easy; no pain; tongue coated and moist; eyes

are not painful, but feel sore; bowels moved this A.M. Skin warm and dry.

Ordered egg-nog. Pulse, 138; Resp., 30. 6.30 P.M., breath and skin smell rather sweet and strong; this has been the case for several days. Pulse, 130; Resp., 30; Temp., 99⅞°.

November 6th, 8 A.M.—Slept quite well; had a sharp pain in the right eye whenever he moved about in bed. No pain at other times in this eye. No pain at all in left eye or anywhere else. Pulse, 117; Resp., 22; Temp., 98¾°. Eyes not so much swollen. Right cornea hazy and wound not healed; left eye, cornea clear and wound healed. Can see imperfectly with both eyes, less perfect with right; chemosis not so great; eyes sore; but no pain. General condition somewhat better; skin is moderately warm. 5 P.M., Pulse, 122; Resp., 24; Temp., 99⅞°. Patient states he feels first-rate; skin is moderately warm. Had two passages from bowels to-day. No pain, feels weak. Tongue is slightly coated and dry, is very thirsty. Has some cough, but very little expectoration.

November 7th.—As the patient sleeps, there is considerable subsultus tendinum, which has been noticed at times for several days. Pulse, 110; Resp., 26; Tem., 99½°. Sight in left eye very much improved. States he can detect shadow with his right eye; both eyes much improved. General condition very much improved. 3 P.M., left eye counts fingers at eight feet; œdema almost gone; tension normal; exophthalmus disappeared.

Right eye, œdema of lid and exophthalmus have disappeared. Eye little injected; tension normal; discerns light. Is disposed to sleep and is stupid. 5 P.M., patient says he feels a great deal better; has no pain anywhere. Skin is warm and moist; tongue is clean and dry. Pulse, 100; Resp., 22; Temp. 98½°.

November 8th, 9.30 A.M.—Patient feels comfortable; has no pain. Eyes look much better. Sight of left eye greatly improved. Can count fingers with right eye at distance of two feet. Has a tendency to sleep all the time; says he feels stupid.

Treatment continued. Ordered whisky ℥ vj. in 24 hours. Pulse, 112; Resp., 33; Temp., 99⅛°. P.M., P., 119; R., 33;

T., 99¾°. 9 A.M., Pulse, 118; Resp., 33; Temp. 99⅛°. Patient feels somewhat better. Can see very well with left eye. Sight of right eye is improving; conjunctiva very much congested. Patient is still stupid and says he feels sleepy all the time. P.M., Pulse, 114; Resp., 32; Temp., 98°. Patient states he feels first-rate.

November 10*th*, A.M.—Patient says he feels very well. Orderly states that the patient was delirious during latter part of the night; was up and walking about the ward and talking incoherently. He was perfectly rational this A.M. Had a good appetite for breakfast this morning. Had a passage from bowels. Pulse, 121; Resp., 35; Temp., 98⅝°. P.M., states he does not feel so well. Complains of shortness of breath, some cough. No pain. Examination of lungs reveals a few moist râles over lower portion of left lung. Had two passages from bowels to-day, passes water freely. Tongue is clean and moist; skin is warm and moist. P.M., Pulse, 124; Resp., 38; Temp., 99½°.

November 11*th*, A.M.—Pulse, 120; Resp., 34; Temp., 98¾°. Patient is very stupid; has aphonia this A.M. Complains of shortness of breath last night and this A.M. Complains of weakness, and says he feels stupid. No pain anywhere. Throat feels dry. No swelling or tenderness in throat. Tongue is dry and coated brown. Appetite good. Eyes are still somewhat congested. Sight is still improving.

November 11*th*, P.M.—Pulse, 128; Resp., 32; Temp., 100¼°. Patient states he feels comfortable. Has no pain, has some cough. Expectoration abundant and muco-purulent. Has an offensive odor. Some dyspnœa. Has had three passages from bowels to-day.

November 12*th*, A.M.—Pulse, 128; Resp., 33; Temp., 99. Says he feels better, was very quiet last night. Had four assages from bowels yesterday; but none since. They have an offensive odor. Skin is warm and dry. Tongue is brown, dry, and fissured. Has some cough and yellowish expectoration. Relapses into stupor immediately after being aroused. 5 P.M., Pulse, 124; Resp., 40; Temp., 102°. Patient is very weak; is still stupid. Has cough and some dyspnœa. Physical examination reveals moist râles over both lungs posteriorly.

Ordered,

℞. Ammoniæ muriat.....ʒ ij.
Syr. prun. virg.,
Aquæ camphoræ.....āā ℥ j.
M. et sig., ʒ j. q. 4 h.

November 13*th*, 9 A.M.—Patient was quiet all night; died at 6.40 this A.M.

Autopsy, *November* 14*th*.—Exterior body moderately emaciated. Eyes and orbits, nothing to gross examination. Brain and membranes, increase of subarachnoid serum; normal quality. Slight opacity of the arachnoid. Some increase of ventricular serum. Brain-tissue normal.

Heart, left ventricle slightly hypertrophied; walls and membranes otherwise normal. Lungs, small cavity at the right apex. Considerable fibrous induration at the apex of the right lung, less in the left. Small nodules in the lung composed of firm gray and brownish elastic granules. The lower lobe of both lungs congested, but that of the right side more so. Œdematous, and air-cells contain some exudation.

Liver normal. Spleen a little enlarged. Kidneys small; capsule adherent; surface granular. Cortex, diminished size. Urates in the tubes of the pyramids and of cortex, knee, and metacarpo-phalangeal joint of great toe. Spinal cord, nothing except calcareous plates on the arachnoid.

Microscopical Examination of Eyes, by Dr. Delafield.—Both eyes have been removed with the muscles and surrounding tissues attached, and with nearly the entire length of the optic nerves. Both eyes present the same appearances. When they are opened, the vitreous is opaque. It contains fibrin and small round cells; at the fundus, a thin layer of fibrin and cells separates the *retina* from the *choroid*. The iris presents the coloboma of an iridectomy. The *lens* is in place. The *ciliary body* is swollen and filled with round cells. The choroid shows a remarkable distention of all its vessels with blood. The *retina* is altered by decomposition. The optic nerve is not cupped; it appears to be normal over its entire length. The *sclera* is thicker and denser than usual, especially at the fundus.

There seem to be, therefore, acute inflammatory changes, affecting the ciliary body, choroid, and vitreous in both eyes.

This history is furnished by M. B. Early, M.D., *House Physician.*

It had been my suspicion during the life of the patient and at the outset of the severe inflammation, that a pyæmic process was taking place in the orbits and indirectly affecting the eyes. The extreme prostration which occurred 48 hours after the iridectomies confirmed this opinion. The record of the pulse and temperature point to a very grave constitutional disturbance. From this, however, the patient rallied by the help of vigorous doses of quinine and whisky, and subsequently sank under influences which could not be accurately specified. In fact, the full diagnosis of the case was not made except upon the post-mortem table. While it was known that the man had had chronic rheumatism and what seemed to be lead-colic, (he was a painter,) the urine was not searched for urates, and gout was not thought of. When, however, uric-acid crystals were seen in the substance of the kidneys, and a deposit of urates found upon the cartilaginous surfaces of the joints of the knee and of the great toe, the true pathology of the case was made clear.

Two other cases in Bellevue Hospital I can only record from memory.

No. 2.—Gouty kidney, dropsy, cachexia; acute scleritis, iridectomy, relief; afterward relapse, and cure by iodide of potassium.

A man, æt. 60, of very intemperate habits, came into Bellevue Hospital in February, 1873, with dropsy and general cachexia, the result of his abuse of alcohol, and of gouty degeneration of his kidneys. His history clearly indicated that he had suffered from chronic gout, and the examination of the urine revealed that the kidneys had been invaded by this lesion. There was an œdematous condition of all the tissues, great anæmia, and his complexion sallow. There was a slight amount of heart-trouble. After he had been a short time in the hospital, he got inflammation of both eyes, which developed as a general scleritis of moderate severity. There was pain, general injection, moderate chemosis, a little lachrymal and no

catarrhal secretion; the aqueous became hazy, but the pupil not adherent. Leeches, cold water, and atropine were applied. After a few days, as the condition grew worse, iridectomy was done in both eyes. Relief ensued; but complete recovery was slow to take place. After three weeks, the injection of the eyes had not entirely disappeared, and then a subacute attack of the same kind of inflammation recurred. For this, iodide of potassium in doses of five grains three times daily was prescribed; and in four days the symptoms had yielded, while entire restoration was brought about in ten days. The man improved in health so as to be able to leave the hospital and return to work.

No. 3.—Another case in Bellevue was in a man æt. 30, likewise diagnosticated as having chronic gout with lesion of the kidney. In him a rather mild form of acute scleritis attacked both eyes, which yielded in a week to cold water, atropine, and Rochelle salt. No serious implication of the inner parts of the globe occurred.

A CASE OF WOUND OF THE SCLERA TREATED BY SUTURE, WITH REMARKS. By Thomas R. Pooley, M.D., of New-York.

It is one of the fundamental rules of surgery, in all cases of simple incised wounds, to bring the edges of the wound in contact after all bleeding has been arrested. It would seem strange, then, that this course of treatment has not been more adopted in the treatment of wounds of the eye. There are various means for bringing about this object, such as position, support by bandage or adhesive plaster, and the suture. The latter would seem at first sight to be most appropriate in wounds of the eyeball, and yet it is only lately that it has come into frequent use. This is no doubt due, in a measure, to the fact that such wounds of the eyeball are usually small and do not gape very wide, and again to the difficulty of their application and subsequent removal. In support of this latter fact, Mr. Thomas Windsor, in an interesting paper on "The Treatment of Wounds of the Eye by Suture," (Manchester Medical and Surgical Reports, October, 1871, pp. 1–8,) mentions the difficulties encountered in the introduction of sutures in the various trials at keratoplasty, and how often the attempt failed. An interesting review of these attempts at this impracticable operation may be found in his paper. It is not the purpose of this paper to say any thing about this subject, but to confine our remarks to the use of sutures in wounds of the sclera. It is well known that the possibility of introducing sutures even in the cornea has been demonstrated by Dr. Williams of Boston, who used them after cataract extraction. It is not necessary here to speak of his method, as

it is mentioned in his book, and again in the "Archives of Ophthalmology and Otology," (ii. p. 102.)

It was shortly after reading Mr. Windsor's paper, that the case I am about to report came under my care, and this method of treatment at once came into my mind. Before giving my own case, however, let me give in brief the recorded cases in which a wound of the sclera has been sutured. I should add that this task is rendered easy by making use of the references in Mr. Windsor's paper.

Von Walther just mentions the use of sutures in wounds of the eye, but, it appears, had never tried them himself.[1] The first case to which I refer was recorded by Dr. O. D. Pomeroy.[2]

"John S. N——, aged 21 years, a soda-water manufacturer, was struck on the eye by fragments of a soda-bottle which had burst, inflicting a wound of the sclerotic at the margin of the cornea, about four lines in length, causing a prolapsus of iris, (and perhaps of choroid,) an unsightly coloboma resulting. I easily succeeded in reducing the prolapsus, although it remained but momentarily. Two sutures were then passed through the conjunctiva, near the margin of the wound, and gradually tightened as the prolapsus was reduced; they failed, however, in reducing the whole, so a suture was placed between the two already in. The sclerotic aspect of the wound afforded a sufficiency of conjunctiva, but not so with the corneal; so the suture was passed through a portion of the sclerotic at its corneal junction, which closed the wound satisfactorily. The after-treatment consisted in the application of ice to the eye, atropine, and leeches.

"In fifty hours, the lateral sutures were removed, when the wound was found to be well adhered. On the next day, an effort was made to remove the central suture; but as the wound showed signs of gaping if much interfered with, it was not removed until the following day, when the wound was found to be well united. There was a little conjunctival injection,

[1] P. F. Von Walther, Augenkrankheiten, ii. p. 16. Freib. i. Br., 1849.

[2] Ophthalmic Review, vol. iii. p. 80, from the Boston Medical and Surgical Journal, vol. lxxiii. p. 216.

which disappeared in a few days. Patient sees as well, or nearly so, as with the other eye, which is normal."

Mr. Bowman twice resorted to this procedure.[1] In the first case, John M., aged 25, was admitted into the hospital October 31st, 1862, under Mr. Bowman, on account of an injury he had received the day previously. He was at work with an iron punch, when a piece flew off and struck the sclerotic on the inner side of the cornea close to its margin. There was a horizontal wound in the sclerotic at the inner margin of the cornea about $\frac{1}{8}''$ in length. The edges were not in apposition, and vitreous was oozing out. The anterior chamber was deep and the plane of the iris sloping backward. The aqueous was serous—T. 3, and daily diminishing. He could count fingers at from 6 to 7′. Mr. Bowman first made iridectomy at the inner side, and then adjusted the edges of the wound in the sclerotic by a fine suture, the needle being made to pass through each lip of the wound from within outward; using a fine silk thread with a needle attached at each end.

The second night after the operation, the man had a good deal of pain, which was relieved by leeches.

On November 4th, the iris had assumed its proper plane, the lens had come forward, and the tension of the globe was normal. The thread had come away. He could see letters of 16 Jaeger. The case did well, and when he left the hospital, (November 25th,) he could read letters of No. 10.

Mr. Lawson gives a short account of the second case, which is given exactly in his own words. "Mary S., aged 9 months, was brought to the hospital on July 7th, 1863, suffering from an injury to the left eye. A piece of china in falling off a shelf struck the eye, and inflicted a small wound in the sclerotic, close to the corneal margin. The wound (notwithstanding that a week had passed since the accident had occurred) was still a gaping one; the edges of it not being in apposition. Mr. Bowman applied a single suture, and with it brought the lips of the wound accurately together. No irritation followed; and on July 21st the child ceased its attendance at the hospital, the eye being quite well."

Mr. Lawson has also reported a case which was under his

[1] Injuries of the Eye Orbit and Eyelids. Lawson, London, 1867, p. 59.

own care.[1] The patient came under his care on March 5th, 1869. A few hours before, a fragment of stone flew up and struck him on the left eye. There was a jagged wound in the sclerotic, in the lower part of the eye, a short distance from the cornea. A small quantity of vitreous had evidently escaped. The wound gaped, and its lower edge was prominent, and stood away from the upper margin, which was somewhat depressed. A single suture was introduced about the middle of the wound, and brought the divided parts into apposition. The patient progressed most favorably, and the wound completely united; the presence of the stitch produced no irritation. On April 27th, the eye was free from redness and seemed to have completely recovered from the accident; but on testing his vision, he could only count fingers, and on examination with the ophthalmoscope, an extensive detachment of the retina was seen to correspond with the site of the puncture.

Mr. Windsor's case is recorded in the paper already referred to, (l. c. p. 5.) He was called to see a child whose left eye had been injured two or three hours previously. The injury was inflicted with a large blunt curved knife. On raising the lid, an incised wound was found, commencing in the inner and upper side of the cornea and extending through the sclera backward for fully half an inch; there was a nodule of iris in the anterior part; the rest of the wound was gaping widely, and through it vitreous was bulging, though none appeared to escape. Mr. W. at once thought of ligature, but it appeared unadvisable to him to give chloroform, as the child was certain to cry and struggle and the least effort would force more vitreous out of the wound; he therefore decided to wait. He applied a bandage to the injured eye, and closed the other by plaster.

The patient was kept in bed for some time; hardly any inflammation occurred, and the wound gradually contracted.

Progress being slow, it was determined to remove the prolapsed iris, which was done under chloroform. This had a beneficial effect, the anterior part of the wound was soon firmly healed, the posterior part uniting also for a little distance further.

[1] Royal London Ophth. Hosp. Reports, vol. vii. part 1, p. 14.

In November, the centre was still open and allowed the vitreous to project; the bandage was tightly applied, and continued until December 27th, when, as the prolapse of vitreous increased rather than diminished, chloroform was given, the projecting nodule excised, and a suture passed through the middle of the wound. As the edges of the wound were thickened, endeavor was made to pass the thread obliquely through it.

The stitch, when drawn tightly, completely closed the wound. A bandage was applied. The next day the parts immediately around the wound were injected, and there was some pain. On the 30th, less congestion, and the suture had cut partially through.

A day or two after, the suture came away spontaneously, and on January 6th, the wound appeared quite closed. On the 20th, the cicatrix was quite level and all irritation had gone. When last seen, (February 24th,) the wound was quite healed. Pupil of good size, but displaced inward with a rather large coloboma. He reads slowly No. 5, and letters of No. 4 Jaeger. Media and fundus normal.

These are, so far as I have been able to find, the recorded cases, in which suturing of the sclera has been resorted to for wounds of the eye, and I will now add to them my own case. The fact that the subject was fresh in my mind when this case offered, had no doubt some influence in determining me to try it, and, as will be seen, the result was fully as satisfactory as in any of the cases I have enumerated.

James O'Neil, aged 32, a fireman, was admitted to Charity Hospital January 27th, 1873. Four days before, while chipping steel, a piece flew off and struck his right eye, causing a wound which bled a good deal at the time. The evening following the injury, the eye was very painful and he had flashes of light in it. Upon admission to the hospital, examination revealed a large horizontal wound of the sclera fully ½″ in length. It was situated at the lower and outer part of the eye, and extended into the cornea. The iris was adherent to the corneal wound, but did not prolapse. The edges of the scleral wound were gaping widely, and a nodule of vitreous protruding.

The tension of the eyeball was greatly diminished —T. 3.

He could only count fingers at 3′. Examination with the ophthalmoscope showed considerable opacity of the vitreous, from hemorrhage, but not sufficient to prevent a reflex from the fundus; no details, however, could be made out. The visual field was normal.

As it seemed to me quite impossible to bring the edges of the widely separated wound together without a suture, I introduced a simple, very fine, black silk thread through the middle of the sclerotic part of the wound.

The needle was passed by means of the needle-holder in the ordinary way, from without inward, except that I passed it obliquely through both edges of the sclerotic, without penetrating its whole thickness.

When tied, the suture exactly adjusted the edges of the wound, and completely prevented the further escape of vitreous. A pressure bandage was now applied, atropine instilled, and the patient put to bed. The next day, (January 29th,) the patient had passed a good night, there had been some pain in the eye, but not enough to keep him awake. The edges of the wound were in apposition, and no vitreous escaping. Pupil ovally dilated. There was but little injection in the vicinity of the wound.

February 1st.—The wound having firmly and evenly united, I removed the suture, continuing the bandage. The eye was quite free from pain or irritation. The case continued to progress favorably, and on the 8th of February the patient was discharged. The tension of the globe was now normal; vision had risen to counting fingers at 10′, but the vitreous was still too opaque to allow a good view of the fundus. The field of vision was complete. The cicatrix was smooth and even, but the iris remained adherent to the corneal wound. I did not see the patient after he left the hospital. I have now enumerated (including my own) six cases in which this procedure was resorted to, and all of which terminated favorably.

Mr. Windsor's case is particularly instructive, for it shows that union may be effected by the use of a suture, even though the edges of the wound may have been separated for a long time. In view of this fact, he suggests that this method might

be employed with success in cases of fistulæ of the cornea and sclerotic.

Chloroform was not given in my case; but in performing the operation upon children, it would undoubtedly be necessary, to prevent a further escape of vitreous.

In all of the cases we have cited, the stitch produced little or no irritation, and in most of them was allowed to come away spontaneously. I should prefer to remove it, however, after a firm union of the wound had been accomplished. This is rendered much easier if a black thread has been employed. In conclusion, it seems to me that in all cases of wounds of the sclera or cornea in which the wound gapes, and when union is not readily accomplished without, a suture may with advantage be applied.

REPORT OF ONE HUNDRED AND FOURTEEN EXTRACTIONS OF CATARACT. By H. Knapp, M.D., of New-York.

During the last four years and a half, I made in the city of New-York 114 extractions. In this number all cases of cataract, complicated and uncomplicated, that I have operated on are included, except such in which a recent traumatic lesion had done some serious injury to the eyeball. The *results* I have obtained are less favorable than those I had in Europe. This, it seems to me, is due to a greater percentage of unfavorable cases I have had to deal with in America. Of the 114 eyes, *I have lost* 13, which is more than twice as many as I lost in Heidelberg. Among the losses I have included all cases that could not count fingers at the distance of a foot. Some of them would probably gain useful sight by an after-operation; but in preparing statistics we have to note things as they actually are, not what they are capable of being. There were 9 eyes which obtained only moderately good sight, namely, from $\frac{1}{200}$ to $\frac{10}{20}$, and 92 had good sight, from $\frac{20}{200}$ to $\frac{20}{20}$.

Methods of Operation.—One hundred eyes were operated on by Graefe's method, with a loss of 12 eyes; 13 by Weber's method, of which one eye was lost six months after the operation, the individual being a drunkard of the lowest class. One eye was operated on by Le Brun's method with S $\frac{20}{20}$, but with extensive anterior synechiæ. Weber's operation I did, in 1871, thirteen times in succession, but gave it up in spite of the good results, on account of its uncertainty and accidents to which it is liable. I pointed out the advantages and disadvantages of Weber's method at the meeting of the American Medical Association in 1872, in a paper pub-

lished in the Transactions of that Association. I have followed Graefe's method with the following deviations. The *centre of the flap* touches, or nearly touches, the upper transparent margin of the cornea. The section is as linear as Graefe's, with no partial return to the flap. It seems to me that this location of the wound is sufficiently removed from the ciliary body so that the operation and its consequences leave the deeper parts of the eye uninvolved. I *circumcise* with a cystotome that portion of the *anterior capsule* which corresponds to the whole space of the pupil after a broad iridectomy has been made, and endeavor to remove the circumcised piece of capsule with the cystitome or the forceps. Where I did not succeed, the piece of capsule mostly came out with the cataract. In expelling the lens, I gently depress the posterior lip of the wound with a broad spoon, and press upon the cornea from its lower margin upward, while an assistant steadies the eye with the fixing forceps.

Of the *accidents during the operation* I will here mention only the *escape of vitreous*, which happened 10 times, twice in the 13 Weber's operations, and 8 times in the 100 Graefe's operations; it occurred only 3 times in cases of ordinary cataract; the remainder were in cases of immature, (1,) disciform, (1,) Morgagnian, (2,) and hypermature (3) cataracts.

In five instances I was obliged to *force* the extraction of the lens by introducing *instruments* into the eye, namely, once, successfully, a sharp hook, and four times a broad spoon, upon which three eyes were lost. I appreciate the danger inherent to all traction instruments, especially that of large spoons, which I employ only when there seems no prospect of removing the lens by any other means. Spoons are, it seems, the most dangerous, yet the only reliable traction instruments. Since they have been used in the worst cases only, my statistics should not be adduced to disapprove of their applicability in general. In eyes otherwise healthy, they seem to do comparatively little damage, as is demonstrated by the experience of A. Pagenstecher and others, who use a large spoon in almost every extraction of the lens together with the capsule.

Among the *abnormalities of the healing process* which were observed, I mention the following:

(*a*) *Spongy exudation in the anterior chamber*, three times, results good.

(*b*) *Partial suppuration of cornea, with puriform exudation in the anterior chamber*, was twice successfully treated by making vertical incisions into the infiltrated borders of the wound and evacuating the anterior chamber.

(*c*) Two cases of *plastic capsulitis;* the inflammation began in the upper segment of the capsule, and traveled around the borders of the excised piece of capsule; leaving the centre of the pupil free and the vision unimpaired.

(*d*) One case of *purulent capsulitis*, ending in closure of the pupil and S $\frac{1}{\infty}$ with F complete. The patient did not reappear; his case, therefore, is counted among the losses.

(*e*) One case of *irido-cyclitis*. It was a bad operation, the knife was blunt, vitreous escaped, and the immature cataract had to be removed with the spoon. The patient had two nuclear cataracts with transparent cortices, saw badly, and had come from some distance, the State of Michigan. All this misled me to operate on him. His was the worst case in the whole series, and the only one in which I have to reproach myself for having operated on an eye without proper indications, and moreover, having done the operation badly by neglecting to test the edge of my knife. In the third week, the iris bulged forward and the pupil was crater-shaped. I performed an iridectomy without benefit. I have not heard from the patient since he left the hospital a year ago. The conditions of his operated eye were such as might produce sympathetic trouble in the fellow-eye.

(*f*) *Iritis and hyalitis* with following closure of the pupil and S $\frac{1}{\infty}$ were observed in two patients; the one leaving this city for Porto Rico; the other, two years later, for the next world; and neither having yet returned, I had no opportunity of improving their sight by an iridectomy, but had to register the two among the failures.

(*g*) *Iritis simplex*, leaving pupillary obstructions impairing the vision to a certain degree, was observed in eleven cases.

(*h*) *Detachment of the retina* was noted once, namely, in the case of the drunkard above mentioned, who had been operated on successfully by Weber's method. As the detachment oc-

curred only some months after the operation, in a debauched person, I do not know whether I did right in counting his case among the failures.

I performed *fifteen after-operations* in this series of 114 extractions, which is less than I used to perform formerly. The reason of it is, that of late years I have endeavored, and almost always with success, to remove the central portion of the anterior capsule, which leaves the pupil less obstructed than when the capsule is simply lacerated. The after-operations consisted of twelve *discissions*, some six months or a year, the majority within the first six weeks after the extraction. None of these operations was followed by a noteworthy reaction. I made the incision with one or two sickle-shaped needles when the opacities in the pupil were recent, and with a Graefe's or Beer's knife, when they were old and tough. Twice the operation left the visual acuteness as it was; in the other it increased it materially. Besides these discissions, I made iridectomy in three other cases—the one to arrest cyclitis in the case before mentioned, the two others in cases of dense pupillary membranes—in the one with tolerably good result, in the other destroying an eye which before counted fingers at five feet. In this case, which looked very favorable, and would undoubtedly have done well had I made an ordinary iridectomy, I tried a new method of operating. I made an opening into the lower segment of the cornea with a lance-shaped knife, then thrust the sharp-pointed blade of a delicate pair of scissors through the iris and cut it obliquely upward and outward; then I carried the blade of the scissors back to the first point of the incision and made a second incision, nearly at a right angle with the former one, upward and inward. The angular piece of iris thus formed, contracted toward its attached base, and left a beautifully clear pupil. The patient had pain during the night; purulent iritis and panophthalmitis followed from the second day. This kind of angular iridectomy tempted me by its rational appearance, yet I had tried it with the same unfortunate termination not long previously. This was in an eye where closure of the pupil had followed traumatic cataract. I made the first steps of the operation as I did in the case just related; then I endeavored to pull the

retracting triangular piece of iris out, in which attempt I did not succeed. Suppurative iritis followed, produced, I thought, by the bruising of the iris in the endeavor to draw a piece of it out. Since the avoidance of such bruising in the second case did not obviate suppuration, I made up my mind never to try again this operation, which I may style "angular iridotomy."

The preceding remarks form only a part of the report, yet I thought it proper to limit them on this occasion when so many important things claim your time. I have confined myself to observations of a directly practical nature, leaving the detailed discussion of the subject to a publication in the Archives of Ophthalmology and Otology.

REPORT OF TWENTY-FIVE CASES OF MEDIAN FLAP EXTRACTION. By Henry W. Williams, M.D., Boston.

Since October 18th, 1872, I have performed median flap extraction in twenty-five cases; the upward section being made according to Le Brun's method in nine cases, the lower section according to Liebreich in sixteen. Anæsthesia by etherization in all the cases.

The corneal wound united without ulceration in all the eyes operated on, though in five instances the healing process was a little delayed by slight protrusion of the iris at one extremity of the section, and there was subsequently some anterior synechia. In one case, where the results were perfect as regarded the operation, there was found to be so much atrophy of the optic nerve that the patient could only distinguish features. One eye was lost, in a very cachectic person, from hyalitis. In another instance, one eye suffered from iritis implicating the capsule and requiring its removal from the eye; but there is every reason to expect good results from a secondary operation to free the pupil from adhesions, the patient being even now able to see the time by a watch with this eye. Two other cases had partial closure of the pupil by adherent capsule, which will require laceration.

All the other eyes operated on obtained good vision, reading ordinary print, though in three patients the number of glasses was not recorded through inadvertence.

October 18*th*, 1872.—Mr. ——, æt. 70. Semi-hard cataract, both eyes. Lower section. Discharged November 4th. Sees well at distance with right eye with $+4\frac{1}{2}$, and reads with $+3$. In left eye, partial adhesion of the capsule to margin of pupil will require a slight secondary operation.

October 24th.—Mrs. ——, æt. 61. Hard cataract, both eyes. Lower section. Discharged November 15th. +7 for distance, +3½ for reading.

November 8th.—Mr. ——, æt. 62. Semi-hard cataract, both eyes. Lower section. Discharged November 23d. Well. Glasses not recorded.

November 18th.—Mrs. ——, æt. 65. Hard cataract, both eyes. Upward section. Discharged November 28th. +4½ for distance, +2½ for reading.

November 25th.—Mr. ——, æt. 71. Semi-hard cataract, right eye. Upward section. Discharged December 13th. No accidents as regards operation; but sees only to distinguish features with +6, on account of atrophy of optic nerve.

December 13th.—Mrs. ——, æt. 71. Hard cataract, both eyes. Lower section. Discharged December 24th. +4½ for distance, +2½ for reading.

December 13th.—Mr. ——, æt. 74. Semi-hard cataract, both eyes. Lower section. Discharged December 30th. Good vision. Glasses not recorded.

December 16th.—Mr. ——, æt. 55. Semi-hard cataract, right eye. Lower section. Discharged December 27th. +4½ for distance, +2½ for reading.

December 25th.—Mrs. ——, æt. 65. Hard cataract, right eye; semi-hard, left eye. Lower section. Discharged January 8th, 1873. +4 for distance, +2½ for reading.

April 2d, 1873.—Mr. ——, æt. 68. Hard cataract, left eye. Lower section. Discharged April 15th. +5 for distance, +3 for reading.

April 14th.—Mr. ——, æt. 60. Semi-hard cataract, right eye. Lower section. Discharged April 28th. +4 for distance, +2½ for reading.

April 18th.—Mrs. ——, æt. 51. Semi-soft cataract, left eye. Lower section. Inflammation of capsule and hyalitis, requiring removal of capsule on 20th. Good union of corneal wound, but closure of pupil by adhesions to hyaloid. No vision. A very cachectic subject, whose other eye had been previously operated on unsuccessfully.

April 18th.—Mrs. ——, æt. 43. Semi-hard cataract, both eyes. Lower section. Discharged May 9th. Slight anterior

synechia in right eye; but good vision in both eyes. Glasses unrecorded.

June 9th.—Mrs. ——, æt. 74. Hard cataract, both eyes. Lower section. Discharged July 4th. Slight anterior synechia, but sees well at distance with $+4\frac{1}{2}$, and reads with $+2\frac{3}{4}$ with right eye. Partial capsular adhesions in pupil of left eye requiring laceration.

June 13th.—Mr. ——, æt. 65. Hard cataract, right eye; semi-hard, left eye. Lower section. June 17th. Inflammation of iris and capsule in left eye; the capsule was removed with fine forceps through the centre of corneal wound. Discharged June 28th. Right eye sees well at a distance with $+4\frac{1}{2}$, and reads with $+2\frac{3}{4}$. August 4th, sees to tell time by a watch with left eye, but the pupil is partially closed by adhesions.

ON THE IMPORTANCE OF AN ACCURATE RECORD OF ALL OPERATIONS FOR CATARACT AND THE RESULTS OF THE SAME, WITH SOME PRACTICAL SUGGESTIONS. By HASKET DERBY, M.D., Boston.

THOSE of us who were present, a few years ago, at the first meeting of this Society in New-York, can well recollect the numerous and radical changes that have occurred, in our own time, in the accepted method for the extraction of cataract, the capital operation of ophthalmology. Hardly any one of the leading operations of general surgery has passed, within a much more extensive period, through such vicissitudes. At the commencement of my own practice and in the city of Boston, I found a respectable number of the older practitioners adhering to the time-honored reclination, and even discission, of senile cataract; while our president was striving for the introduction of flap extractions, then in general use in Europe. To him belongs the honor of demonstrating to his younger colleagues, fresh from the schools of the Continent, the safety and advantage of anæsthetics, which they had been taught to discard, for this purpose. It is needless to-day to refer to the general applicability and entire safety of the agent which our experience teaches us to deserve the title of the anæsthetic *par excellence*, to the exclusion of chloroform, nitrous oxide, and the newer and fleeting fashions of the day.

Following in rapid succession on the general revival in this country of flap extraction, performed under the influence of sulphuric ether, came the modification by Mooren, the scleral flap of Jacobson, the outspooning of Waldau, Critchett, Bowman and Pagenstecher, and in 1865 the peripheric linear

method of our illustrious von Graefe. Its general adoption divided our ranks into rival, though numerically unequal, camps. On the one side were the advocates of the pure or variously modified flap; on the other, the adherents of the linear or nearly linear cut combined with iridectomy. One side has striven to convince the other by theoretical arguments as well as by practical statistical proof; with what result, every colleague present has undoubtedly formed a clear opinion.

Very recently, the question of the best operation has been reopened by Liebreich, and the median corneal cut without iridectomy has been largely practiced and highly extolled. Many of the advocates of the corneal flap have ranged themselves on the side of this new method, still in opposition to the views of the school of von Graefe. Again are we called upon to decide as to the relative advantages of two procedures, so widely at variance that it is safe to assert that one will, in the long run, be found to offer better results than the other. Preconceived opinions and personal predilections must here be set aside, and the question settled, as settled it most undoubtedly will be, by the logic of facts and figures. To urge the systematic and accurate attainment of the same, by means of concerted action, is the object of this paper.

For, after all, why should not our collective experience be brought to bear on this as well as similar questions, instead of caviling at and often only grudgingly accepting the tables furnished by foreign journals? And why have we in America and England lagged so far behind our continental brethren in the accumulation and publication of operative statistics? With the labors in this field, already made public, we are all familiar. Von Graefe's project of giving to the world his accurate tables of all his cataract operations, however performed, a project long cherished and in part doubtless matured, was interrupted by his untimely decease, and his bare results are to be met with in various disjointed summaries. It is unnecessary to more than refer to the series of three hundred extractions so carefully analyzed by Knapp, to the table of nearly as many operations mostly performed by Snellen at the Utrecht Hospital, and so conscientiously and exactly noted, and to the very full reports of the cases operated on at the

Clinique of de Wecker, published in the years 1872 and 1873, and embracing upward of three hundred operations, besides several smaller tabular statements by various, mostly German, colleagues.

Against all of this what have we to show? The institution from which, of all others, the most might have been expected in this regard, maintains an unbroken silence. For the Royal London Ophthalmic Hospital Reports shed but a feeble light on the question of the best operation for the extraction of cataract; the more recent rich experience of Moorfields Hospital has as yet, and for the rest of the world, been accumulated in vain. While here in America the Infirmary of Dr. Knapp in New-York and the Boston Infirmary are the only ones that have, to my knowledge, even attempted to array their results in a form available to the seeker for truth. Three out of the four last published reports of the Massachusetts Charitable Eye and Ear Infirmary contain a careful, and the last a somewhat extended statement of its annual operative experience in this direction. Beyond this all is a blank. We do indeed find stated in infirmary and hospital reports the number of cataracts operated on during the year, but there the record stops. "We exist," say they, "we operate, we invite charity, we receive patients, we dispense instruction. Our results are our own business, and in them those outside have no share."

An able surgeon recently commenced an article on ovariotomy and his experience therein, with the enunciation of his belief that those who published no statistics did so because they had none they could publish. A statement of this kind, made with reference to American ophthalmologists, would be justly scouted by those familiar with their known skill. Have we never, however, reflected that our conduct in this regard has exposed us to such an imputation?

During the past spring, I addressed circulars to all the active members of this society, inviting a statement of their comparative experience in the operations of von Graefe and Liebreich, and requesting a *résumé* of the statistics on which their opinion was based, when it had been thus formed. I received

twenty-three answers, which may be briefly analyzed as follows:

5 expressed a decided preference for Liebreich's operation.
6 an equally decided opinion against it.
12 had formed no opinion.

11 had never done Liebreich, being satisfied with existing methods.

1 had statistics "unfit for use."

1 had fifty-eight per cent "good results" by Graefe, but gave no figures or standard.

1 had done one Liebreich, no result given.

1 had done two Liebreichs, no result given.

1 had done fourteen Liebreichs, one result given, (V. $\frac{18}{100}$;) had also done one hundred and fifty Graefes, but "kept no accurate statistics, has wholly discontinued doing so."

1 had done twenty Liebreichs, no result given.

And finally,

1 had done one Liebreich V. $\frac{28}{10}$

1 had done two Liebreichs $\begin{cases} \text{V. } \frac{18}{100} \\ \text{V. } \frac{28}{100} \end{cases}$

1 had done four Liebreichs $\begin{cases} \text{V. } 0 \\ \text{V. } \frac{1}{\infty} \\ \text{V. } \frac{28}{30} \\ \text{V. } \frac{28}{30} \end{cases}$

We obtain thus a total of forty-four operations done according to the method of Liebreich, results being furnished in eight cases.

Comment is needless!

Whatever course now our English brethren may see fit to adopt, it is, I think, self-evident that a persistence in our present plan of neglecting the accumulation and comparison of the results of our operative experience is incompatible with the idea of progress and improvement. Unless every new operation for cataract is to run the course of the fashions of the day, to be accepted or assailed on theoretical grounds, to be commended for its novelty and deserted for a yet more novel successor, we must seek to establish its worth on a more solid basis, and to judge it by its results. I feel fully justified

in laying down the rule that it is the duty of every surgeon who undertakes the removal of a cataract to record the facts in the case, and to take the trouble to ascertain the amount of vision that the patient ultimately acquires.

I am aware that the objection will be at once raised that such a course is impossible in hospital practice—that patients often leave so unexpectedly, before the expiration of a proper period of convalescence, or before the opportunity of a suitable examination has been afforded, that an accurate determination of the amount of vision in every case is a simple impossibility.

That, with the most earnest effort and unsparing pains, there may always be a certain number of unrecorded cases, I readily admit. But that the percentage of such cases may steadily be diminished, and ultimately, by personal assiduity, be reduced to a minimum, my own experience has amply proved. And the means I have found most efficient has been the Cataract Register I herewith submit to the inspection of the society. It consists, as will be seen, of a series of parallel columns, arranged under the following heads:

No. of case.
Name.
Age.
Index of reference (that is, page of hospital or private records where full history and details of case are given.)
Diameter of cornea.
Dilatation of pupil under atropine.
Perception of light.
Projection.
Date of operation.
Remarks on same.
Length of after-treatment.
Vision (with date of testing) for Far.
" " " " " " Near.
Subsequent history.

Were this, or some similar record-book, conspicuously displayed in the office of every ophthalmic hospital; were the name, particulars of case, and date of operation of every

patient entered by the assistant, and the surgeon himself made responsible for the filling out of the remaining blanks, the wealth of valuable material that is now recklessly flung away would be, with each year, more and more thoroughly utilized. Why should not we emulate our German brethren in this regard, and why should not each member of this society bring to its annual meeting some such record of his labors? Be his operations one or many, be his method this or that, be his results favorable or the reverse, it will at least be an honest effort to accumulate a fund of knowledge and experience, profitable to our successors and accruing to the benefit of humanity.

I will simply add one or two suggestions that have occurred to me as a result of my own experience, and which may perhaps be found worthy of being brought forward at the meeting of the Ophthalmological Congress in 1876, for concerted action.

1*st*. *Tables of cataract operations by a single method, intended to serve as a basis of comparison with the results of other methods, should include only cataracts that are neither the result of local injury, tangible local or general bodily disease.*

Under this rule, all traumatic cataracts, those resulting from any intra-ocular affection known to have previously existed, from diabetes, etc., would be excluded, or at any rate separately catalogued.

2*d*. *In recording vision, the full fraction should be stated, the number of test-type seen, and the distance in which it is actually seen, no attempt being made to reduce the fraction to lowest terms.*

3*d*. *The test card should be artificially illuminated by a light of fixed power, placed at a stated distance from the centre of the card.*

It is to be hoped that the International Society will, at its approaching session, fix both the intensity and distance of the source of illumination.

4*th*. *The date of testing, as distinct from that of the performance of the operation, should be invariably stated. And*

every effort should be made to ascertain and record any variations in vision that may subsequently occur.

5th. A definite standard of success should be agreed upon; that is, that fraction should be settled which must be at least equaled by the acquired vision, in order that the result of the operation may justly be regarded as successful.

By an adoption of these or similar rules, it is at once evident that the existing amount of confusion would be greatly reduced, while many sources of mistake would be removed and many apparent discrepancies obviated or explained. Absolute precision, entire accuracy of statement, can of course only be approximated to. Even as in mathematics the exact ratio between the diameter and circumference of a circle can be sufficiently approached though never precisely attained, so the gradual elimination of error after error from our statistical tables will in time lead to results so full of truth that their slight imperfections may practically be overlooked.

REMARKS ON CATARACT EXTRACTION—SUGGESTIONS FOR SECURING GREATER PRECISION IN REPORTING OPERATIONS AND RESULTS—FORM OF THE CORNEAL SECTION. By John Green, M.D., of St. Louis, Mo.

It is evident from the discussions of the past year or two, that the majority of ophthalmic surgeons are not yet satisfied with established operations for cataract extraction, but are still busy devising and testing new methods. With the exception of those operators who still adhere more or less closely to the "peripheric-linear" method of von Graefe, we now find but few exclusive advocates of any particular operation. Methods and modifications of methods, variations in the details of the operation and in their combination, have become so numerous as already to defy nomenclature; general statistics, therefore, classifying operations under a few heads, according as they happen to resemble, more or less closely, some established or well-known method, are no longer sufficient for purposes of comparison; but we require instead, from each operator, a methodical record of all extractions performed, together with a precise indication of the manner in which each essential stage of each operation has been conducted. Thus, and thus only, can we hope to secure records which shall afford data for definite conclusions as to the advantages and disadvantages of particular modes of procedure.

In recording and tabulating our cataract extractions, we should note, in each case, the exact form, extent, and position of the corneal section; the character and extent of the iridectomy, if iridectomy has been performed; the manner of opening the capsule or otherwise dealing with it; and the measures

adopted for facilitating the exit of the lens. We should also record in detail any complication or defect in the completed operation, and in the immediate result of the healing process; and in estimating the final result, we should, in addition to giving the measure of the acuteness of vision, be careful also to detect and note any irregularity in the healing of the corneal wound, any synechia or other irregularity of the pupil, any remains of capsule or other pupillary obstruction, and any abnormal condition of the vitreous or of the fundus as shown by the ophthalmoscope.

The record of the form, extent, and position of the corneal section, the character of the iridectomy, and the ultimate form and condition of the pupil may be illustrated by simple diagrams, with the very great advantage of showing these details of the operation and result as they have appeared to the eye of the operator, and so supplementing and correcting defects and inaccuracies of statement. Such diagrams are best drawn upon engraved blank forms, which may be printed in any light color and gummed on the back, like a postage-stamp, for insertion in the case-book. The forms which have suggested themselves to me as most useful are three in number, namely, a front and a profile view of the cornea, and a front view of the iris.

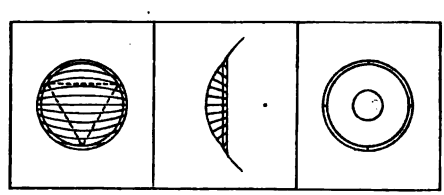

FIG. 1. FIG. 2. FIG. 3.

Figures 1 and 2 represent a front and a profile view of the eye, with great circles drawn upon the cornea; the two concentric small circles indicate respectively the anterior and posterior boundaries of the cornea. Figure 3 is the same as Figure 1, omitting the great circles. Upon these blanks, lines illustrative of the case to be recorded are drawn in ink, the printed lines serving merely as guides to their accurate delinea-

tion and interpretation. To reproduce the diagrams in connection with printed tables of statistics, it is only necessary to engrave them in very fine or dotted lines, with heavier lines to mark the course of the incision, etc. This can be most easily managed by lithography, by transferring any desired number of the engraved blanks upon a fresh stone and mark-

even this, as it is described and figured, appears to be a low flap rather than a strictly linear cut.

It would seem, therefore, that much that has been written about great-circle or linear incisions has been based upon operations in which the actual section has been a small circle or flap. Each of these two forms of section has its especial advantage and disadvantage. The great-circle cut opposes greater resistance to the exit of the lens, but, for the same reason, it tends to close more perfectly and heal more quickly. The flap incision, on the other hand, lets out the lens more easily, but it does not close so perfectly, and is therefore longer in healing. The ideal form of section would seem to be not quite a great circle, but rather such an approximation to a great.

adopted for facilitating the exit of the lens. We should also record in detail any complication or defect in the completed operation, and in the immediate result of the healing process; and in estimating the final result, we should, in addition to giving the measure of the acuteness of vision, be careful also to detect and note any irregularity in the healing of the corneal wound, any synechia or other irregularity of the

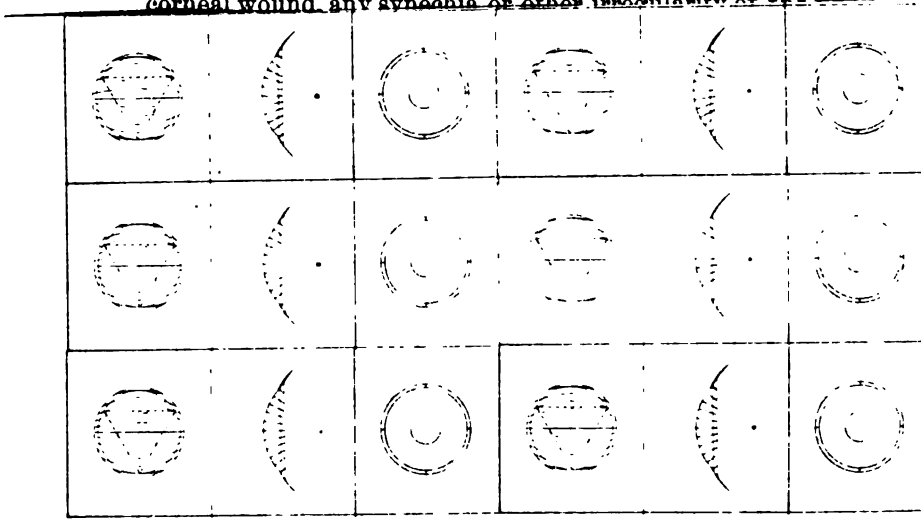

FIG. 1. FIG. 2. FIG. 3.

Figures 1 and 2 represent a front and a profile view of the eye, with great circles drawn upon the cornea; the two concentric small circles indicate respectively the anterior and posterior boundaries of the cornea. Figure 3 is the same as Figure 1, omitting the great circles. Upon these blanks, lines illustrative of the case to be recorded are drawn in ink, the printed lines serving merely as guides to their accurate delinea-

tion and interpretation. To reproduce the diagrams in connection with printed tables of statistics, it is only necessary to engrave them in very fine or dotted lines, with heavier lines to mark the course of the incision, etc. This can be most easily managed by lithography, by transferring any desired number of the engraved blanks upon a fresh stone and marking in the heavy lines with the pen.

This use of diagrams to illustrate reports of extractions has been suggested by a model which I have found useful in studying and demonstrating the various corneal sections which have been proposed, or which may be proposed. The model consists of a sphere upon which two concentric small circles are painted, indicating the anterior and posterior boundaries of the cornea; two intersecting meridians made of stiff wire, which may be applied to any part of the surface of the sphere, afford the means of drawing great circles at will, and of testing experimentally any arcs which we may draw upon the surface of the cornea. Upon such a sphere we may measure off and lay out with the greatest accuracy any described corneal section, and immediately test it by applying to it the movable meridian.

Testing in this way the various sections hitherto proposed, it is easy to show that, with the single exception of the *Querschnitt* of Küchler, not one coincides exactly with a great circle of the cornea. Liebreich's modification of Von Graefe's section conforms perhaps most closely to a great circle; but even this, as it is described and figured, appears to be a low flap rather than a strictly linear cut.

It would seem, therefore, that much that has been written about great-circle or linear incisions has been based upon operations in which the actual section has been a small circle or flap. Each of these two forms of section has its especial advantage and disadvantage. The great-circle cut opposes greater resistance to the exit of the lens, but, for the same reason, it tends to close more perfectly and heal more quickly. The flap incision, on the other hand, lets out the lens more easily, but it does not close so perfectly, and is therefore longer in healing. The ideal form of section would seem to be not quite a great circle, but rather such an approximation to a great

circle as shall render the exit of the lens easier, without at the same time too greatly retarding the first closure of the wound, and the reëstablishment of the anterior chamber.

A very simple relation exists between the several measurements of the cornea and lens which may serve as a convenient guide to the accurate execution of sections like that of Liebreich. Taking the measurements of the cornea and lens as given by Arlt, (*Archiv für Ophthalmologie*, 1857,) we have for the anterior diameter of the cornea, 5‴; for the diameter of the anterior chamber, $5\frac{1}{2}'''$; and for the diameter of the lens, a little more than 4‴. Now the length of the chord of a corneal arc of 120° (or the side of an equilateral triangle inscribed in the transparent cornea) equals $\sqrt{3r^2}$ or $4\frac{1}{2}'''$, and by making both puncture and counter-puncture in the sclero-corneal zone, we may secure a length of available section somewhat exceeding $4\frac{1}{2}'''$, which in this position appears to afford ample room for the extraction of a large and firm lens. This relation is indicated in Fig. 1 by the dotted triangle inscribed within the circle of the cornea.

[NOTE.—The stamps, represented in Figs. 1, 2, and 3, may be advantageously used in connection with the form for recording statistics of cataract extractions lately adopted by the American Ophthalmological Society. A specimen sheet is furnished with this volume of the Transactions.]

LIEBREICH'S EXTRACTION OF CATARACT.—DISLOCATION OF LENS, AND FAILURE TO ESCAPE.—REOPENING OF WOUND NINE DAYS AFTER.—EXTRACTION OF LENS.—GOOD RESULT. By D. B. St. John Roosa, M.D.

The following case presents, I think, some curious features, that may make it worthy a recital to the Society. Mrs. Van P., æt. 62, was operated upon by me for cataract of the right eye, in the fall of 1872, with the final result of V.=$\frac{20}{100}$. On the 29th March, 1873, she was admitted to the Manhattan Eye and Ear Hospital, for the purpose of the performance of the same operation upon the left eye. The patient had submitted to the first operation, without ether, with great coolness and composure, and I therefore decided to attempt the second one also without anæsthesia. Liebreich's section was made, but with some difficulty, due to some extent to the restlessness of the patient. The counterpuncture was made a little more internal to the margin of the cornea than I intended, and consequently the incision was rather small, but I have known the lens to escape readily from quite as small an opening. After incising the capsule, repeated and careful attempts were made to extract the lens in the usual way, and then by means of the hook, but they all failed, until finally the lens became dislocated into the vitreous, and a small quantity of the latter fluid escaped. I then determined to push the lens still farther into the vitreous, which I did and closed the eye. No reaction of any significance followed, and the pupil was found partially clear, and the patient was able to count fingers at a few inches from the eye. On April 7th, or nine days after, the lens had appeared in the upper portion of the anterior cham-

ber, peeping out into the pupil, and I determined to attempt to remove it. The patient was placed under the influence of ether, and the upper lid being held open by my colleague Dr. Loring, I fixed the eyeball with forceps, and with a narrow Graefe's knife I proceeded to open the corneal wound as nearly as possible in the line of the first incision, which was firmly united, lengthening it a very little. I then, by means of a cystotome placed under the lens, brought it out from its position, and from the eye, without losing a drop of vitreous, so far as could be determined. The wound healed, with a slight adhesion of the iris along a part of the corneal wound, and vision $\frac{20}{70}$ resulted, with which the patient was discharged thirty-seven days after the second operation.

HERPES ZOSTER OPHTHALMICUS OF THE LEFT SIDE, CAUSING LOSS OF THE CORRESPONDING EYE, AND SUBSEQUENT LOSS OF THE OPPOSITE EYE. By H. D. Noyes, M.D., New-York.

Mrs. A. H., widow, born in England, æt. 50, came to the New-York Eye and Ear Infirmary, March 3d, 1873. She was totally blind and in feeble health. Eighteen months before, while in England, she had an attack of violent neuralgic pain in the left side of the head and face, attended by an eruption of herpes. The skin was much swollen, and the inflammation raged so severely that she was kept a month in bed. During the progress of the disease, the left eye became inflamed and totally blind. In June following, that is, ten months afterward, the other eye became painful and inflamed and vision was destroyed. There was no attack of herpes on this occasion.

Present condition is as follows: All the left half of the forehead is covered by deep cicatrices of the skin, as if the tissue had been burned. The eyebrow has been partially destroyed, and some scars can be found in the scalp. Some scars exist on the side of the nose, showing that the eruption had occupied this situation. There is partial anæsthesia of all the scarred surface, and occasional attacks of neuralgia now take place in it.

Patient says that she was always myopic. In the left eye, there is no perception of light, the pupil is occluded, and the picture is that of old irido-choroiditis.

In the right eye, which became sympathetically diseased, there is quantitative perception of light, but no projection of a candle flame upward or inward. Tension normal. The

lesion consists in irido-choroitis, and consequent cataract. The globe is sensitive to pressure, while the cornea of the left eye is in a state of almost perfect anæsthesia.

The above case is remarkable for the destructive results of herpes zoster ophthalmicus, in causing directly the loss of one eye, and remotely the loss of the remaining eye. The disease was attended by such violent neuralgic symptoms that no doubt could be entertained that the essential pathology of the case must conform to the usual fact, namely, organic lesion of the ganglion of Gasser. The evidences of implication of the trigeminus nerve were perfectly distinct and palpable.

In the tabulated cases of Hybord, ninety-eight in number, no case of loss of sight in both eyes is related. (For a *résumé* of the paper by Hybord, see *New-York Medical Journal* for June, 1873, p. 642.)

TWO CASES OF HERPES ZOSTER OPHTHALMICUS DESTROYING THE EYE. By B. Joy Jeffries, M.D., Boston, Mass.

1st Case.—March 14th, 1873, a man, æt. 52, applied to me, from whom and his wife I obtained the following account. Thirty-four days ago, he noticed his left eye a little bloodshot, and his forehead, eyelids, and side of his nose became red, and "awfully swelled" within the next two days. The parts were very painful, and he had intense "neuralgic" pain over his head on the left side. An eruption appeared, which left scabs, lasting two or three weeks. He insists that he had no sleep for the first week, and has had no good rest for three weeks. He presents all the appearance of a man exhausted by a severe attack of ophthalmic shingles. There are still some crusts up to the hair, also on the nose and lower lid; one on the brow, over the exit of the frontal nerve. There is pain all over the scalp on the left side, although but little blush of the surface. Patient can not distinguish any difference of sensation on the two sides. The upper lid is swollen and droops a little over the lower. The man can not open this eye. The globe is injected, and the cornea looks badly inflamed and infiltrated. A four-grain solution of atropine was ordered, and quinine freely. March 22d, 1873, there is still some pain over the forehead. The cornea is sloughing in parts. March 26th, the cornea has opened with an irregular slough, and the aqueous flows off. No pus runs, and no pain. April 11th, 1873, the cornea has healed with a flattened cicatrix. No pain. 19th, cornea flat, less irritated. Vision a "white cloud." 25th, the same. The quinine and atropine have been continued. May 2d, 1873, less pain in head. The patient feels it in cold weather. May 9th, 1873, no pain now. Continue quinine.

2D CASE.—Mrs. Blank, æt. 64, states, for several years she has had frequent headaches in the morning. Commencing at least ten days and nights before Sunday, September 8th, 1872, she had neuralgic pain of steadily increasing severity, confined entirely to the right side of the head. On Wednesday, the 11th, her physician was called and prescribed hot applications. An eruption appeared during the following two or three days, over the scalp, forehead, and side of the nose to the tip, on right side. This eruption, when out, was called erysipelas. Nothing was applied to limit it. The eruption was all out by the end of a week. The patient was relieved of the hard pain when it appeared. Crusts then formed, one on the forehead, over the exit of the frontal nerve. The crusts came off by the end of a week, but re-formed. The right eye seemed greatly affected, the lids so swollen as to close it. The symptoms were so bad that by the following Sunday a solution of nitrate of silver was ordered, one drop to be used at a time. As this solution did not seem to be of benefit, it was made stronger. The globe was not so painful, but the lids secreted. Her physician said the eye "was like a ball of blood." The stronger solution was used a week, but the patient complained of its being too painful, and a zinc wash was substituted. She could see for the first few days, but by the second Sunday after the commencement of the attack vision was gone. These statements were definitely given, and corroborated by her daughter, bringing her to me, October 4th, 1872.

The patient then presented a person weak and feeble, evidently worn out with pain consequent on a severe attack of herpes zoster ophthalmicus, in the right side, marked traces of which she now bore. The whole affected surface, namely, scalp, forehead, and side of nose, was intensely red. A large crust still remained on the scalp in front of the vertex. Reddened scars showed where other crusts had been. The patient was still suffering from considerable pain. The right eye was tender to touch, through the lids. Ciliary redness, and a large central slough of the cornea, stained with nitrate of silver. There was marked sympathetic irritation of the other eye, so that enucleation was thought of, somewhat prevented by the

patient's weak condition. A solution of atropine, grs. iv. to ℥j., was applied to the eye several times a day, the patient kept quiet, and quinine given freely. Her general condition at once improved. By October 7th, the upper margin of the cornea was seen and the pupil behind, the anterior chamber existing. Ten days later, the symptoms were somewhat better; the light can now be more freely borne by the left eye, previously extremely sensitive. She complains of neuralgic pain of peculiar character, "prickling," and "stinging of bees." The patient went home, a short distance from the city, in greatly improved bodily condition.

November 5th, 1872, I saw her again. The last crust, from near the vertex, came off to-day, about two months from commencement of disease. The peculiar numbness complained of has now disappeared. There is, however, a difference of sensation; namely, a loss of it over the affected parts. There is still a redness and blush over the skin. The left eye is again more sensitive to light than when she went home. She attributes it to taking cold, that special day, in the cars. The globe does not present so much ciliary redness. More than half the size of the cornea, there is a circular, central crust, exactly the appearance of the incrustation round the mouth and stopper of a vial long used for solution of arg. nit. It has a dry, dull, metallic lustre, and quite opaque, and looks as if the sloughing substance of the cornea had united with the silver. Above, there is a clear enough ring of the cornea for the patient to count fingers through. There is some anterior chamber, but the aqueous evidently drains through this silver crust.

November 22d, 1872, eleven weeks after the commencement of the attack, I again saw the patient, who still complains of some soreness over the scalp and eyebrow. This soreness is growing less. She repeats, it is not pain, but "soreness in the skin." There is yet a blush over the surface. The left, unaffected eye she can use better. The right has darting pains. The cornea looks worse than November 5th, as if slowly sloughing away. There is no anterior chamber, and vision is gone. It looks as if the scale of crust would slough off. I have not seen the patient since.

In my Boylston Prize Essay on Diseases of the Skin, published two years ago, I said, in reference to herpes zoster: "New facts about it are, that it has been now seen on all the different regions of the skin, from the head to the feet, on the inside of the nose, and on the tongue. It has been noticed to occur repeatedly in the same individual. It not very unfrequently appears on both sides of the body at the same time, and then, perhaps, not over corresponding nervous tracts. It affects one side of the body as often as the other. It is more common in April, May, October, and November. It may occur as early as ten, seven, or five months; is not uncommon in children. It may be accompanied or followed by paralysis. It may leave lasting or permanent neuralgia, and that of an intense character. It may be followed by dangerous sloughing, and finally, in the aged, it may cause fatal prostration. When affecting the ophthalmic nerve, it has naturally attracted the attention of ophthalmic surgeons, who have especially studied it, and report that it may greatly injure or destroy the eyeball."

The reports since published give this curious disease a still worse reputation. Dr. Weidner reports a fatal case in the *Berliner klin. Wochenschrift*, Jahrgang 1870, No. 7. Prof. E. Wagner, another in the *Archiv der Heilkunde*, Bd. 11, 4 Heft, 1870, p. 321. Prof. Oscar Wyss, of Zurich, a third, in the same Archiv, No. 12. This last case was most carefully dissected by Prof. Horner with Prof. Wyss. Death occurred during the attack of ophthalmic shingles, from œdema of lungs, due to the extensive purulent deposit causing possibly capillary embolus from the detritus, fat, etc., originating in the ophthalmic vein.

Prof. Horner said of this case, that the strictly pathological alterations in the eye were of two kinds: one set associated with the herpes zoster, as such, (cornea, iris, and ciliary nerves;) the other due to the phlebitis of the ophthalmic vein. To the latter he joins the considerable extravasation of blood in the choroid and retina, the vessels of which were filled to their utmost.

As long ago as 1861, Barensprung, from his dissections, had asserted that "zoster depends on a disease of the ganglionic

system, and in special cases on irritation of some one of the spinal ganglia or the Gasserian; yet the peripheric irritation of a nerve having ganglionic fibres in it may be followed by a limited eruption of zoster vesicles."

Now, Prof. Horner's dissection, in the case of ophthalmic shingles above mentioned, showed inflammation of the Gasserian ganglion, which, as it were, completes our evidence. Prof. Wyss concludes that his case teaches us "that zoster is a typical disease of the skin, caused by inflammation of the Gasserian ganglion, or of one of the spinal ganglia and the nerve passing through it. Ganglion as well as nerve may be partially affected. [NOTE.—This means not separately, ganglion of itself or nerve of itself, but a portion of the ganglion with its corresponding portion of nerve, whilst the rest of the ganglion and nerve remain intact.] In cases where the whole cutaneous nervous distribution of one branch is not affected by zoster, but only one region of a single branch, then we may assume simply a partial affection of the ganglion and nerve."

As another instance of the destructive and serious character of zoster, I would briefly mention a case reported in the May and June numbers of the *Annales d'oculistique*, 1872, by Dr. Hubsch, of Constantinople. Prof. Hebra, of Vienna, diagnosticated and treated the case as one of chronic herpes zoster. There gradually came on white atrophy of both optic nerves; seen also by the late Prof. Graefe, at Berlin. Furious delirium supervened, and the patient, when last seen, was fast hurrying to the grave, with evident signs of diffuse encephalitis.

Dr. Albert Hybord published, last year, an interesting monograph on ophthalmic zona and the ocular lesions caused by it. He has sketched and analyzed ninety-eight cases, so far reported. The list includes the four cases I have previously given, one of which ended fatally. He concludes: 1st. Ophthalmic zona is an herpetic eruption developed over the territory of the first branch of the trigeminal. 2d. Ocular alterations coëxist with the cutaneous eruption, the most important of which are keratitis and iritis. These may exist together or singly; keratitis more frequent than iritis. 3d. Zona is the cutaneous expression of irritation or inflammation of distinct parts of the nervous system, (mixed nervous trunk, sensitive

trunk, spinal ganglion, posterior sensitive root, posterior columns of the cord.) 4th. Ophthalmic zona is the cutaneous expression of irritation or inflammation of the first trigeminal branch. The process causing the eruption may be developed in the Gasserian ganglion, or in the track of the ophthalmic branch. 5th. The lesions of the cornea and iris belong to the same class of phenomena as the cutaneous; they are due to irritation or inflammation of the ciliary twigs of the nasal branch of the ophthalmic division. Most often they correspond to the distribution of the eruption in the cutaneous territory of the nasal nerve. 6th. The cutaneous eruptions and the ocular lesions are not dependent on the paralysis of the vasomotors and consecutive neuro-paralytic hyperæmia. They must be referred to the direct influence of the nervous system on nutrition. Of all the theories suggested, the one seems most satisfactory and simple which attributes these trophic troubles to irritation of the trophic nerves.

To return now to the two cases of ophthalmic shingles I have reported above. In one, I have the direct testimony of the attending physician; in the other, that of the patient and daughter, that they were thought to be erysipelas. The nitrate of silver solution used in the one case could, of course, only add to the patient's pain and discomfort, if it really did not cause the loss of the eye. The eye was properly treated in the other case, by solution of atropine. Though zoster has now been repeatedly reported double on other portions of the body, no unfortunate creature has yet been seen with double ophthalmic shingles. We could wish an enemy nothing worse. Since Mr. Hutchinson, in special, wrote about this disease, cases have been apparently more often seen. This is because it is now recognized, and not so likely to be mistaken for erysipelas, with which, of course, many cases must have been formerly classed. I regret not being able to add something satisfactory in reference to treatment of the disease, or our means of controlling the lasting or permanent neuralgic pain following an attack. As this is passing through the press, I have under my care another extremely interesting case where remedies have afforded very great relief.

TRAUMATIC RUPTURE OF THE CHOROID, WITHOUT DIRECT INJURY OF THE EYE. By B. Joy Jeffries, M.D., Boston, Mass.

A young man, æt. 19, in September, 1871, was running into a barn, when his forehead struck a projecting timber, by which he was stunned. He was not, seemingly, much injured, the effect of the blow soon passing off. On the third day subsequent, he noticed "black specks before the left eye." For instance, as he was shooting on the beach, he imagined a flock of birds coming from the distance. For a month or two after this, he "could not tell a horse from a dog," and then could distinguish a portion only of an object. He judges his sight, in this respect, was worse than now. There are now, March 3d, 1872, no cerebral symptoms. No muscæ volitantes. Externally the eye looks perfectly healthy, and the media are clear. His field of vision, as taken by my register, would require a cut to be here given.

Search being made with the ophthalmoscope, disclosed an, at first sight, quite healthy fundus and nerve. With the direct or upright image, however, there were seen two peculiar white, brilliant crescents, as choroidal scars, up and out from the nerve. Without my being able to say that the retina was detached or plicated, it certainly had in this region, including the crescents, a peculiar, glistening look, like a reflection from a brilliant, rough surface; toward the macula, also, the choroidal vessels could be seen, although with difficulty. The possibility of a separated retina having subsided, was suggested.

THE CAMERA LUCIDA APPLIED TO THE OPHTHALMOSCOPE. By Henry D. Noyes, M.D.

For the purpose of facilitating the execution of sketches of the fundus oculi, I have sought the aid of the camera lucida, and, after a variety of failures, have, by the help of Mr. Grunow, microscope maker, of New-York, succeeded in making it available.

It is needless to relate the contrivances which proved unsuccessful, and I will briefly describe what Mr. Grunow has made for me:

I have employed a mirror of 13″ focal length and 3″ diameter, mounted on a sliding brass stem, capable of swinging at any angle. To form the inverted ophthalmoscopic image, I use a biconvex lens, similarly mounted, of 6″ focus and 4″ diameter.

The mirror is placed at 13 inches from an argand burner, and about 4 feet from the patient; between the gas-light and the patient a screen is placed to protect his eyes and the aerial image from direct rays of the light.

The arrangement is precisely that modification of the usual way of showing the inverted image in fixed ophthalmoscopes which Mr. Carter, of London, adopted. Its essential quality consists only in using a mirror of large diameter and a lens of long focus.

The camera lucida is a bit of glass shaped after Wollaston's suggestion, so as to give two total reflections, and thereby the image is made to appear erect. The size and form of the prism are represented in the cut.

This is inclosed in a box of thin metal, blackened, and is held in place by means of a tube attached to it which is thrust

into the central hole of the mirror. It projects thus in front of the mirror, and of course destroys a small amount of reflecting surface.

The paper on which the drawing is to be made lies on the table in front of the mirror, and is tipped up at such an angle as to present a plane parallel to the exposed lower face of the prism. It is within easy reach of the hand, and permits the tracing to be done with the same facility as if it were looked at in the usual way.

The pencil-point and paper are, by the prism, projected into the air with a perpendicular plane which coincides with the aerial image of the fundus oculi. In this way, the tracing-point is carried rapidly over the lines of the vessels and the contour of the nerve, and the exact relations and size and number of any pathological appearances are designated with certainty. To do this to better advantage, it is desirable to be able to vary the degree to which the paper and pencil are illuminated. A mirror of 7″ focus and 3″ diameter is placed near the gas-light, and made to reflect upon the paper at will. When the pencil-point can only be dimly seen because of the brightness of the ophthalmoscopic image, the second reflector, which is at the observer's left hand, at once floods it with light and brings it out clearly. On the other hand, if the image is feeble, the pencil must have only a corresponding degree of light.

Of course, in working with this apparatus the patient's pupil must be fully dilated, and it is indispensable that he be capable of fixing with perfect steadiness for a minute or two upon a certain spot.

In all fixed ophthalmoscopes the adjustment of the instrument and of the patient is troublesome. A rest must be provided for the patient's chin and head, and to get a clear image undisturbed by reflections is often a perplexing task, but a little practice secures it. To enable the observer to make slight motions in the position of the objective lens, a wooden rod is attached to it, which lies on the table.

An object must be provided for the patient to fix his sight upon, and this may be a bit of white card, a small taper, or any convenient thing.

The practical difficulty in this matter is, to keep the pa-

tient's eye absolutely fixed for one to three minutes, so as to get the sketch in at one sitting. I have found some trouble in this respect, but have not yet had much experience with the apparatus on the human eye. To make a sketch upon a working model of the eye, such as Nachet makes for teaching the use of the ophthalmoscope, is perfectly easy. The main purpose of the camera lucida is, to get the general outlines and correct relations of parts to be depicted; and the rough drawing thus obtained serves as a guide in subsequently filling up a more perfect sketch. If a large picture be desired, this can easily be drawn with the original outline as a model.

AN INSTRUMENT FOR THE DIAGNOSIS OF THE REFRACTION. By Dr. W. Thomson.

In the Transactions of this Society for 1870, will be found a description of an instrument for the determination of the refraction, consisting of four brass disks, variously perforated. To a fifth disk, which combines many of the advantages of the entire instrument, but which is especially suited for the diagnosis and correction of astigmatism, your attention is now invited.

This consists of a disk of thin brass, 1½ inches in diameter, which can be placed in the trial-frames in general use, having, in its central part, ten perforations ½ mm. each in diameter, and ½ mm. apart, arranged in the form of a cross whose vertical stem is composed of six and its horizontal arms of five apertures. A scratch across the face of the disk, in a line with the stem, enables it to be placed at any angle in the trial-frames, so that the stem may correspond with any meridian of the cornea, and the arms with the meridian at right angles to it. The test object should be a small bright point of light at a distance of not less than sixteen feet from the patient, whose accommodation, when an accurate diagnosis is desired, should be entirely paralyzed. To an ametropic eye, free from astigmatism, the test light will be multiplied and will assume the form of a cross, and by passing a card in front of the disk, so as to cover seriatim the apertures forming the cross, we can distinguish myopia from hypermetropia; since in the former, as the card is moved from right to left, the lights disappear in the same order, whilst in the latter, they are eclipsed from left to right. Furthermore, the cross may be united into a single point by some + or — spherical glass, which will correct the ametropia and give the highest visual power.

When there is astigmatism, a spherical glass may remove either the stem or the arms of the cross, but it will not fuse all of the lights into one point, and in simple astigmatism, when the disk is placed to correspond with the best and worst meridians, the patient will see only a line of lights, a fact which any observer can confirm for himself by the aid of a + $\frac{1}{10}$ cylindric placed in front of the disk over his own eye. For the clinical correction of astigmatism, the meridians of greatest and least ametropia must be carefully ascertained by the circular opening advised by Donders, and the radiating lines introduced by Dr. Green. The disk may then be placed in the trial-frames with the stem of the cross corresponding to one of these, and by passing a card in front of each part of the cross, the refraction of each meridian, whether myopic or hypermetropic, may be separately ascertained. A spherical glass can now be found which will fuse into one the stem, and another the arms of the cross, and the combination of one of these with a cylinder equal to the other, will fuse the lights into a point and give an accurate correction. For example, I have recently seen F. M., age 13, myopic since infancy, and growing worse, whose sight is so defective as to prevent her education. At 6 in., the far point of either eye, she can read only No. 3—Sn=V.=$\frac{1}{6}$. With ophthalmoscope the vertical retinal vessels are seen with a — $\frac{1}{12}$, and the horizontal ones with + $\frac{1}{12}$. With the disk with stem placed in trial-frames at 90°, a light was seen as a cross, which was converted into a vertical series by — $\frac{1}{12}$, and into a horizontal one by + $\frac{1}{12}$, whilst a + $\frac{1}{12}$ ⌒ — $\frac{1}{6}$ cy., axis 180°, fused them all into one point and increased her visual power to $\frac{20}{XXV.}$

T. H., age 25, an albino, is very myopic, being able to read only at four inches; spherical glasses gave her V.=$\frac{1}{12}$ only, and there was so much nystagmus as to render the diagnosis of refraction by the ophthalmoscope impossible. The disk was of great service here, and it was quickly ascertained that — $\frac{1}{10}$ gave a vertical, and — $\frac{1}{5}$ a horizontal series of light, whilst — $\frac{1}{10}$ ⌒ — $\frac{1}{10}$ cy., axis 180°, fused them together and increased her V. to $\frac{1}{4}$. The nystagmus, absence of pigment, high degree of myopia and astigmatism, and low acuity of vision combined to render this case very difficult to diagnosticate, and the disk

above described was found in this instance to give greater precision, and with less expenditure of time, than with any of the other methods of examination at hand.

This simple instrument is, therefore, presented to your attention as a useful supplement to, and in part of substitute for, the more complicated one described at a former meeting.

AN INSTRUMENT FOR TATTOOING THE CORNEA.

By Dr. William Thomson.

Having recently met with two cases of central corneal opacity, where it seemed desirable to reproduce as accurately as possible the appearances of the black pupil, and not being satisfied with the grooved needle which I saw in use at Moorefield, where, in this operation, the commissure, at opening of the lids, was filled with the pigment, and the punctures were made through this stratum, I was led to give a trial to the one presented for your consideration.

It consists of a small steel pen, manufactured by Gillott, and known as the Lithographic Crow Quill, which has been fitted for this purpose, by having its point converted into a cutting surface by rubbing it flatwise upon a hone. Its barrel will receive the ink in sufficient quantity to complete, perhaps, the entire operation, and the pen should be held with its trough uppermost. It may then be made to penetrate the laminæ of the cornea obliquely, and by a slight lifting movement on its withdrawal, a portion of ink will be carried into the depths of each incision. The vision of the operator is not impeded by a quantity of ink overlying the cornea; he can easily perceive the effect of each puncture, and the leucoma may be stippled with as much precision as though it were composed of paper. In the two cases in which it was used, it fulfilled the above conditions, and both operations were followed by very pleasing results.

THE LIGHT-STREAK IN THE CENTRE OF THE RETINAL VESSELS. By Edward G. Loring, M.D.

At the meeting of the American Ophthalmological Society for 1870, I had the honor of reading a paper on the nature of the light-streak seen with the ophthalmoscope in the centre of the retinal vessels. The views expressed in this paper have since met with a good deal of opposition, the most strenuous, if not the most convincing, coming from Professor Nagel, who, in the first volume of his admirable bibliography[1] has felt constrained to allude to my paper as a "tissue of physical impossibilities," and to allege that the "appearances claimed to have been observed were as foundationless as the arguments based upon them."

To this very forcible, if not very courteous, criticism I have nothing to say, except that if the learned professor did not get the effect exactly as it is described in the paper referred to, he could not have performed the experiment in a proper manner; as not only were the appearances "claimed to have been observed" seen by all the members present, but the experiment has since been repeated by many other competent observers, with always the same result.

In the last number of the *Archive für Ophth.*, (B. 18, Ab. 1, p. 113,) Dr. Schneller has again taken up the subject, and publishes somewhat apologetically the results of his investigations, because he believes "that concerning these so simple matters of examination, the greatest possible clearness should prevail."

After a short introduction in regard to the nature of light and reflections in general, Dr. Schneller approaches the subject under consideration by observing that, "from what has

[1] Jahresbericht der Ophth., 1870, p. 208.

gone before, it will be readily inferred that I consider the clear streaks on the retinal vessels to be the image of the source of light produced by means of the anterior walls of the vessel."

This is the old view held by Van Trigt, and formerly by Jaeger, who latterly gave it up in favor of a reflection from the "blood-column."

Schneller now returns to this old view, which he supports by the following "positive proofs," the first of which is, that "the clear stripe is both in length and breadth of the required dimensions," that is to say, it corresponds, mathematically, with what it should, were it actually the reflection of the source of light.

To prove this, Dr. Schneller proceeds as follows: He supposes an examination to be made in the usual way, with two different ophthalmoscopes, the mirror of one having a radius of 44 cm., or, as is more commonly said, a focal distance of 22 cm., or 8½ Paris inches; the other, a radius of 28 cm., or a focal distance of about 5 Paris inches. The source of illumination is at 30 cm., or 11 inches, and is 18 mm., or ⅔ of an inch broad.

Rays coming from this source of light enter the examined eye, after reflection from the mirror, as convergent, consequently they must cross somewhere in the vitreous, and, at their place of crossing, an image of the source of light will be formed, inverted of course, and reduced. The place and size of this image will be proportionate to the distance and size of the source of light and the curvature of the mirror, consequently the result will vary for every mirror used. From well-known formulas, Dr. Schneller calculates for each of his mirrors the size and position of this image in the vitreous and in front of the retinal vessels, and, having obtained this, he then calculates what the size of the image of this image would be as reflected by the wall of the arteria centralis, looking thus on the wall of the vessel as a convex mirror with a radius of curvature for its first division equal to 0.1 mm., for its second 0.07 mm., and for its third 0.05.

Schneller from his calculations obtains as a final result, that the size of the image as reflected by the wall when seen with

the first mirror, the focal length of which is $8\frac{1}{2}$ inches, is $\frac{1}{2.3}$ (or a little less than $\frac{1}{2}$) of the diameter of the vessel.

But with the second mirror, the focal distance of which is 5 inches, the image is only $\frac{1}{6.5}$ to $\frac{1}{7}$ of the diameter of the vessel. That is to say, the light-streak seen with a mirror of 8 inches focal length is three times as broad as when seen with one of 5 inches! This disproportion is certainly startling, and it can be readily conceived that the image in question would speedily become invisible, when mirrors of only moderately short focal lengths were used. This conclusion has not escaped Dr. Schneller, who says, "From the above calculations it is self-evident why, in using mirrors of progressively shorter focal lengths, the light-streak becomes smaller and smaller till it even fades wholly away, and why in myopia it is smaller, and in hypermetropia it is broader than usual."

In answer to this first positive proof, I would say that it does not appear to me that facts bear out the conclusions, for the light-streak certainly does not appear to my eye, or any one's else, three times as broad when a mirror of 8 inches focal length is used as with one of 5.

Imitating precisely the same conditions used by Schneller, I get identically the same breadths of the light-streak, whether I use a plane, a moderately convex or concave mirror, that is to say, up to a focal length of 3, or even $2\frac{1}{2}$ inches.

Of the concave mirrors which I used, one had a focal length of $1\frac{3}{8}$ inches, another, one of only $\frac{7}{8}$ inches. With either of these mirrors the light-streak can be plainly seen. I must remark, too, that the illumination of the bottom of the eye with mirrors of such short curvature is exceedingly difficult, and can only be done satisfactorily when the eye is under atropine; for, on account of the great condensation of light by the strong concave surface, the pupil contracts violently and excludes a large amount of the rays.

The reason then why, when we use the stronger concave mirrors, we see the light-streak less plainly, is due to the fact that, when the rays cross each other at a considerable distance in front of the retina, the cone of light when it reaches the retinal surface has an ever-increasing base, and the rays an ever-increasing divergence, the more anteriorly they intersect;

so that fewer and less forcible rays strike upon the summit of the vessel, and consequently fewer come back to the observer's eye.

That the light-streak is less well marked in myopic eyes, may then be due to two causes: first, that with any given concave mirror the rays must cross each other, owing to the increased antero-posterior axis at a greater distance from the retina than in a normal eye; and secondly, because a great amount of light is consumed by the necessary correcting glass; while in a hypermetropic eye the reverse holds good—the cone is smaller and the rays striking the vessels are less divergent, and, *a priori*, it ought to be, as Schneller says it is, that the light-streak is more pronounced. The general illumination of all hypermetropic eyes is, from well-known optical laws, much more easily obtained and more brilliant than in myopic; but whenever a good general illumination can be obtained, so that the details of the fundus can be seen in perfect sharpness, then, too, will the light-streak be well marked, no matter what mirror we use.

Hitherto we have occupied ourselves with only one of the conditions of the problem, namely, the mirrors; and much more might be said in regard to them, but want of space forces us to another equally important factor, the source of illumination.

According to optical laws and to what the author himself lays down, the size of the image in the vitreous must vary with the position of the source of light, and consequently the size of the light-streak which depends upon this would also vary. The further the lamp was removed from the mirror, the narrower, and the nearer it was brought, the broader, would the streak become.

If now we take a seven-inch mirror, and make the ophthalmoscopic examination in the ordinary way, but move the lamp back and forth while the eye is always fixed on the vessel, which can be most readily done with the jointed lamp which most of us have in our offices; if we do this, we find that from the farthest extension of the lamp up to its nearest approach, there is no perceptible change in the breadth of the streak. If we repeat the experiment, except that we put the lamp at fifteen, or even twenty feet, we find that we still

get the light-streak in very nearly the same, if not the identical dimensions, as when the lamp was at one, instead of fifteen feet.

It is a little difficult, with the light at this distance, to get a proper illumination of the fundus, but with a little patience it is readily enough obtained, though the circle of illumination is, of course, very small in diameter, since the rays cross each other so far forward that the external rays of the cone strike the retina at such an angle that they are not reflected back; so then they enter the eye of the observer. It is only the most central rays of the cone that do this, and this holds good, for precisely the same reason, when mirrors of very short focal lengths are used.

Passing now to the third condition, the size of the source of illumination, we find that we may reduce the breadth of the flame at will, provided this has enough force to throw a circle, however small it may be, of well-defined illumination upon the retina. If this circle is only broad enough to cover a vessel, it is all that is needed.

We have, then, to recapitulate a phenomenon alleged to depend on three principal conditions: first, the curvature of the mirror; secondly, the size of the source of the light; and thirdly, its distance from the mirror. Now, it is mathematically demonstrable that, if any one of these conditions are changed, the result will be changed; and yet we have fundamentally changed every one of them, some to an enormous extent, and yet the result remains unaltered to any appreciable degree.

It is therefore proved *experimentally*, that the effect can not be due to regular reflection of the source of light from the anterior wall of the vessel.

Let us look now at the affair briefly in a mathematical point of view.

Schneller takes the diameter of the central artery of the retina, upon the authority of Henle, as 0.28 mm., and deduces from this that the first division of the vessel would have a radius of 0.1 mm., and a diameter of 0.2 mm.

I have already stated that the light-streak could be readily seen when the source of illumination was at a great distance,

and, assuming with Schneller that the radius of the first division is 0.1, I have had the curiosity to calculate what the size of the image would be as cast by the anterior wall of the retinal vessel, when an ophthalmoscope of seven inches focal length was used, and when the flame of the lamp was 23 mm. ($\frac{9}{8}''$) broad, and placed 20 feet behind the observed eye.

Rays coming from the lamp at this distance are practically parallel, and after reflection from the mirror, would meet, if uninterrupted, at its principal focus.

Intercepted, however, by the observed eye, the nodal point of which we will assume to be at one inch from the mirror, the rays will enter the eye as convergent, and the degree of their convergence will be precisely the same as if a biconvex glass of seven inches focal length occupied the place of the mirror, and the lamp was twenty feet in front of the glass.

As the rays enter the observed eye as convergent, they would meet in the vitreous, in front of the retina, and the eye which brought such rays to a focus on its retina, would have to be hypermetropic, and the degree would be equal to the glass used, minus the distance from the nodal point. In this case it would be $\frac{1}{7}-1=\frac{1}{6}$. H. $\frac{1}{6}$ equals a shortening of the normal axis of the eye of 1.6 mm. Consequently the image of the flame would be 1.6 mm.[1] in front of the retina, and the size of the image would be to the size of the flame as their respective distances from the second nodal point of the eye. The distance of the lamp is 20 feet, or 6504 mm. The size of the image would then be to that of the lamp as 15 mm. is to 6504 mm., or, expressed as a decimal, .002 that of the flame; and as this is 24 mm. broad, the actual size of the image in the vitreous would be 0.048 mm.

We have now, having obtained this, simply to calculate the place and size of the image of this image as reflected by the anterior wall of the vessel, the radius of whose curvature is 0.01 mm.

The place where this image would lie is obtained by the for-

[1] For formulas by which this is calculated, see Mauthner, pp. 67, 226, Ab. 1. Knapp's Archives, V. No. 2, p. 377. American Journal of Medical Sciences, April, 1870.

mula which Schneller uses: $\frac{1}{f'}=-\left(\frac{2}{r}+\frac{1}{b}\right)$ in which f' is the required distance of the image behind the curvature of the vessel, and b, the distance of the first image in front of the retina; that is to say, 1.6 mm. According to the above formula, the image would lie then 0.048 mm. behind the apex of curvature of the anterior wall of the vessel, and the size of this image would be to that in the vitreous, as their respective distances from the surface of the wall, that is, as 0.048 is to 1.6 mm. And as the size of the image in the vitreous is 0.048 mm., that of the vessel wall would be 0.00144 mm. Now as the diameter of the vessel, according to Schneller, is 0.2 mm., the light-streak, under the conditions taken, would be only $\frac{1}{139}$ of the diameter of the vessel.

The above figures, 0.00144 mm., give the actual size of the image of the source of light; but as we see the bottom of the eye under an enlargement of 15 diameters, we must multiply this by 15 to get the size of the image as it would appear to us: $0.00144\times15=0.021$ mm. This, as can be readily conceived, would be invisible to the naked eye. And if this is so with the first division of the vessel, what would it be with the third? And yet, the light-streak, as any one can convince himself, with the conditions taken is not only not invisible, but is to be seen under pretty nearly the same aspect as in the ordinary ophthalmoscopic examination.

It must be borne in mind, however, that the circle of illumination on the retina will be here as it was with the mirrors of short focal distance, exceedingly small, and for this reason a little care and skill will be required to get the effect.

There are three other positive proofs, in regard to which I should like to oppose some objections, did not want of space forbid. Turning then from what is purely mathematical and deductive, to what is really positive evidence of the author's views, we come to the following experiment.

"A glass tube, says Schneller, (*loc. cit.* p. 118,) filled with a solution of carmine, upon which the reflection of the flame has been cast by an ophthalmoscope, shows when the rod is perpendicular to the line of vision, a glittering stripe, which moves in the same sense with the image of the flame. If the

eye of the observer is moved sidewise from the ophthalmoscope, then a second stripe comes into view, of a dull reddish color, which moves in an opposite sense to that of the flame. The former is the reflection of the source of light from the anterior, and the latter that from the posterior wall of the cylinder. Both fade away when the tube is inclined from the plane which is perpendicular to the line of vision, the more diffused image from the posterior wall somewhat later than the other. If a reflector is now placed behind the tube, so as to form a contrasting background, say a piece of white, blue, or (what corresponds to the fundus of the eye) brownish-red paper, then the tube seems to be uniformly illuminated; still, when it is held in the right position, both of the above-mentioned reflections can be clearly seen."

"If the tube be a little inclined, and the streaks of reflection in themselves be weak, then the background is less concealed from view, and so clearly shines through, that printed matter, lying behind the tube, can be read. From which it follows that the ordinary solutions of carmine are more transparent than blood; and this is the reason why Loring saw the hole of the mirror which he used as a background, clearly defined."

The whole point of my experiment is so hopelessly buried in his last sentence, that we will not stop to resurrect it, but pass at once to those points which Schneller in his experiment brings forward to prove his part of the question. These are the reflections from the anterior and posterior walls of the tube.

Both of these reflections were noticed and commented upon when my paper was presented to the society, and they should, no doubt, have been dwelt upon when it was published, but they were discarded from playing any important part in the formation of the light-streak, on account of physical laws, which seemed at the time to preclude such a possibility; that is to say, the simple laws which govern reflections when light passes from one medium into another.

These views can not be better illustrated than by repeating the experiment performed by Schneller, which is similar to my own, with the important modification that instead of using behind his tube a highly polished surface, from which there is a large amount of regular reflection, he uses a piece of paper,

from which there is very little or none. In fact, his experiment is a precise counterpart of the one I made to refute the very thing which Schneller now tries to prove by it. It is but a repetition of my "Cylinder B."

Suppose then, a bit of small glass tube to be filled with a solution of carmine, and that this is placed against a background (slightly removed, however, from it) of white paper.

If now we cast the light of a flame against this tube with the ophthalmoscope, we get, as we should naturally expect, a glittering streak, corresponding to the apex of the curvature of the tube. This, as you are well aware, is the image of the source of light, and the same general effect is produced, whether we throw the light upon the tube with the ophthalmoscope, or allow the flame of the lamp to strike directly upon it. If then, for the sake of convenience, we expose the tube at the proper angle to the light of the single burner in the chandelier overhead, we get the same glittering streak along the vertex of the vessel.

In both cases this is unquestionably the image of the source of light; hence, argues Schneller, that in the centre of the vessel must be the same, and this would certainly be a strong argument in its favor, were the conditions the same in regard to the tube as to the retinal vessels. But it strikes me that these are widely different; for in the case of the tube we have the light passing through air, which has an index of refraction of 1, and striking against a curved surface of a medium, the index of refraction of which is 1.6, if the tube, as is commonly the case, is made of flint, and 1.533, if of crown-glass.

The difference here between the indices of refraction is very great, and we should *a priori* expect a brilliant reflection.

But the retinal vessels are not surrounded by air, but by media, the indices of refraction of which are almost identical with that of the wall itself. Indeed, the blood, the vessel-wall, the retina, and hyloid membrane, are all contained between an index of 1.34 and 1.35, a difference of only 0.01, and on top of these comes the vitreous, with an index of 1.339.

Under these circumstances, we should not *a priori* expect any reflection at all from the wall of the vessel, certainly not so

broad and brilliant a reflection as that under discussion. And if this is true, then we ought not to expect one rom the glass tube, which is a sufficiently exact representative of the retinal vessel, when this is subjected to the same conditions that hold good in the eye. It is impossible to imitate in any adequate manner the wonderful and complex mechanism of the eye, but a sufficiently exact imitation can be got of the conditions which govern the phenomenon under consideration, in a very simple manner: we have only to surround the glass tube by a medium which differs slightly from it in its index of refraction. From many fluids which might be used for this purpose, I select for the present experiments, solely as a matter of convenience, chemically pure glycerine, which has an index of refraction of 1.473.

If we now put the bit of tube with its white background—and I should have stated that in this case the tube itself is filled with glycerine stained red with carmine—if we place this in some proper receptacle, such as a shallow cup or capsule, such as sections of eyes are mounted in, and then expose the tube to the light so as to get, just as we previously did, the brilliant streak running down its centre, and then while we keep the eye fastened upon this, we pour the glycerine gently into the vessel, we see that the streak maintains all its brilliancy and integrity, while the fluid is gradually mounting up the sides of the tube; but the moment it reaches the vertex, and flows over the tube, that moment, just as we should naturally expect, the reflection vanishes, totally it seems at first sight, but by the very closest inspection, and by varying the position of the cup holding the tube, we can sometimes catch the faintest ghostlike remains of the minutest dimensions of what was the broad and brilliant streak of reflection running along the centre of the tube.

If we examine the tube, now covered with glycerine, with the ophthalmoscope, which can be easily done by placing the lamp below and looking down perpendicularly upon the vessel, the same result is obtained, only in this case there is a *total absence* of the streak of reflection from the wall.

In the experiment the tube represents the retinal vessel, and the glycerine the overlying media. The difference in the

indices of refraction between the two equals 1.60 — 1.47= 0.13, and, if no reflection is produced in this case, it is hardly possible that it could be, when the discrepancy is only .01, or thirteen times less.

A very simple and at the same time very striking exemplification of the above principle, on a larger scale, can be easily had by using instead of the small tube one of the positive cylindric glasses of the common test cases, of eight or nine inches focal distance.

Such a glass, so far as the anterior surface is concerned, may be looked upon as a portion of the anterior wall of an enlarged retinal vessel. If the plane surface of the glass be blackened or covered with dull, dark paper, then we get only the reflection from the anterior surface, and, if we now catch the reflection of the lamp overhead, we then get an image of it of great brilliancy and of sufficient size to be seen in all its detail. If we now pour in the glycerine at the side of the cup, in such a manner that it shall gradually rise over the surface of the cylindric glass, we then see the reflection, brilliant and distinctly defined as it is, fade away like magic the moment the fluid comes in contact with it, and the question is once more pressed upon us with redoubled force—how is it possible that the broad and brilliant light-streak of the vessels can be the result of reflection when the discrepancy in the indices of refraction between the walls and the surrounding media is so very insignificant?

If we use a common bi-convex lens, instead of a cylindric one, and so raise it from the bottom of the vessel that the glycerine will flow under it, we then see the reflection from both the anterior and posterior surface fade away as soon as the glass is covered by the fluid.

Having now destroyed, by the glycerine, the power of reflection from the walls of the tube, it would seem to follow that we had also destroyed the refractive power. But this is not so, and to prove it, we have only to repeat the experiment used in my first paper, and precisely like the one just given, except that behind the tube alpolished surface, an ophthalmoscopic mirror, is to be used, instead of an unpolished one; we have only to take the same bit of tube and place a mirror be-

hind it, the two being slightly separated from each other, and then to pour in glycerine till it rises over the tube. If we now examine the tube with the ophthalmoscope, we find, as before, not the slightest trace of reflection from either of its walls; but the moment we succeed in so casting the light upon the tube, that it shall be reflected directly back to us, that is to say, as soon as our line of vision is perpendicular to the axis of the tube, we see a beautifully marked, broad light-streak running the entire length of the tube, precisely as described in my former experiment.

The only interruption in the streak is precisely where the tube passes over the hole, and here it comes, on either side, to an abrupt ending, the lateral limits of the hole being sharply defined; showing clearly that where there is no reflecting surface behind the tube there is no light-streak. This experiment shows conclusively that here as elsewhere the power of refraction remains after that of reflection has been destroyed; or that, in other words, we still have a considerable amount of refraction where the differences in the indices of refraction are too small to admit of any appreciable amount of reflection; at least, whenever the reflecting surface is perpendicular, or nearly so, to our line of vision.

Schneller and others have laid great stress as an argument in favor of reflection on the fact that the light-streak is only visible when the vessel lies in a plane directly perpendicular to the line of vision. This is precisely the same whether the effect be due to reflection or transmitted light, as can readily be seen from the experiment; for it is only when just such conditions are fulfilled that the streak can be seen, and it requires not a little patience and dexterity, when glycerine is used, to bring the vessel into the required position.

Schneller also lays a good deal of emphasis on the fact that the light-streak is "glittering" and of a "white color," whereas, if it were due to transmitted light, it would be reddish. I can not admit with him that the light-streak is in any sense "glittering," though in the arteries it is certainly oftentimes brilliant, nor to my eyes does the streak ever appear white, but rather of a pale straw color, with the slightest possible pinkish hue in it, while, even as the author

himself admits, in the veins, where the blood is darker, it not unfrequently seems to have a decided reddish tint. This pale straw color, bordering on the color of old parchment, ought not to seem strange to us when we think how very small the actual column of the blood really is, and that in the common ophthalmoscopic examination we see the vessels under an enlargement of thirteen to fifteen diameters, and under so brilliant an illumination.

From what has gone before, the writer is forced to the opinion that the phenomenon in question cannot be due to reflection from the *anterior wall* of the vessel, and that Schneller's views are not tenable, either from a mathematical or physiological point of view. If a reflection at all, this must come, as Jaeger says, from the anterior surface of the blood column. But precisely the same arguments against this meet us as those already urged at length against the anterior wall of the vessel. No reflection that would be visible could be produced here, unless physiologists have been utterly mistaken in the index of refraction of human blood, and it hardly seems possible that two such physicists as Sir David Brewster and Thomas Young could have been mistaken in their estimates. Both of these observers agree in putting the index of refraction of blood at 1.35.

Much that had already been written in support of my former paper has been omitted, because I have preferred to base my defense on actual experimentation. Instead, therefore, of producing any more arguments of my own, to which exception might well be taken, may I be permitted to bring forward one which can not fail to be of great weight with all who have interested themselves with physiological optics, and that is, that Giraud T. Teulon has had the kindness not only to repeat my experiments but to add others of his own invention for the solution of this problem, and that, through these, he has been led to precisely the same conviction that I have?

So far as appearances go, I readily admit that these are against my views, as the light-streak certainly seems, at first sight, to be the product of reflection and not that of refraction, and if there were any way in which the phenomenon of reflection could be reconciled with what we have been taught

to believe were the correct indices of refraction, it would certainly be more natural to attribute the effect to the former than to the latter. But how this can be possible with the accepted indices of refraction of the different media of the eye, I am at a loss to see. If, however, the indices hitherto given by the physicists are wrong, or have been incorrectly taken, then, of course, the foregoing views and arguments are also incorrect.

There is, moreover, one argument in favor of reflection which was originally brought forward by Jaeger, and now repeated by Schneller, which I can not satisfactorily meet, and that is that where two vessels cross each other the light-streak is not interrupted, as a rule, though it occasionally is seen to be when the vessels which cross each other are very small and apparently lie as nearly as possible in the same plane. We do, in this case, get an interruption, the light-streak forming a small quadrangular place at the point of crossing. This, it appears to me, can only be the effect of transmitted light, and the question arises whether the absence of the effect, in case of the larger vessels, may not be due to the fact that they do not cross each other in close contiguity, but are separated by intervening tissue, and, moreover, run at an angle to each other.

If, however, the tissue which lies immediately behind the vessel, and in which the latter is imbedded, could in any way act as a concave cylindric reflector, then the light-streak would not be interrupted when two vessels crossed each other. But to this suggestion, as to all others which have been presented, either by me or others, there are pros and cons which must be finally decided by higher authority.

The above remarks have been written solely as an answer to Dr. Schneller's objections to my former paper, and it appears to me that, although I myself may well be wrong in my views, Schneller certainly is in the demonstration of his, or, at least, that his arguments are entirely insufficient to give that convincing clearness which he seems so desirous of imparting in these "such simple matters of observation." But I must leave the further discussion of this subject to those who have more taste and a greater aptitude for deciding such problems.

I should, however, like to add here a few points connected

with the condition of the light-streak that may be of sufficient clinical importance to deserve mention.

Any disturbance in the media lying in front of the retina, naturally interferes with a perfect illumination of the bottom of the eye, and, inasmuch as the details of the fundus will be more or less obscured, the light-streak will be proportionately affected. Still, when even, on this account, only a moderately distinct view of the fundus can be had, the light-streak on the retinal vessels will be comparatively well marked, allowance being made for the general haziness of the media. But, on the other hand, though the media in front may be perfectly clear, the slightest œdema into the retina will cause the light-streak to be much diminished, or even to vanish entirely. And this takes place even if the œdema is confined to the immediate neighborhood of the vessel, and occupies, so to speak, only the perivascular space. Should the œdema be of any extent, the vessels have no central streak whatever, but present a uniform red appearance. This is markedly the case where the œdema is very pronounced, as it sometimes is in embolism or injuries from blows on the eye or in some forms of acute retinitis.

Without laying too much stress upon it, I have been led to look on this absence or presence of the light-streak as a useful and important sign in the differential diagnosis between troubles in the superlying media, especially in the vitreous, and haziness in the retina itself.

In some cases of overworked eyes, where there has been no other ophthalmoscopic sign, I have often noticed a decided diminution in the brilliancy and size of the light-streak, or even a total want of it, especially in the veins. I have attributed this to some slight impediment in the circulation and a consequent transudation of serum into the perivascular spaces, or tissue immediately surrounding the vessels. I have seen precisely the same thing in patients who have been suffering from some affection of the heart, though I have never been able to trace this, as Becker does, to the single condition of aortic insufficiency. Nor have I, as he does, attributed this reduction in size and brilliancy to the reduced calibre of the vessel; for I have seen cases where the light-streak was entirely

absent, even where the vessels were abnormally distended, and I have then thought it due to the abnormal condition of the blood, or the wall of the vessel or surrounding tissue which interferes with their usual transparency.

I have noticed, too, this disappearance of the light-streak in one or two instances of what afterward proved to be commencing separation of the retina, several days before the actual separation took place; the separation corresponding pretty nearly with the tracts of the retina where the light-streak was absent In one of these cases, the retina readjusted itself and remained applied for some three weeks, and then finally gave way. In another case, where the line of demarkation between where the light-streak was present and where it was not, in all the lower vessels, was well marked, and where, too, there was a corresponding limitation of the field of vision, no separation of the retina took place, and the œdema around the vessels, or what was supposed to be such from the absence of the light-streak, gradually passed off.

In actual separation of the retina, the light-streak is wanting.

I have also observed that the light-streak is absent, in different degrees, however, in many conditions in which the vessels themselves seem to have suffered from inflammatory action, especially in perivasculitis or perhaps inflammation of the wall itself, and where secondary atrophy of the tissue has taken place, with hypertrophy of the connective tissue elements. Thus the effect is often very pronounced in the secondary or atrophic stage of retinitis albuminurica, in those cases where the vessels themselves seem to have been involved and finally to have become reduced slightly in size. In these cases, the light-streak is often very much diminished or even entirely wanting.

Precisely the same thing takes place in some cases of retinitis pigmentosa, and oftentimes in the earlier stages of the disease where the vessels are just beginning to suffer a reduction in size, and where, as yet, the accumulation of pigment in the retina has not taken place to any considerable degree, or even where this is entirely wanting. And moreover, in these cases where the light-streak is absent, it is not universally so, that is, in all parts of the fundus; for it may still be present in all its

normal dimensions and brilliancy in some places, while in others it is much reduced or even wholly absent.

Precisely the same thing occurs oftentimes in those curious cases of retino-choroidal atrophy, occurring especially in old people with atheromatous arteries, and where, in different parts of the fundus, but usually near the macula, well-defined regions exist, which show an absorption of the choroidal epithelium, capillary layer, and pigment of the stroma, to such a degree that the larger vessels seem to be dissected out and to stand in vivid contrast with the adjoining parts of the fundus which still preserve a normal appearance.

I would say here that I do not allude at all to the well-known atrophic patches seen in choroiditis disseminata, or areolaris, where the retina itself is not usually much affected, but to that condition which Jaeger has described (and of which he has given two admirable drawings[1]) as atrophy of the pigment layer of the choroid.

It would appear that this diagnosis is not correct, or at least not comprehensive enough, since simple atrophy of the choroidal pigment layer never in itself produces any great disturbance in vision, as we see in posterior staphyloma, where not only the pigment-layer but almost the entire choroidal tissue has been absorbed. And in all these cases of ordinary choroidal disease, we very rarely if ever see scotoma—never, in fact, unless the retina is affected. But in the cases to which I allude, and in those which Jaeger has figured, we find great disturbances of vision and well-marked scotoma, showing that the retina is implicated, and it is in such cases that directly over and in the immediate vicinity of these circumscribed patches, the light-streak of the retinal vessels is often completely wanting. Through the kindness of Dr. Althof, I was enabled to present a beautifully marked example of this at the last meeting of the New-York Ophthalmological Society. In this case, that of an old woman of some seventy years, the light-streak could be seen perfectly well in some places, while in those parts of the fundus corresponding to the atrophic condition of the patches, it was either very much diminished or entirely wanting. I have also seen this want of the light-streak in some

[1] Hand-Atlas. Taf. xxii. fig. 97; text p. 165.

cases, chiefly among old people, where there was no other ophthalmoscopic sign, but where, from other symptoms, there was reason to believe that the vessels of the general circulation were more or less affected with atheromatous or amyloid degeneration.

So, too, in cases of what looks like simple atrophy of the disk, with shallow excavation, I have noticed this diminution or want of the light-streak, and a closer inspection then always reveals the fact that the fundus has a slightly hazy appearance with delicate changes in the choroid. And I have been led to believe in such cases that the retina itself was affected, and that the nerve-fibre layer especially participated in the trouble which was so plainly marked in the united nerve-bundles in the disk.

Whether in the foregoing and similar cases the above-mentioned absence of the light-streak be due to an abnormal thickening of the vessel-wall itself or that of the adventitia, or to a slightly œdematous condition of the tissue immediately surrounding the vessel, I am unable to determine, but I believe that at times it is due to all of them.

I would add that the light-streak is often of great service in determining the optical condition of the eye, especially in astigmatism; and the differential diagnosis between that want of sharp definition caused by an optical error, and the same effect caused by some abnormality in the condition of the membranes at the bottom of the eye.

A CASE OF SPARKLING BODIES IN THE RETINA.

By George T. Stevens, M.D., Albany, N. Y.

Z. M. is a clerk, twenty-two years of age, a native American, in good health, a full-chested, well-developed man. He onsulted me in May last on account of defective vision and of pain in the right eyeball. He had been conscious of a partial loss of vision for several years. The defect he described as if a feather or vail were hung so as to obscure a portion of the field of vision, while the remainder of the field was clear. He had been suffering from severe pain in and behind the eye for two weeks.

On testing the field of vision, there was found to be a loss of rather more than one fourth of the field, the upper and inner portion of the field being blinded. Opthalmoscopic examination showed the outer and lower portion of the retina to be illumined by hundreds of brilliant sparkling bodies. This exceedingly beautiful appearance was confined principally to about one fourth the retinal surface, though here and there, outside the limits of the greatest numbers, the glitter of solitary points could be seen.

These bodies seemed to be located in the internal (nerve-fibre) layer of the retina, or, possibly, in the internal limitans. None were below the level of the vessels, and many were seen to lie immediately upon the anterior surface of the veins and arteries. The retina, in other respects, revealed no indication of disease.

The facts relating to the history of the case, as communicated by the patient, are as follows:

In the summer of 1867, he was a passenger on board a steamer descending the Mississippi River. He was in perfect health, or, as he expressed it, "never better." While sitting

upon the deck of the vessel, quietly conversing with some friends, he was suddenly seized with a most violent pain in the eye, the shock feeling, as he says, "as though a needle had been driven through the eyeball." From that time he suffered intense pain in the eye for about two weeks; at the end of which time the pain gradually disappeared.

During this time the pain and intolerance of light were so severe that he made no effort to ascertain whether any vision remained.

When the pain at length subsided, he thought the eye well and took no further special notice of it for a year or more. Then, while serving as a clerk in a book-store, he observed that there was a partial loss of vision in one eye. Once after that, he thinks after an interval of another year, he suffered severe pains in the same eye, lasting a fortnight, and at the time of applying for counsel he had also suffered for two weeks. In neither of these latter instances could the pain be compared in severity to the first attack.

He has been a smoker for six years, but has used tobacco very moderately until within two years.

On examination of the heart, the impulse is found to be unusually strong, and, after vigorous exercise, there is slight irregularity. I detect no other evidences of disease of that organ. In all other respects he appears to be in perfect health.

May not the history of the case, and the location of the sparkling bodies, suggest that at the time of the attack of pain on board the steamer there was retinal hemorrhage, that the effused blood lodged in the nervous layer, spreading out in the direction of the nerve-fibres, the effusion thus assuming a sort of pyramidal form, and that after the production of these blood crystals (hæmoglobin or cholesterin) all vestiges of the effusion were removed, except the sparkling bodies?

DEMONSTRATION OF SOME NEW INSTRUMENTS.

By H. Knapp, M.D., of New-York.

The first instrument which I would like to submit to your kind attention is an *improved lid-forceps.* It has already been described by me in the first number of the third volume of the *Archives of Ophthalmology and Otology.* I need not, therefore, here dwell on the description of the instrument. I may say that it has rendered me and my colleagues at the New-York Ophthalmic and Aural Institute good service in various operations on the lids. The modification, which renders the instrument applicable to both eyes, seems to answer perfectly well. One inconvenience of the instrument is, that at its free end, namely the end which is farthest from the insertion of the handle into the plate, the plate yields to the pressure exerted by the lid, thus leaving the corresponding portion of the ring a little too much elevated, which renders the grooving of the fibro-cartilage less easy. This inconvenience is obviated by giving to the free end of the plate a higher level.



The second instrument is a "*hook for the extraction of foreign bodies from the interior of the eye.*" It is a small hook, grooved[1] and roughened at its concave

[1] Note.—The wood engraving wrongly represents the concave surface of he hook dotted. It should be striped.

side, made of flexible silver, so that its curve may be changed according to the requirements of the case. I have used this instrument for years with good results, and have a number of cases on record in which it rendered me excellent service. Those who have had opportunities to remove forei n bodies from within the eyeball, will know how unavailable forceps are for this purpose, the foreign body, in most cases, receding before the instrument, is pushed more deeply into the inner structures of the globe. The best instruments to extract foreign bodies out of the eye, and, in fact, the only available ones, are hooks and curettes. With these, you go behind the foreign bodies and draw them toward and into the opening through which you have introduced the instruments. I may add that in this way I have extracted successfully a number of foreign bodies from the *anterior chamber*, some from the *lens*, and a few from the *vitreous chamber*. Among the latter I may mention the case of a boy, who was seen by several of my New-York brother ophthalmologists. A gun-cap had penetrated the cornea and iris. It floated in the centre of the vitreous chamber, when I saw the case, two days after the injury. I made an opening into the vitreous chamber through the sclerotic, the boy being in the deepest chloroform narcosis; after an unsuccessful attempt with a delicate pair of anatomical forceps, I passed the hook behind the piece of metal and extracted it almost without loss of vitreous. I closed the scleral wound by a conjunctival suture, excised the iris which plugged the original wound, and had the pleasure of seeing an almost perfect recovery take place. The boy, when I examined him last, on July the 11th, that is about two weeks after the operation, had no cataract, no opacity in the vitreous, read with some difficulty Sn 1½, and had a complete field of vision. There was a white scar visible with the ophthalmoscope, at the place where the opening in the vitreous chamber had been made, and some hyperæmia of the disc and its vicinity, where the foreign body probably had struck and was repelled.

The third instrument I beg leave to show to the Society is

a new *ophthalmoscope.* The practical improvements which of late have been made in the construction of ophthalmoscopes have reference to their use as optometers, thus aiding our examinations of the state of refraction, and making them independent of the answers of the patients. The advantage of having an instrument which admits this examination with the smallest loss of time, is felt by every ophthalmologist. A rotating disc behind the mirror, first employed by Mr. Rekoss, of Königsberg, and modified so usefully by Dr. E. G. Loring, of New-York, seems to be the best mechanical contrivance for using the ophthalmoscope as an optometer. Loring's three discs, however, cause considerable loss of time by changing from one to the other, and Cohn's modification, which puts all the glasses of Loring's three discs into one large disc of 3 inches in diameter, appears clumsy and unmanageable. Apart from these inconveniences, the discs in Loring's ophthalmoscope have not a sufficient number of glasses for the requirements of a careful ophthalmic practitioner. Some years before Dr. Loring constructed his instrument, I had a complete collection of small trial-glasses made which I could insert into an ordinary small (Liebreich) ophthalmoscope, and Dr. H. D. Noyes had his ophthalmoscope so changed that he could place behind the mirror all the numbers of his trial case of spectacles. All this, however, requires too much time for constant use. The ophthalmoscope which I have the honor to show you affords the greatest possible



Fig. 1.

number of trial-glasses behind the eye, permits them to be rapidly changed, while the instrument is nearly as small as

Loring's. It consists of the ordinary mirror, behind which two discs can be rotated like the diaphragm in some—for instance, Kellner's—microscopes. In each disc are thirteen little aper-



FIG. 2.

tures, twelve of which are filled with glasses, one being empty, (see Fig. 2 A.) One disc contains convex, the other concave glasses, in the following progression: 3, 4, 6, 8, 10, 12, 14, 17, 20, 24, 33, 48.[1] The intervals of refractive power between these numbers are as follows: between 3 and 4 = $\frac{1}{12}$; 4 and 6 = $\frac{1}{12}$; 6 and 8 = $\frac{1}{24}$; 8 and 10 = $\frac{1}{40}$; 10 and 12 = $\frac{1}{60}$; 12 and 14 = $\frac{1}{84}$; 14 and 17 = $\frac{1}{79}$; 17 and 20 = $\frac{1}{113}$; 20 and 24 = $\frac{1}{120}$; 24 and 33 = $\frac{1}{88}$; 33 and 48 = $\frac{1}{100}$. The weaker numbers which occur more frequently in practice, show very small intervals of refraction. These two series of glasses are sufficient for the majority of cases coming before the practitioner. To avoid, however, any loss of time, both discs are placed behind the mirror, and the change from one glass to any other is effected by a very easy rotation of the disc. The discs are held in

[1] NOTE.—In the new instruments + 2 and —2 are added.

place and protected from being soiled by a thin metal plate, (Fig. 2 B.,) which covers the glasses from behind, whilst in front the discs are applied to the body of the instrument. The



FIG. 3. A

cover has three holes; the middle one corresponds to the perforation of the mirror, through the two others, placed respectively above and below the central one, the numbers of the glasses can be read, (see Fig. 3.) The cover can be removed if the glasses require cleansing. The vertical diameter of the ophthalmoscope, the handle, of course, not included, is 60 millimeters, not quite 2½ inches; its horizontal diameter is 35 millimeters, not quite 1½ inches.

The instrument has, however, another advantage: the edges of the two discs overlap each other at the place of the perforation of the mirror, so that each glass of one disc can be superposed by each glass of the other disc, thus giving combinations of glasses which will satisfy all practical and scientific demands. It is easy to make intermediate numbers between the higher

numbers of the discs. If, for instance, you superpose —4 and +48, you have the number —4.33. If you superpose —4 and + 24, you get $-\frac{5}{24}$ or nearly — 5, and so forth. If you want to know the distance between two parts of the fundus oculi, for instance, the centre and the margin of the optic disc, you determine the position of one part by one disc, and add or take away so much refractive power by the other disc as is required to see the second part clearly. Say, for instance, that the centre of an excavated papilla appears clear with — 8. You then leave the disc of the concave glasses with — 8 behind the aperture in the mirror, rotate the disc of the convex glasses and find that convex 24 renders the margin of the papilla clear. Then the refractive difference between the margin and the centre of the disc is $\frac{1}{24}$, which indicates an excavation of 0.4 millimetres in depth. I need not multiply examples, as the use of the instrument is very simple. Messrs. Miller Bros., manufacturing opticians, 1223 Broadway, New-York City, have made the instrument with extreme neatness. Its whole thickness is only 5 millimetres.

Two objective lenses, (Fig. 3, A.,) No. 2 and No. 3, are added, and the whole instrument is contained in a case which is only a little more than half as large as Fig. 3. Its price is $40.

TRANSACTIONS

OF THE

AMERICAN

OPHTHALMOLOGICAL SOCIETY.

TENTH ANNUAL MEETING.

NEWPORT, JULY, 1874.

NEW YORK:
WILLIAM WOOD & CO., 27 GREAT JONES STREET.

1874.

TRANSACTIONS

OF THE

AMERICAN

OPHTHALMOLOGICAL SOCIETY.

TENTH ANNUAL MEETING.

NEWPORT, JULY, 1874.

NEW YORK:
WILLIAM WOOD & CO., 27 GREAT JONES STREET.

1874.

CONTENTS.

PAGE

Members of the Society 117

Minutes of the Tenth Annual Meeting 119

Astigmatism produced by Tenotomy of Recti Muscles. By H. D. NOYES, M.D., New York 128

Three Cases of Conical Cornea, corrected by suitable Glasses. By W. THOMSON, M.D., Philadelphia 132

On the Atropine Treatment of Acquired and Progressive Myopia, with a Table of Cases. By HASKET DERBY, M.D., Boston 139

Case of Extreme Myopia. By H. D. NOYES, M.D., New York 155

Visual Acuteness = $\frac{17}{8}$ to $\frac{47}{16}$. By B. JOY JEFFRIES, M.D., Boston ... 158

A new Modification of the Ophthalmoscope (with Plate). By E. G. LORING, JR., M.D., New York 161

Cases of Optic Neuritis (with Figures). By W. F. NORRIS, M.D., Philadelphia 163

On the Circulation of the Optic Nerve and Retina in Disease of the Spinal Cord and Membranes, dependent upon Caries of the Vertebræ. By C. S. BULL, M.D., New York 170

Syphilitic Gumma in the Ciliary Body (with Plate). By E. G. LORING, JR., M.D., and H. C. ENO, M.D., New York 174

On color-tests for Ametropia, based upon the Chromatic aberration of the Eye. By John Green, M.D., St. Louis 179

Two Cases of intraocular Sarcoma. By O. F. WADSWORTH, M.D., Boston 185

Brief Report of a Case of pigmented Sarcoma. By W. THOMSON, M.D., Philadelphia 190

Case of Melanosis of Apparent Traumatic Origin. By A. MATHEWSON, M.D., Brooklyn 193

Two Cases of interesting Syphilitic Lesion of the Eye. By C. S. BULL, M.D., New York 195

Sympathetic Ophthalmia, persisting after Enucleation. Removal of Extremity of Optic Nerve and surrounding Tissues. Recovery. By HASKET DERBY, M.D., Boston 198

PAGE

A Foreign Body in the Globe only producing Sympathetic Trouble after Thirteen Years. By B. JOY JEFFRIES, M.D., Boston..... 203
Trephining the Cornea to remove a foreign Body deeply imbedded in its Substance. By C. R. AGNEW, M.D., New York..... 204
A new Method of treating Blepharospasm. By A. MATHEWSON, M.D., Brooklyn..... 207
A Case of double, extremely minute, and apparently congenital Lachrymal Fistula. By C. R. AGNEW, M.D., New York..... 209
Three new Instruments (with Wood-cuts). By RUSSELL MURDOCH, M.D., Baltimore..... 211
Instrument for facilitating Section of the Optic Nerve (with Wood-cuts). By G. HAY, M.D., Boston..... 214
Two new Instruments (with Wood-cuts). By H. D. NOYES, M.D., New York..... 215
Case of Herpes Zoster Ophthalmicus. The whole side of Nose involved without Affection of the Eye. By O. F. WADSWORTH, M.D., Boston 219
Six Cases of Herpes Zoster Ophthalmicus, with Remarks. By B. JOY JEFFRIES, M.D., Boston..... 221
Treatment of Cases of Herpes Zoster Frontalis by Electricity. By A. MATHEWSON, M.D., Brooklyn..... 228
Canthoplasty: a Clinical Study. By H. ALTHOF, M.D., New York..... 232
Schneller's Operation for Trichiasis and Entropium of the Lower Lid. By J. S. PROUT, M.D., Brooklyn..... 249
A Contribution to the Statistics of Cataract Extraction of One Hundred and Eighteen recent Cases. By C. R. AGNEW, M.D., New York..... 251
A new Method of Operating for Strabismus. By J. F. NOYES, M.D., Detroit..... 273

MEMBERS

OF THE

American Ophthalmological Society.

ACTIVE MEMBERS.

Dr. C. R. Agnew	19 East 39th St.,	New York, N. Y.
Dr. Charles M. Allin	42 West 36th St.,	" "
Dr. H. Althof	40 West 36th St.,	" "
Dr. Joseph Aub	102 West Seventh St.,	Cincinnati, O.
Dr. Edwin W. Bartlett	115 Wisconsin St.,	Milwaukee, Wis.
Dr. Charles S. Bull	214 West 44th St.,	New York, N. Y.
Dr. F. J. Bumstead	32 West 26th St.,	" "
Dr. W. F. Carmalt	In Europe.	
Dr. Edward Curtis	27 Washington Place,	" "
Dr. Edward Delafield	1 East 17th St.,	" "
Dr. Francis Delafield	12 West 32d St.,	" "
Dr. Hasket Derby	12 Beacon St.,	Boston, Mass.
Dr. Richard H. Derby	111 East 25th St.,	New York, N. Y.
Dr. John H. Dix	Hotel Pelham, Boylston cor. Tremont Sts.,	Boston, Mass.
Dr. Lewis S. Dixon	49 Pearl St.,	Worcester, Mass.
Dr. Abram Du Bois	16 West 30th St.,	New York, N. Y.
Dr. E. Dyer	154 Third Ave.,	Pittsburgh, Pa.
Dr. Henry C. Eno	58 East 25th St.,	New York, N. Y.
Dr. John Green	1613 Washington Ave.,	St. Louis, Mo.
Dr. A. D. Hall	1623 Spruce St.,	Philadelphia, Pa.
Dr. George C. Harlan	1806 Chestnut St.,	" "
Dr. Gustavus Hay	91 Charles St.,	Boston, Mass.
Dr. Edward L. Holmes	207 S. Clark St., N. E. cor. Adams St.,	Chicago, Ill.
Dr. Edwin Hutchinson	14 Bleecker St.,	Utica, N. Y.
Dr. B. Joy Jeffries	15 Chestnut St.,	Boston, Mass.
Dr. Samuel J. Jones	758 Wabash Ave.,	Chicago, Ill.

Dr. CHARLES J. KIPP	8 Centre St.,	Newark, N. J.
Dr. H. KNAPP	25 West 24th St.,	New York, N. Y.
Dr. EDWARD G. LORING	151 Lexington Ave.,	" "
Dr. ARTHUR MATHEWSON	17 Clinton St.,	Brooklyn, N. Y.
Dr. R. J. MCKAY	107 West 22d St.,	New York, N. Y.
Dr. C. S. MERRILL	49 Eagle St.,	Albany, N. Y.
Dr. H. G. MILLER	262 Benefit St.,	Providence, R. I.
Dr. T. G. MORTON	1421 Chestnut St.,	Philadelphia, Pa.
Dr. RUSSELL MURDOCH	12 Cathedral St.,	Baltimore, Md.
Dr. HOMER G. NEWTON	17 Clinton St.,	Brooklyn, N. Y.
Dr. WILLIAM F. NORRIS	1526 Locust Street.,	Philadelphia, Pa.
Dr. HENRY D. NOYES	73 Madison Ave.,	New York, N. Y.
Dr. J. F. NOYES	101 Shelby St.,	Detroit, Mich.
Dr. CHARLES J. PARDEE	72 West 35th St.,	New York, N. Y.
Dr. O. D. POMEROY	33 East 29th St.,	" "
Dr. THOMAS R. POOLEY	106 West 34th St.,	" "
Dr. J. S. PROUT	167 Clinton St.,	Brooklyn, N. Y.
Dr. CHARLES E. RIDER	60 South Fitzhugh St.,	Rochester, N. Y.
Dr. C. A. ROBERTSON	Hawk St., cor. State St.,	Albany, N. Y.
Dr. D. B. ST. JOHN ROOSA	20 East 30th St.,	New York, N. Y.
Dr. W. W. SEELY	118 West 7th St.,	Cincinnati, O.
Dr. HENRY L. SHAW	159 Boylston St.,	Boston, Mass.
Dr. FRANCIS SIMROCK	64 East 12 St.,	New York, N. Y.
Dr. A. G. SINCLAIR	70 Fort St., West,	Detroit, Mich.
Dr. GEORGE T. STEVENS	47 Eagle St.,	Albany, N. Y.
Dr. FRANCIS P. SPRAGUE	9 Chestnut St.,	Boston, Mass.
Dr. GEORGE STRAWBRIDGE	1616 Chestnut St.,	Philadelphia, Pa.
Dr. WILLIAM THOMSON	1502 Locust St.,	" "
Dr. J. J. B. VERMYNE	174 Union St.,	N. Bedford, Mass.
Dr. O. F. WADSWORTH	84 Charles St.,	Boston, Mass.
Dr. DAVID WEBSTER	19 East 39th St.,	New York, N. Y.
Dr. ROBERT WILLARD	93 Charles St.,	Boston, Mass.
Dr. CHARLES H. WILLIAMS	15 Arlington St.,	" "
Dr. E. WILLIAMS	64 West 7th St.,	Cincinnati, O.
Dr. HENRY W. WILLIAMS	15 Arlington St.,	Boston, Mass.

TOTAL 61

HONORARY MEMBERS.

Dr. G. A. BETHUNE	166 Tremont St.,	Boston, Mass.
Dr. ISAAC HAYS	1525 Locust St.,	Philadelphia, Pa.
Dr. R. W. HOOPER	114 Beacon St.,	Boston, Mass.
Dr. JOHN JEFFRIES	15 Chestnut St.,	" "
Dr. E. REYNOLDS	7 Park Sq.,	" "
Dr. C. SCHWEIGER	Berlin,	Prussia.
Dr. GEORGE WILKES	16 North Washington Sq.,	New York, N. Y.

TOTAL 7

WHOLE NUMBER 68

AMERICAN

OPHTHALMOLOGICAL SOCIETY.

NEWPORT, *July* 16th, 1874.

THE Society held its tenth annual meeting at the Aquidneck House.

The first session opened at 10.30 A. M., by the President, Dr. C. R. Agnew, of New York, who gave a brief introductory address.

The chair then appointed a committee to prepare a bulletin of papers to be presented, consisting of Drs. Jeffries, Rider, and Norris. Also a commitee on election of new members, consisting of Drs. H. W. Williams, Thomson, Green, Richard H. Derby, and Prout. The same Committee were by resolution charged with the duty of nominating officers for the ensuing year, and proposing the place of meeting.

The Secretary announced the death of two members during the year—Dr. Edward M. Curtis, of Sacramento, Cal., and of Dr. Lawton, of Syracuse.

The Treasurer's report was read, accepted, and referred to an Auditing Committee; viz., Drs. J. F. Noyes and Bull.

The Auditing Committee reported the Treasurer's account to be correct and duly vouched for.

The Committee on Bulletin then reported the following order of papers:

1. Case of Herpes Zoster Ophthalmicus. The whole side of nose involved without affection of the eye. By Dr. WADSWORTH.

2. Six cases of Herpes Zoster Ophthalmicus, with remarks. By Dr. JEFFRIES.

In this connection Dr. Mathewson reported some cases under his own observation.

3. Two cases of interesting Syphilitic Lesion of the Eye. By Dr. BULL.

4. A case of Sympathetic Irritation of one Eye following injury of the other. By Dr. DYER.

5. Sympathetic Ophthalmia, persisting after Enucleation. Removal of Extremity of Optic Nerve and surrounding Tissues. Recovery. By Dr. H. DERBY.

In addition to case reported by Dr. Derby of exsection of the stump of the nerve, others were given by Dr. H. D. Noyes, Dr. Loring, and Dr. Althof. Dr. J. F. Noyes reported a case of detachment of the retina which excited sympathetic irritation of the other eye, and which was removed by enucleation.

6. Astigmatism produced by Tenotomy of Recti Muscles. Dr. H. D. NOYES.

The cause of the astigmatism was operations of tenotomy for muscular insufficiency. Dr. Mathewson reported a case of acquired astigmatism, caused by a tumor of the upper lid, which disappeared on removal of the tumor. Cases of acquired astigmatism not caused by any apparent lesion were given by Drs. Loring, Pomeroy, and Green. Dr. Webster recited a case produced by permitting an infant to suck upon the mother's closed eye, to make it go to sleep. Dr. Thomson gave a case which ensued from phlyctenular inflammation of the cornea.

7. Three Cases of Conical Cornea, corrected by suitable Glasses. By Dr. THOMSON.

8. On the Atropine Treatment of Acquired and Progressive Myopia. With a Table of Cases. By Dr. H. DERBY.

9. Case of Extreme Myopia. By Dr. H. D. NOYES.

10. Mydriasis treated by Electricity. By Dr. WEBSTER.

Various members gave experiences of success, and want of success by galvanic treatment, using both kinds of currents.

11. Cases of Inflammation in the Orbit. By Dr. H. D. NOYES.

12. Visual Acuteness = $\frac{17}{8}$ to $\frac{17}{10}$. By Dr. JEFFRIES.

13. A new Modification of the Ophthalmoscope. By Dr. LORING.

14. Syphilitic Gumma in the Ciliary Body. By Dr. LORING.

15. On the Circulation of the Optic Nerve and Retina in Disease of the Spinal Cord and Membranes dependent upon Caries of the Vertebræ. By Dr. BULL.

The Committee on Membership reported to the Society, and recommended for election:

Dr. C. S. MERRILL,	Albany, N. Y.
" EDWIN W. BARTLETT,	Milwaukee, Wis.
" LEWIS S. DIXON,	Worcester, Mass.
" A. G. SINCLAIR,	Detroit, Mich.

All of these gentlemen were duly balloted for and elected.

The papers read were on motion referred to the Publishing Committee.

The thanks of the Society were returned to Dr. Samnel W. Francis, for his proposed entertainment, and the regret expressed that the time of final adjournment will prevent the enjoyment of his proffered hospitality. The Secretary was directed to make this communication to Dr. Francis. Adjourned to meet at 8 P. M.

July 16, 1874.

Society met at 8 P. M.

The President, Dr. Agnew, took the chair. Minutes of the morning session were read and approved.

The bulletin resumed:

16. On Color-Tests for Ametropia, based upon the Chromatic Aberration of the Eye. By Dr. GREEN.

17. Trephining the Cornea to remove a Foreign Body. By Dr. AGNEW.

Dr. Noyes reported an unusual proceeding for removing a deeply seated foreign body.

18. A new method of treating Blepharospasm. By Dr. MATHEWSON.

19. Case of Congenital Lachrymal Fistula. By Dr. AGNEW.

20. Exhibition of new instruments.

Dr. Murdoch showed a speculum and fixation forceps, and a knife for tenotomy of the muscles of the eye. Dr. Hay showed an instrument to facilitate the removal of a long piece of the optic nerve in enucleation.

Dr. H. D. Noyes showed a new form of lid-retractor, adapted to deeply set eyeballs; also a fixation forceps which is held by the speculum.

The Committee on Membership presented for election the name of Dr. Charles H. Williams, of Boston, who was duly elected.

They also recommended that the next meeting in 1875 be held at Newport, which was adopted.

The Treasurer proposed that the assessment for the coming year be ten dollars. Adopted.

Dr. H. W. Williams reported that the Treasurer in Berlin of the fund for erecting a monument to Von Graefe, Mr. Felix Mendelssohn, had acknowledged the receipt of a sum amounting to six hundred and forty dollars, subscribed mostly by members of this Society. Ordered to be entered on the minutes.

Dr. Williams also reported the receipt of a letter from Professor Hasner, of Prague, acknowledging the courtesy of the Society in sending him their Transactions.

Dr. Prout offered the following resolutions, which were adopted, viz.:

Resolved, 1st, That the numbers of the published Transactions of the Society for its first eight meetings be considered the first volume of Transactions.

2d. That the second volume shall commence with the proceedings of 1873, and that in the published proceedings of the current and of subsequent years, the numbers shall be called parts of each volume, and paged continuously until about seven hundred pages shall have been printed.

3d. That the Secretary, Dr. H. D. Noyes, be requested to prepare a preface for the first volume, which shall include a history of the inception and original organization of this society, and a notice of its first meeting; and an index which shall be printed and sent, with title-page for Volume 1, to each member.

4th. That the Secretary, when each volume is completed, be requested to prepare a title-page and index therefor, which shall be printed and sent to each member.

Adjourned to meet at 9 A. M.

NEWPORT, *July* 17, 9½ A. M.

The President, Dr. Agnew, took the chair. The minutes of the previous session read, and, with certain amendments, approved.

The President brought before the Society the subject of making preparations to receive the International Congress in 1876.

Dr. H. W. Williams moved that a committee of six be appointed by the chair to advise with the Committee appointed in London, and to report to this meeting such suggestions as they have to offer. The chair appointed Drs. Williams, Jeffries, H. Derby, Thomson, Green, Rider, and Murdoch.

Voted, That the Committee on New Members be instructed to name a committee to give a report at the next meeting on the Progress of Ophthalmology.

Voted, That this Committee on New Members also consider the matter of a change in the by-laws, altering the time of meeting of the Society from the third Thursday to the second Thursday of July.

The bulletin resumed:

21. Cases of Optic Neuritis and Illustrations By Dr. NORRIS. Discussion by Drs. Wadsworth and Noyes.

22. Canthoplasty: a Clinical Study. By Dr. ALTHOF. Remarks by Drs. Pomeroy, Prout, and Agnew.

23. Sarcoma of the Choroid, with Specimen. By Dr. STEVENS.

24. Sarcoma of the Choroid; two Cases, with Specimens. By Dr. WADSWORTH.

25. Sarcoma of the Choroid, with Specimen. By Dr. JEFFRIES.

26. Case of Foreign Body in the Globe, with Specimen. By Dr. JEFFRIES.

Cases of Sarcoma were also verbally reported by Drs. Mathewson, Bull, Thomson, and Noyes, who were requested to hand them in writing to the Secretary for publication.

The Committee on Membership reported, as the Committee on the Progress of Ophthalmology, the names of Drs. H. D. Noyes and Wadsworth.

Dr. Noyes returned thanks for the honor, but would be unable to accept the duty. Dr. Wadsworth was then appointed.

The Committee also reported that the time of meeting be changed to the fourth Thursday of July.

On motion, adjourned for five minutes.

After a recess of five minutes, the Society called to order by the President. The minutes of the Session read and approved.

The proposed amendment to the by-laws as to time of meeting brought forward. Dr. Green proposed to substitute the second Thursday for the fourth Thursday, as recommended by the Committee. This proposition was lost.

The vote then taken on the proposition of the Committee, which resulted in thirteen in favor, and three against it. This vote being just one-half the total number present at this annual meeting, and not a majority, the vote was decided in the affirmative, by the casting vote of the President, viz., fourteen to three, the number in attendance at this meeting being twenty-six.

The Special Committee as to the International Congress presented their report, which was accepted, as follows:

The Committee respectfully report that they recommend that the Congress be held at Newport, R. I., rather than in any large city, for reasons as follows:

Newport is, as it were, neutral ground as regards the different sections of our country. All members in attendance will be at leisure in Newport to attend to our guests, while in a city the local delegation must be more or less engrossed with their private cases.

The success of our own meeting in Newport is an earnest of a similar greater success of the Congress, if held in Newport rather than in any large city.

The visits of our friends to the institutions of our cities can be better and more advantageously made by individuals or in small parties than in the crowd incident to visits in the interval of the sessions when held in a large city.

In Newport an elegant private hospitality may probably be invoked in behalf of our guests.

All our guests will necessarily visit our cities: the meeting at Newport will give a glimpse of another phase of American life.

The Committee express the hope that the members of this Society may receive our foreign visitors as our guests, taking

them under our charge from the time of their leaving New York until the end of the Congress.

A brief sketch of possible tours with cost, etc., and especially a directory of members of our Society, may greatly facilitate the movements of our guests, and add to the cordiality of their reception when journeying through the country.

The Committee also recommend the following as a Co-operative Committee to aid in carrying out more fully the hospitable wishes of the Society, omitting names of members from New York City who have already been designated by the New York Ophthalmological Society:

Dr.	H. W. Williams,	Boston, Mass.
"	G. Hay,	" "
"	B. J. Jeffries,	" "
"	Isaac Hays,	Philadelphia, Penn.
"	W. Thomson,	" "
"	W. F. Norris,	" "
"	George Strawbridge,	" "
"	J. S. Prout,	Brooklyn, N. Y.
"	Arthur Mathewson,	" "
"	G. T. Stevens,	Albany, "
"	C. S. Merrill,	" "
"	Edwin Hutchinson,	Utica, "
"	Charles E. Rider,	Rochester, "
"	Ezra Dyer,	Pittsburgh, Penn.
"	Russell Murdoch,	Baltimore, Md.
"	H. G. Miller,	Providence, R. I.
"	J. J. B. Vermyne,	New Bedford, Mass.
"	E. Williams,	Cincinnati, O.
"	Edward L. Holmes,	Chicago, Ill.
"	J. F. Noyes,	Detroit, Mich.
"	John Green,	St. Louis, Mo.
"	Edwin W. Bartlett,	Milwaukee, Wis.

Dr. Mathewson moved that the Secretary have printed an amended copy of the constitution and by-laws. Carried.

Dr. Mathewson also moved that the Secretary be instructed to have printed a list of members with their addresses in detail, to be sent to the members. Carried.

The bulletin resumed:

27. Operations for Entropium and Trichiasis according to Jaesche's method. Dr. Green.

28. A Contribution to the Statistics of Cataract Extraction of one hundred and eighteen recent Cases. Dr. AGNEW.

29. Twenty-two Extractions of Cataract. Dr. RIDER.

30. A new method of operating for Strabismus. Dr. J. F. NOYES.

Considerable discussion ensued upon this paper, which was verbally presented—the method being in reality a new process of advancement of a muscle.

The resolutions regarding the sending of papers to the Publishing Committee were reaffirmed—the time fixed for placing them in the hands of the Committee being September 15th.

The reproduction of Green's tables for testing Astigmatism was referred to the Publishing Committee, in connection with Dr. Green.

The Committee on New Members, etc., reported the nomination of the following officers for the ensuing year, viz.:

For President, Dr. C. R. AGNEW, New York.

For Vice-President, Dr. G. HAY, Boston.

For Recording Secretary and Treasurer, Dr. RICHARD H. DERBY, New York.

For Corresponding Secretary, Dr. H. ALTHOF, New York.

For Publishing Committee, Dr. H. D. NOYES, Dr. E. G. LORING, New York.

The above officers were unanimously elected. Dr. Agnew returned thanks to the Society for the honor conferred upon him.

Dr. Williams moved that the thanks of the Society be offered to Dr. H. D. Noyes, for his assiduous labors as the Recording Secretary and Treasurer of the Society during the period of ten years, and the regret of the Society that he finds himself compelled to relinquish the position. Carried. And Dr. Noyes responded.

On motion, adjourned.

HENRY D. NOYES, M.D.,
Recording Secretary.

THE FOLLOWING MEMBERS WERE IN ATTENDANCE ON THE MEETING OF JULY, 1874.

Dr.	DAVID WEBSTER,	New York, N. Y.
"	ARTHUR MATHEWSON,	Brooklyn, "
"	J. F. NOYES,	Detroit, Mich.
"	E. DYER,	Pittsburgh, Penn.
"	O. F. WADSWORTH,	Boston, Mass.
"	C. S. BULL,	New York, N. Y.
"	H. W. WILLIAMS,	Boston, Mass.
"	H. ALTHOF,	New York, N. Y.
"	J. S. PROUT,	Brooklyn, "
"	O. D. POMEROY,	New York, "
"	JOHN GREEN,	St. Louis, Mo.
"	WM. THOMSON,	Philad'phia, Penn.
"	G. HAY,	Boston, Mass.
"	RUSSELL MURDOCH,	Baltimore, Md.
"	J. J. B. VERMYNE,	N. Bedford, Mass.
"	CHARLES E. RIDER,	Rochester, N. Y.
"	HENRY D. NOYES,	New York, "
"	C. R. AGNEW,	" "
"	HASKET DERBY,	Boston, Mass.
"	B. JOY JEFFRIES,	" "
"	RICHARD H. DERBY,	New York, N. Y.
"	EDWARD G. LORING, JR.,	" "
"	W. F. NORRIS,	Philad'phia, Penn.
"	GEORGE T. STEVENS,	Albany, N. Y.
"	F. J. BUMSTEAD,	New York, N. Y.
"	LEWIS S. DIXON,	Worcester, Mass.

ASTIGMATISM PRODUCED BY TENOTOMY OF RECTI MUSCLES. By Dr. Henry D. Noyes, New York.

Miss A. B., æt. 18, New York, came to me in June, 1867, for advice respecting her eyes. She had never worn glasses, notwithstanding she had myopia: in the right eye $-\frac{1}{18}$; in the left $-\frac{1}{24}$; in both V. $= \frac{20}{20}$. Her chief complaint was on account of double vision for distant objects. The diplopia corrected by a prism of 3°, with base outwards and horizontal. Sometimes her eyes become visibly crossed. Another examination, made three months later, modified the record of ametropia by the detection of a slight astigmatism in each eye, and the formula was written—

$$\text{O. D.} - \tfrac{1}{20}\ \text{s} - \tfrac{1}{48}\ \text{c}\ 65^\circ\ \text{V.} = \tfrac{20}{20}.$$
$$\text{O. S.} - \tfrac{1}{20}\ \text{s} - \tfrac{1}{48}\ \text{c}\ 20^\circ\ \text{V.} = \tfrac{20}{20}.$$

The diplopia is due to paresis of left rectus externus, and requires a correcting prism of 4° for distance. About six months later, the paresis had increased so much as to require a prism of 8°.

I made a tenotomy of the left rectus internus, which was done with such extreme care as to produce absolutely no effect upon the equilibrium of the muscles. About three weeks later, I made a tenotomy of both recti interni at the same sitting, and found the muscles large. The effect was to give on the following day crossed images for fifteen feet, which by a strong effort she could just overcome. In ten days there was correct single vision, from twelve feet to three inches in the median line, and at twelve feet an abductive power of 3°. In five weeks later additional improvememt had taken place. Single vision was enjoyed at all distances on the median line, and also on the side toward the paretic muscle (the left), while an extreme move-

ment to the right elicited crossed diplopia. When the eyes were turned to the extreme limit on either temporal side, nystagmus would occur. It thus appeared that the tenotomies had been pushed to the bounds of safety, and the patient was able to use her eyes with comfort. During about two years the improvement continued; diplopia was entirely absent; there was no pain; the glasses served their purpose for distant vision. I congratulated myself upon a result so auspicious, and upon the accuracy which had been obtained in a kind of operation which will not always behave according to rules.

But the sequel remains. Miss C. made a visit to Europe in 1871, remaining about eighteen months, and just before her departure she found that some tendencies to the original variety of diplopia began to appear—*i. e.* paresis of the left externus. After being abroad for some time the trouble increased, and at length, under advice of Dr. D. in Switzerland, she submitted to another tenotomy of the left rectus internus. This was the third time that this muscle had been attacked. The details of the operation and the amount of effect produced, I do not know; but on her return home there was crossed diplopia, which required at fifteen inches a prism of 6° base inwards. That is, there was insufficiency of the rectus internus, and also of the rectus externus of the left eye. The annoyances of this condition were much more acutely felt than were those which she before endured. It was impossible to use her eyes upon near work, and to use her glasses for distance made her uncomfortable, because she was not quite able to secure single vision.

Examination showed the following to be the state of the eye, in June, 1872:

$$\text{O. D.} - \tfrac{1}{16}\ \text{s} - \tfrac{1}{36}\ \text{c}\ 10^\circ\ \text{V.} = \tfrac{20}{20}.$$
$$\text{O. S.} - \tfrac{1}{36}\ \text{s} - \tfrac{1}{15}\ \text{c}\ 20^\circ\ \text{V.} = \tfrac{20}{20}.$$

At sixteen inches there is an insufficiency of adduction with a prism base upwards of 15°; at fifteen feet with a prism base upwards, there is insufficiency of abduction of 20°. It will be noted that the optical conditions have already decidedly changed. In the right eye myopia has advanced, both in the spherical and cylindrical sense, to a slight degree; while in the left and much operated eye, the spherical error has diminished from $\frac{1}{20}$ to $\frac{1}{36}$ and the cylindrical error been augmented from $\frac{1}{48}$ to $\frac{1}{15}$. A

diminution in spherical error of $\frac{1}{45}$, and an addition to the cylindrical error of $\frac{1}{25}$. I prescribed for reading a pair of prismatico-cylindric glasses, which gave great comfort.

In March, 1874, the following data were obtained:—In viewing a candle at twenty feet with correcting glasses, the amount of adduction = 9°, of abduction = 6°; with a prism before one eye vertically there was 2° of divergence. In looking at a candle at twenty feet, without correcting glasses, the amount of abduction was 15°, and when vertical diplopia was produced, there was divergence of 10°.

At the distance of fourteen inches, with vertical diplopia, there was deficiency of adduction of 7°.

The refractive condition was as follows:

O. D. — 16 s — 20 c 180° V. = $\frac{20}{20}$.
O. S. — 36 s — 12 c 175° V. = $\frac{20}{20}$.

It is thus seen that a muscular condition in which there was at the first defective abduction for distance of 8°, became converted into defective adduction by the repeated tenotomies. The degree of deficiency cannot perhaps be expressed in figures accurately, but the ratio of 9° adduction to 6° abduction for distance is wholly inadequate to comfort; while a ratio of 18° to 6° or 3 : 1 is much nearer to the average normal condition. The loss of adductive power may therefore be set down as from 17° to 20°.

The influence upon the refraction was most evident in the eye which was submitted to the greatest number of operations, viz., the left. Of course allowance may be fairly made for the natural tendency to increase of myopia in six years, but this has not been great. The right eye shows only an increase from $\frac{1}{20}$ s to $\frac{1}{16}$ s, and of astigmatism from $\frac{1}{48}$ c to $\frac{1}{20}$ c, but with a change of axis from 65° to 180°.

The left eye shows a diminution of spherical error from $\frac{1}{20}$ s to $\frac{1}{36}$ s, and increase of astigmatism from $\frac{1}{48}$ c to $\frac{1}{12}$ c, accompanied by a change of axis from 20° to 175°.

It appears, therefore, that the myopia which at its maximum in the left eye amounted to $\frac{1}{15}$ in the meridian of 20°, was increased by the operations to an error of $\frac{1}{9}$, and the position of the maximum meridian of curve underwent a rotation of 25°.

While the increase of optical error was not attended by any

special disadvantages to the patient, inasmuch as it was capable of perfect correction, the case in my judgment throws light on the etiology of astigmatism. I would also call attention to the very common association which is found to exist between myopic astigmatism and muscular insufficiency; and although astigmatism is commonly regarded as a congenital error of the eye, ought we not to set down a certain number of cases as the result of defective muscular equilibrium?

diminution in spherical error of $\frac{1}{45}$, and an addition to the cylindrical error of $\frac{1}{25}$. I prescribed for reading a pair of prismatico-cylindric glasses, which gave great comfort.

In March, 1874, the following data were obtained:—In viewing a candle at twenty feet with correcting glasses, the amount of adduction = 9°, of abduction = 6°; with a prism before one eye vertically there was 2° of divergence. In looking at a candle at twenty feet, without correcting glasses, the amount of abduction was 15°, and when vertical diplopia was produced, there was divergence of 10°.

At the distance of fourteen inches, with vertical diplopia, there was deficiency of adduction of 7°.

The refractive condition was as follows:

O. D. — 16 s — 20 c 180° V. = $\frac{20}{20}$.
O. S. — 36 s — 12 c 175° V. = $\frac{20}{20}$.

It is thus seen that a muscular condition in which there was at the first defective abduction for distance of 8°, became converted into defective adduction by the repeated tenotomies. The degree of deficiency cannot perhaps be expressed in figures accurately, but the ratio of 9° adduction to 6° abduction for distance is wholly inadequate to comfort; while a ratio of 18° to 6° or 3 : 1 is much nearer to the average normal condition. The loss of adductive power may therefore be set down as from 17° to 20°.

The influence upon the refraction was most evident in the eye which was submitted to the greatest number of operations, viz., the left. Of course allowance may be fairly made for the natural tendency to increase of myopia in six years, but this has not been great. The right eye shows only an increase from $\frac{1}{20}$ *s* to $\frac{1}{16}$ *s*, and of astigmatism from $\frac{1}{48}$ *c* to $\frac{1}{20}$ *c*, but with a change of axis from 65° to 180°.

The left eye shows a diminution of spherical error from $\frac{1}{20}$ *s* to $\frac{1}{36}$ *s*, and increase of astigmatism from $\frac{1}{48}$ *c* to $\frac{1}{12}$ *c*, accompanied by a change of axis from 20° to 175°.

It appears, therefore, that the myopia which at its maximum in the left eye amounted to $\frac{1}{15}$ in the meridian of 20°, was increased by the operations to an error of $\frac{1}{9}$, and the position of the maximum meridian of curve underwent a rotation of 25°.

While the increase of optical error was not attended by any

special disadvantages to the patient, inasmuch as it was capable of perfect correction, the case in my judgment throws light on the etiology of astigmatism. I would also call attention to the very common association which is found to exist between myopic astigmatism and muscular insufficiency; and although astigmatism is commonly regarded as a congenital error of the eye, ought we not to set down a certain number of cases as the result of defective muscular equilibrium?

atropia, the following formula gave the highest acuity of vision:

Rt. $+\frac{1}{10}$ cy ax. 30° ⌒ $-\frac{1}{10}$ cy ax. 120°.
Lt. $+\frac{1}{10}$ cy ax. 120° ⌒ $-\frac{1}{10}$ cy ax. 30°.

which increased V. from $\frac{10}{c}$ to $\frac{10}{xvi}$.

Case 2. M. P., age thirty-eight: seen first, December, 1870. Until eighteen years of age had perfect sight for distance, since he was a surveyor and could see the signals at half a mile distant. He then changed his occupation for that of a conveyancer, and in addition to his daily duties attempted to study law, by a poor light at night, keeping himself awake by walking the floor with his book in his hand. His general health broke down, and he then found his distant sight very imperfect, but improved by concave glasses.

Two years previously he had been examined and provided with a $-\frac{1}{8}$ sph. on the Right, and $-\frac{1}{9}$ s ⌒ $\frac{1}{18}$ cy on Left, which gave but little satisfaction for distant vision, and is interesting as showing the opinion of a clever surgeon. It was found that in the Left these glasses gave an induced hypermetropia $= \frac{1}{14}$, and a yet greater defect in the Right. Inspection, and the ophthalmoscope, revealed marked conical cornea, whilst the most patient efforts with test objects, spherical and cylindrical glasses, and stenopäic slits, with paralyzed accommodation, were needed to obtain a diagnosis. By the upright method it was found that the periphery of the cornea at some parts was hypermetropic, whilst the centre was highly myopic; and after hours of effort the following result was obtained:

Rt. $+\frac{1}{30}$ s. ⌒ $-\frac{1}{7}$ cy., axis 50°, V. $= \frac{20}{LX} = \frac{1}{3}$.
Lt. $-\frac{1}{24}$ s. ⌒ $-\frac{1}{15}$ cy., axis 115°, V. $= \frac{20}{XXX} = \frac{1}{21}$.

On the right this was a compromise, and was attended by a singular double vision, arising from the uncorrectable apex of the cone. When he regarded a gaslight, for example, there was at the side and below the sharp image a second large, indistinct blur of light. It was found that this second image could be sharpened in definition by a $-\frac{1}{8}$, at the expense, however, of the first and best one. The ghost of the main object was far enough away, and vague enough to interfere but little with the appearance of the true light, and the patient soon became indifferent to its presence. I have not seen this per-

son for three years, but I have recently been informed that he uses his correction with entire satisfaction. The etiology of this case is not less interesting than its correction with glasses.

Case 3. D. M. P., age forty-two:

When a boy, he could tell the time of the clock on a distant tower, and had perfect distant vision until sixteen years of age, when he went as clerk into a store, and for some months read from badly printed books for hours late into the night, by a very poor light. His sight became imperfect, and his general health also became impaired. At twenty he was using the glasses which he wore when first examined by me: on the Rt. $-\frac{1}{24}$, which gives for distance V. $\frac{10}{cc} = \frac{1}{20}$, but with which he is able to read at six inches from the eye; on Lt. $-\frac{1}{4}$, which gives so little aid that he uses the right for all purposes.

The reflex from the cornea, very small at centre, and rapidly increasing in size at the periphery, the deep anterior chamber, and the marked cone on lateral inspection left no doubt as to the diagnosis. This was confirmed by the play of light from the apex of the cone with the ophthalmoscope, and by finding the inverted image of the retinal vessels visible about 1 inch in front of the cornea; he could read large print at three inches, and with $-\frac{1}{24}$ s. at 6 inches, which was then his far point. With paralyzed accommodation and dilated pupil, the most contradictory results were obtained by stenopäic slits and circles. A circular opening of 1 mm. for example, and $-\frac{1}{2}$ s. gave V. $\frac{10}{xxx}$ at the conical centre, but nowhere else. With my test of double perforations, and one covered with crimson glass, the double light point would indicate either myopic or hypermetropic refraction as the patient moved his head, nor was it possible to ascertain by this method any more than the refraction of two peripheral points of a conical cornea. A stenopäic slit with spherical glasses was likewise unavailing, since it included in its analysis peripheral and central corneal portions; and for the same reason the radiating astigmatic lines of Greene only served to put the patient and the observer farther apart in their efforts to extract some truth from the conflicting experiences.

The upright examination with ophthalmoscope gave the most

precise preliminary knowledge, and enabled the surgeon to at least form some definite idea of the refraction; the apex of the cone demanded the highest concave glasses, whilst there were parts of the periphery of the cornea through which retinal vessels were seen with convex ones; one fixed point after the other was thus obtained, the patient's power of definite statement being gradually cultivated until the following result was reached, giving hypermetropia and myopia combined, and affording in Right V. $= \frac{20}{XXX}$ with $+ \frac{1}{10}$ cy., ax. 180°, ⌒ $-\frac{1}{6}$ cy., s., ax. 90°.

With the Left, the far point was $2\frac{1}{2}$ inches, and a $-\frac{1}{24}$ s gave V. $\frac{10}{CC}$; the appearances were the same as in the right, but there was greater distortion in light points and other test objects. With the ophthalmoscope in the upright method, I found when he wore his $-\frac{1}{24}$ s, that the horizontal retinal vessels were seen above it, avoiding its use, with $+ \frac{1}{12}$, and through it the vertical vessels were seen with $+ \frac{1}{8}$, and after wearisome examinations with the ophthalmoscope, and every other possible method, the best correction was obtained with the following remarkable combination: $-\frac{1}{34}$ cyld., axis 90° ⌒ $+\frac{1}{10}$ cyld., axis 180° V. $= \frac{20}{XL}$.

These glasses were constructed and properly mounted, and after the accommodation had returned, he had no insufficiency, there was binocular vision, he had an A $= \frac{1}{8}$, and could read with either eye $1\frac{1}{2}$ S at 12 inches fluently.

With either eye there was a ghost of the object regarded, which was dimly seen some distance below the real one. When he looked through his correction at a circle of light one-half inch in diameter, at twenty feet distant, it was clearly perceived, but below it there was seen a pear-shaped, hazy spectre of the same light, with its long axis perpendicular, and commencing just below the true light, and seeming to be six inches in length by two and one-half in width. The double vision was tested also by a disc of blue paper for an object, which was sharply defined, and recognized at twenty feet, whilst below it the patient observed a hazy, much larger, and ill-defined blue image of the disc.

From the study of this case and the one previously related, it would appear that by patient experimentation it might be

possible to correct the greater portion of a misshapen conical cornea, and to overpower by the brilliancy of its definition the remaining uncorrectable apex of the cone. This theory has been fairly successful in practice in these two instances; and either by the skilful arrangement of his head, or by happy accident, each patient can receive the sharp images of objects, through his glasses, on the macula, whilst the hazy images from the small corneal apex fall above it on a less sensitive portion of his retina.

Dr. Norris, who saw case 3d after the correction, pointed out to me that the axis of the cone was directed downwards. I found that the double images, below the true ones, could be obliterated, and vision a little improved, by lifting upwards, to the horizontal line in front of the eye, a screen, or other opaque body, thus cutting off the light that would pass through the lower portion of the cornea.

It is worthy of remark that in this last case, with such high degree of myopia, and the use for years of glasses so unsuited, there was not the slightest appearance of a crescent at the optic disc, posterior staphyloma, or choroiditis in either eye; and this could be definitely ascertained by observing the fundus through his correction, by either the erect or inverted method of using the ophthalmoscope.

NOTE.—Whilst revising the proofs of these histories, a fourth case has been treated, which will be briefly described.

M. W., aged 35, in 1861 had a tumor removed from upper lid of left eye; and in 1869 she used the eyes for hours at night, whilst nursing a sick relative, in reading and writing by a dim light. She now suffers from headache on the near use of the eyes for half an hour, which continues for hours afterwards.

There is Hy. of $\frac{1}{20}$ in right, with V. $\frac{1}{4}$. In left, V. $= \frac{10}{cc}$, not improved by + or — spherical glasses.

With the accommodation paralyzed, the V. in left is reduced for distance, but she can read at 3″, No. 2, Snellen, proving the existence of myopic refraction. By the ophthalmoscope aërial images of the retinal vessels are seen a short distance in front of a limited portion of the cornea, and by the erect image the refraction is there found myopic, whilst above this point convex glasses are needed to see vessels which pass from north-east to south-west; a careful examination with lines and letters gave proof of Hy. astigmatism and a $+ \frac{1}{10}$ cy., ax. at 10° gave V. $= \frac{20}{xxx}$.

With no glass a point of light is a streak, but with $\frac{1}{10}$ cy. it becomes a point,

but there extends from it downwards a luminous haze, which at 20 feet is 6 inches long by 3 wide, pear-shaped and having a point of brightness at its lower extremity ; this can be entirely cut off by placing a card over the lower half of the cornea.

After the atropia had passed away, and the accommodation had returned, she could read No. 2 fluently at 12 inches with the cylinder, or at 3″ without it, which she did by using, in the latter experiment, the conical part of the cornea.

ON THE ATROPINE TREATMENT OF ACQUIRED AND PROGRESSIVE MYOPIA. With a Table of Cases. By HASKET DERBY, M.D.

THE recent therapeutics of progressive and of acquired myopia have received but moderate attention from English writers on ophthalmology. Accepting apparently the dictum of Donders, that the cure of this error of refraction belongs to the class of things "devoutly to be wished for" with unquestioning faith, they have contented themselves with discussing the division of the external recti, in cases where weakness of the interni is found, and in going into the general question of prophylactics. The investigations that have been going on, especially in St. Petersburg and Basle, within the past six years, have attracted very little attention elsewhere, judging at least from current ophthalmic literature. It is therefore with less diffidence that I present a few results of my own, and, having nothing original as regards method to bring before the Society, briefly direct its attention to some departures from the received doctrines on this subject which a few years have inaugurated. Though few in number, they are by no means unimportant.

Speaking of the pain in and fatigue of the eyes experienced by many myopic persons during work on near objects, Donders observes in his classical work on the subject: "In the higher grades of myopia, a species of spasm of the accommodation is not unfrequently associated with this irritable condition, and an even increased degree of myopia is found, which disappears, however, as the irritability diminishes; especially after the abstraction of blood by means of the Heurteloup leech, and after a prolonged seclusion in the dark. Professor Junge, of

St. Petersburg, has called my attention to this fact, and I have found a confirmation of it in several cases."

It will be seen from the above that our illustrious master is inclined to limit the accommodative spasm to the higher grades of myopia, and hence considers its occurrence as comparatively infrequent. It is also to be inferred that he regards the spasm as dependent on the irritability, and as disappearing on its removal.

Different results have, however, been arrived at by a follower of Professor Junge, who undertook the investigation of this subject at his suggestion, and in 1868 published his labors in a supplement to the "Klinische Monatsblätter für Augenheilkunde." With the work of Dobrowolsky you are doubtless familiar, but a resumé of his opinions seems hardly out of place in this connection.

He found the complication of myopia with accommodative spasm to be much more frequent than had previously been supposed—observing it 69 times in 105 cases. It was met with in all grades, yet more frequently with the lower than the higher. It was found to occur with emmetropia and counterfeit myopia.

According to him, myopes, being under all circumstances unable to see distant objects distinctly, are less tempted to relax their accommodation for the far than emmetropes. The ciliary muscle is thus apt to remain in a state of constant tension. This spasmodic contraction yields slowly to atropine. One or two applications, even though made in substance, are not sufficient to cause complete relaxation, and the accommodation lets up little by little, and in a varying degree—the process often occupying several days. Where the intraocular pressure is heightened, the effect of the atropine is least, and increases as the former is diminished.

Dobrowolsky found the symptoms of irritation to depend on the cramp of the accommodation, and not, according to Donders, to act as its cause.

The increase or diminution in the myopia was also found to depend on the degree of congestion of the vessels of the intraocular tunics; local depletion directly diminishing the myopia by bringing about a lessened intraocular pressure, and hence a shortening of the visual axis.

While admitting, with Donders and Stellwag, the influence of hereditary predisposition, as well as congenital myopia, he found a distinct class of cases where undue exercise of the accommodation caused atrophic changes around the optic entrance, and consequent lengthening of the visual axis in the normal, and even in the hypermetropic eye. He found the latter developing staphyloma posticum, becoming emmetropic and even myopic.

The therapeutics employed by Dobrowolsky were the application of atropine, often in substance, and the use of the artificial leech on the temple. The latter he found to lessen the hyperemia resulting from the accommodative spasm; the former to diminish both. With reference to the acuteness of vision, he found this to increase in proportion as the capillary hyperemia of the optic entrance, the congestion, tortuousness, and number of the visible vessels were diminished. Atropine, by bringing this about, often added to the acuteness of vision, even where it did not diminish the refraction.

This is an exceedingly brief and imperfect resumé of the labors of Dobrowolsky. In 1871, Dr. Hosch, of Basle, a scholar of Professor Schiess Gemuseus, and in 1872 the Professor himself published short dissertations, the former on "The Therapeutical Effects of Atropine on Myopic Eyes," the latter on "The Therapeutics of Myopia." The pamphlet of Schiess is accompanied by a tabular statement of fifty-three cases, embracing the twenty-nine reported by his pupil.

To Professor Schiess belongs the credit of utilizing the researches of Dobrowolsky for ophthalmic practice. So long, he justly observes, as myopia was considered largely hereditary and entirely incurable, the ophthalmic surgeon contented himself with giving suitable cautions, and prescribing, in general terms, a course of dietetics calculated to arrest the progress of the trouble he had no hope of ameliorating. But with the knowledge that the affection commenced in many cases with an accommodative spasm, antedating the organic change, and with the certainty that it was often acquired during school years or in early life by individuals manifesting no hereditary predisposition, born emmetropic and even hypermetropic, to a much greater extent than had ever been imagined, came the

idea of probable arrest and possible diminution, and even cure.

Cases of acquired myopia were recognized by Schiess from the outset as those most adapted for treatment, the more recent being naturally the more favorable. He lays down the axiom that the longer the myopia has lasted, and the higher the degree it has acquired, the less is the proportion of spasm, and the greater that of lengthening of the axis, met with.

Withdrawing his patients from all use of the eyes on near objects, and arming them with protective glasses, he ordered twice daily the application of a solution of one part of atropine to 120 of water, and kept this up ordinarily for three or four weeks. The first result was taken after all the immediate effect of the atropine had subsided; and, for the purpose of estimating the ultimate effect, a second measurement was made as much later as possible—sometimes after one, sometimes after nine, months.

One hundred and one eyes were thus treated. The result was a conviction that atropine was capable of bringing about a permanent improvement in a very large number of cases of myopia, and of causing the complete disappearance of this error of refraction in certain cases where it was but slightly developed.

Spasm of accommodation was met with in a little over 85 per cent. of the cases treated.

Of 101 eyes 20 showed no myopia after atropinization.
66 " less " " "
in 15 myopia was unaltered or progressive.

In 69 per cent. there was definite improvement.
" 20 " " myopia was arrested.
" 9 " " myopia progressed.

I have made no special analysis of the results of Hosch, inasmuch as all his cases are embraced in the list just referred to. It should be noted that in the outset many cases of advanced myopia were treated, while later the atropine cure was only employed in the commencement of this affection. Had this

course been followed throughout, the results would have been even more favorable.

I present herewith a series of tables, drawn up on the plan of Professor Schiess, giving an analysis of the condition and results in sixty-seven eyes treated by me in this manner. These tables will readily explain themselves. Separate columns are left for the acuteness of vision, original myopia, immediate result (commonly estimated several days after the last application of atropine), and ultimate result as recorded at the last interview, as much later as possible—the interval between the two examinations being always given. These cases were all taken from my record-books, and some had been under observation a number of years. Under the head of "Remarks" I have stated any interesting points I could find in the history or progress of the case.

To a few of these cases I would call particular attention. Case No. 3 particularly interested me, from the manner in which the true state of the refraction came to be discovered. Patient, a schoolboy æt. twelve, had My. $\frac{1}{16}$ in February, 1866. In December of the same year it had increased to $\frac{1}{14}$. In March, 1867, there being much pain on use, I advised him to commence reading five minutes three times a day, increasing half a minute daily, and ordered him for this purpose $-\frac{1}{36}$ slightly tinted blue. April 27th there was still much local pain and intolerance of light, as well as blur on use. On examining his glasses, I found that the optician had given him, by mistake, *convex* $\frac{1}{36}$ instead of concave, and that his efforts to read with this glass had brought to light the true state of the refraction. An examination now showed Hm. $\frac{1}{36}$ and Ht. $\frac{1}{18}$. Pagenstecher reports * a case of chronic catarrh in a man 43 years of age, who had for three years worn what he bought for a plane, blue, protective glass. Up to the time of his putting it on, his vision had seemed normal. At first he had been unable to see distant objects as well, but after wearing the glass a time he grew accustomed to it, saw as well as ever, and was ultimately unable to get along without it. The glass proved to be convex $\frac{1}{12}$, given by a mistake of the optician for plane.

* Klin. Beob. aus der Augenheilanstalt zu Wiesbaden. Erstes Heft., S. 62.

I cannot agree with Pagenstecher that this was a case of acquired hypermetropia, but think that here, as in my own case referred to, the true refraction was brought to the surface by the accidental use of a partially neutralizing glass. If this is true, may it not be possible to overcome accommodative spasm by the use of appropriate convex glasses, and thus escape the loss of time incident to a prolonged course of atropine?

Case 9 was remarkable for the readiness with which the accommodative spasm yielded. The My. was $\frac{1}{20}$. Solid atropine was applied, and within 24 hours there was Hm. $\frac{1}{12}$. Thirteen days later there was Ht. $\frac{1}{8}$, showing a cramp of $\frac{1}{5.7}$ The largest cramp relieved by Schiess was one of $\frac{1}{8.2}$. In Liebreich's well-known case, My $\frac{1}{40}$. was converted by atropine into H. $\frac{1}{24}$, a cramp of $\frac{1}{15}$. So far as I have been able to follow the literature of the subject, the present is one of the largest degrees of cramp on record. The readiness with which it yielded to atropine was quite exceptional.

Case 30 shows My. $\frac{1}{20}$ turning into Ht. $\frac{1}{36}$ in the right eye, My. $\frac{1}{36}$ into Ht. $\frac{1}{36}$ in the left. On recommencing study, the right eye developed My. $\frac{1}{42}$; left, $\frac{1}{48}$. A weak convex glass being ordered for work on near objects, My. descended to $\frac{1}{60}$ in each eye. Contrary to orders, the glass was thrown aside, and the My. returned, as recorded, to $\frac{1}{48}$.

Case 32 shows a remarkable amount of spasm, which, unlike Case 9, yielded slowly and gradually to the influence of the mydriatic. December 13th, 1873, there was My. $\frac{1}{36}$ in each eye. 1874, January 9th, My. $\frac{1}{24}$, though all work had been refrained from during the interval. Commencing with January 12th, a solution of atropine (gr. os to ʒ j) was applied twice daily. 15th, Hm. $\frac{1}{30}$; 17th, Hm. $\frac{1}{18}$; 21st, Hm. $\frac{1}{14}$; 27th, Hm. $\frac{1}{13}$; 30th, the same; February 4th, Ht. $\frac{1}{11}$.

Finally, Case 14 exhibits the consequences resulting from persistent abuse of the eyes. E. G., æt. 12, the child of emmetropic parents, with no hereditary tendencies to near-sight, was examined by me in May, 1871, on account of pain and intolerance of light, brought on apparently by reading in the cars. My. $\frac{1}{72}$ was then found in each eye; no trace of posterior staphyloma was in existence. In November, 1872, she noticed that distant objects were growing less distinct, and there was

No.	NAM	REMARKS.
1	Mr. H.	t all myopic till within a few weeks. it through difficulty experienced in
2	Miss P.	of this eye was rapidly increasing, een only 1-20 in January, 1866. In eye M 1-14 stationary.
3	Master C	was first seen in February, 1866. pia was then 1-16. In December of year it was 1-14.
4	Mr. F.	xamined together. Small staphy- t. in each.
5	Mr. G.	light scleral atrophy about each rance. The progress of the myopia t first brought to a standstill. Up ommencement of the treatment, in 1870, it had steadily increased, een only 1-6½ in October, 1866.

then found: right, My. $\frac{1}{20}$; left, My. $\frac{1}{36}$. Says that "on some days she can see more clearly than on others. On regarding distant objects intently they appear at first blurred, then suddenly grow distinct." Commencing staphyloma posticum is now plainly visible in each eye. Atropine was applied twice daily for six weeks, at the end of which time My. was $\frac{1}{36}$ right, $\frac{1}{72}$ left. Patient now went back to school, and, being both studious and ambitious, was soon absorbed in her work. 1874, June 6th, My. right, $\frac{1}{15}$, left, $\frac{1}{16}$, each staphyloma growing larger, much congestion of optic entrance and retinal vessels.

On summing up my results I find:

In 89.5 per cent. spasm of accommodation.
Of 67 eyes, 15 showed no myopia after atropine.
45 showed less myopia after atropine.
In 7 myopia was unaltered or progressive.
In 55.2 per cent. there was definite improvement.
In 8.9 per cent. myopia was arrested.
In 10.4 per cent. myopia progressed.
In 13 cases (21.3 per cent.) no subsequent information has yet come to hand.

The whole subject, in fine, needs and deserves further investigation and the collection of much more numerous statistics. As far as our present experience reaches, the following conclusions seem to me, as to others, justifiable.

That the emmetropic eye, through undue or disadvantageous use, acquires myopia much more frequently than has previously been supposed, and that such acquired myopia is very apt to be progressive, commencing with spasm of accommodation and going on, through a state of congestion and irritation, to the structural change characteristic of this error of refraction.

That the paralysis of the accommodation by means of atropine, persisted in during a period of several weeks, and furthered by rest of the eyes, shaded glasses, and, in extremely aggravated cases, by local blood-letting, offers a reasonable prospect of preventing the progress of the myopia, in some instances of lessening its amount, and, in occasional recent and slight cases, of removing it altogether.

That in cases of progressive myopia it is reasonable to expect positive results from an annual course of treatment similar to the above, carried on during those years which experience has shown to be most favorable to the advance of the myopia, thus enabling the patient to tide over a critical period. It is perhaps in its prophylactic action that the most importance is to be attributed to the atropine treatment.

CASE OF EXTREME MYOPIA. By Henry D. Noyes, M.D., New York.

R. R. H., a boy 15 years old, weighing 98 lbs., of delicate appearance, was brought to me by his parents from his home in Detroit, Michigan, at the instance of Dr. J. F. Noyes.

The boy's father is a man of great strength and stature; his mother is quite small in figure. Neither have any defects in sight. The patient is the sixth child and the only one who has any eye troubles. His health has of late years been tolerably good, but at 6 years of age he had frequent and severe headache.

The manner of the boy indicates that his sight is extremely deficient:—he walks about groping his way. He has learned to read with difficulty, and holds a book so close to his face as to rub the end of the nose over the page; he at the same time inclines the head to one side and uses only the right eye. The eyeballs are set rather deeply in the orbits, the palpebral fissures are of about the usual size, and the left eye has a convergent squint. Nothing in the external appearance of the eyes would suggest the great amount of myopia which was actually found.

Attempts to determine the visual acuteness were at first unsatisfactory; the pupils were then dilated, and the conditions found by the ophthalmoscope were as follows:—The fundus perfectly illuminated, no opacity in the media. The lenses shake, the left lens partially luxated upward, and in the right eye it is possible to look beyond the edge of the lens through the suspensory ligament. It is thus evident that both lenses are small, and the anterior part of the vitreous is fluid. Attempts to see the fundus by the upright image proved abortive.

A combination of two concave glasses, each of two inches focus, was the strongest negative glass I could obtain, and with them the dispersion of light was so great that no illumination and no image could be obtained. The only way of gaining a near view of the fundus was by using a convex lens of two inches focus, either more or less, to magnify the spontaneous aërial inverted image. By this method it was decided, by measuring the distance between my own and the patient's head, when my eye was withdrawn to the greatest distance at which, with the convex glass, a distinct image of the vessels could be preserved, that the myopia must be about one inch. The presence of a decided amount of astigmatism was also recognized. By the customary method of the inverted image, the fundus could be seen to greater extent, and it was found that there was no atrophy of the choroid about the nerve-discs, while at the region of the maculæ there was a brownish discoloration indicating lesion of the choroid. The vitreous clear and no signs of cataract.

The thought occurred to me whether it would not be right to remove the crystalline lenses as a means of abating the myopia. But although appropriate in theory, the attendant risks were estimated to be too high to justify the proceeding.

I ordered the following glasses: for distance, Right —1 spherical —6 cylindrical, axis 180°; Left —$\frac{5}{6}$ spherical —4 cylindrical, axis 180°.

With these, using only one eye at a time because of the converging strabismus, he had V. = $\frac{20}{100}$.

For reading I employed a pair of Steinheil's cones, each having 4½ inches negative focus. They were mounted ingeniously by Mr. Hunter in a frame which permitted them to be adjusted to the needful angle of convergence and to the correct distance from each other. They were set in blackened sheets of brass and in a spectacle-frame.

With their help the boy could read S. 5 at 6 inches. With an ordinary concave glass of this focus he could read but little better than with his unaided eye. In this exceptional case the magnifying power of the Steinheil glass conferred a great advantage. The cones were about an inch in length, and at the convex end about ½ an inch in diameter, while the concave end

had about ¼ inch diameter. They constitute small Gallilean telescopes.

The awkward appearance and weight of these glasses makes it usually impracticable for patients to use them, but the patient was not only willing but delighted to wear them.

I subsequently learned that when using any glasses he had diplopia. It will not be difficult to correct this by tenotomy of the rect. interni.

Cases of myopia amounting to this degree are extremely rare, although we see cases needing glasses of 2½ and 3½ inches not very unfrequently.

If we attempt to show by calculation what must be the length of the optical axes of these enormously prolonged eyes, and use for this purpose the formula which Mauthner gives, taking the Paris inch, as he does, at 27.1 millimetres, we have for the right eye a length of axis of 37.647 millimetres. In this calculation, as is well known, the standard is Listings' diagrammatic eye, with a length of 22.23 millimetres.

VISUAL ACUTENESS = $\frac{17}{8}$ to $\frac{47}{16}$. DR. B. JOY JEFFRIES, Boston.

To avoid needlessly adding to our Transactions, I must, in connection with this article, refer to my previous ones in the Transactions of our Society for 1869, p. 43, and in the Report of the London Ophthalmological Congress, 1872, p. 121. I would also refer to Giraud-Teulon's remarks on my first article in the March-April number, 1872, p. 218, "Annales d'Oculistique," as well as Dr. J. Gayat's article in the Congress Report, p. 190.

July 15, 1874, I have tested my vision again in the same locality and under similar conditions; namely, the thermometer standing at nearly 90° in the shade, where I was placed, and the test-types in the sun, except as will be mentioned. I was in better physical condition at this time than when making the experiments two years ago, reported at the Congress. Where I could not read all the letters, I follow the fraction representing vision with the sign *minus*, and where I could read all the letters more than readily, so to speak, with the sign *plus*.

Dyer's Card in sun, I in shade	V. = $\frac{47}{20}$.	
Snellen's Card in sun, I in shade	V. = $\frac{47}{20}$.	Same, white letters or black.
Green's Long Horizontal Card in sun, I in shade.....	V. = $\frac{47}{20}$,	and $\frac{47}{16}$, reading the letter T.
Green's Long Vertical Card in sun, I in shade.....	V. = $\frac{47}{20}$.	
Green's Long Vertical Card in sun, I in shade.....	V. = $\frac{38}{16}$ —.	
Green's Long Vertical Card in sun, I in shade.....	V. = $\frac{35}{16}$ +.	

Green's Long Vertical Card in sun, I in shade..... V. = $\frac{27}{18}$.
Green's Long Vertical Card in sun, I in shade..... V. = $\frac{22}{10}$.
Green's Long Vertical Card in sun, I in shade..... V. = $\frac{17}{8}$.

It will be noticed that V. decreased as I went down the card, sustaining a criticism I made in reference to these test-types five years ago.

Dyer's Card in the sun, I in the shade within the house..... V. = $\frac{58}{30}$ +.
Dyer's Card in the sun, I in the shade within the house..... V. = $\frac{72}{40}$ +.
Green's Long Horizontal Card in the sun, I in the shade within the house ..... V. = $\frac{72}{40}$ to $\frac{72}{32}$.
Dyer's Card in changing sun and shade from moving foliage, whilst I looked through a series of rooms, My..... V. = $\frac{100}{50}$.
Dyer's Card in changing sun and shade from moving foliage, whilst I looked through a series of rooms, My..... V. = $\frac{90}{40}$ —.
Dyer's Card in changing sun and shade from moving foliage, whilst I looked through a series of rooms, My..... V. = $\frac{70}{30}$.
Dyer's Card in changing sun and shade from moving foliage, whilst I looked through a series of rooms, My..... V. = $\frac{53}{20}$ —.

In making these experiments, I took the same precautions as before, not to be familiar with the letters—even writing them down as I saw them, and comparing them afterwards with the tests. One peculiarity I noticed worth mentioning to any one trying their vision. I found it would not do to look down at my paper and write the letter seen, as then the ciliary muscles would not relax my accommodation very readily, and it was some seconds before the focus was adjusted for distant vision or parallel rays. Moreover, the sudden changing quite threw me out in my experiments—producing decidedly uncomfortable fatigue.

I have thus again recorded my vision far above $\frac{20}{20}$, notwithstanding Giraud-Teulon's expressed doubts. I therefore would once more ask, is my vision so very much better than practised emmetropes? I should have lost half my visual power, as we now measure it, to have read the twenty-feet test-types at that distance only.

A NEW MODIFICATION OF THE OPHTHALMOSCOPE. By E. G. Loring, Jr., New York.

As it is considered by some an improvement to have the glasses covered, the following instrument was devised, which, it was hoped, would meet this requirement and at the same time



leave the number of the glasses open to inspection, so that their relative positions could be told at a glance and the required

number turned to at once. This object was obtained by having the cover in the shape of a thin, flat ring which swings round a pivot, as seen in the drawing at the point *a*.

The cover when closed is kept firmly in position by sliding with a little pressure beneath the peg, *b*. A spring is countersunk in the upper part of the handle, which bears on the disc so as to keep it firm, and serves at the same time to centre each glass by dropping into a small hole beneath it. The disc can be rotated either with or against the sun, and can, if occasion require, be turned by the forefinger without removing the instrument from the eye. To clean the glasses, the cover is simply made to swing round the pivot at *a*, in the direction shown in the drawing by the dotted line, when, on reversing the instrument, the disc drops out of itself. There are no loose screws about the instrument. Its price, as made by Mr. H. W. Hunter, 1132 Broadway, New York, is $30.

DESCRIPTION OF THE FIGURES,

ACCOMPANYING DR. W. F. NORRIS'S CASES OF OPTIC NEURITIS.

I. Sarcoma of the Cerebellum.

II. A portion of the Tumor teazed out and magnified 550 diameters, showing large polynucleated cells, smaller granular ones, and scanty fibrillar matrix.

III. Section of Choked Disc, stained with carmine, magnified 36 diameters.

IV *a*. Nerve Fibres teazed out from a similar section to the foregoing, with large spindle-shaped varicosities.

b. Flat ovoid Nuclei of Connective Tissue, 550 diameters.

V. Optic Neuritis from Lead Poisoning, 36 diameters.

1.

Faber pinx.t

F. Meisenbach Phil.a



2.



4.

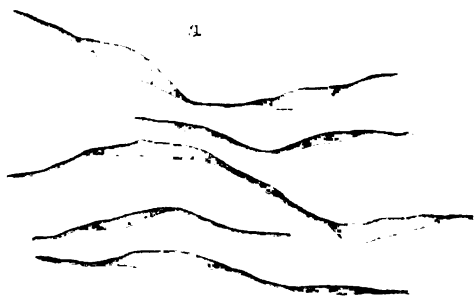

5

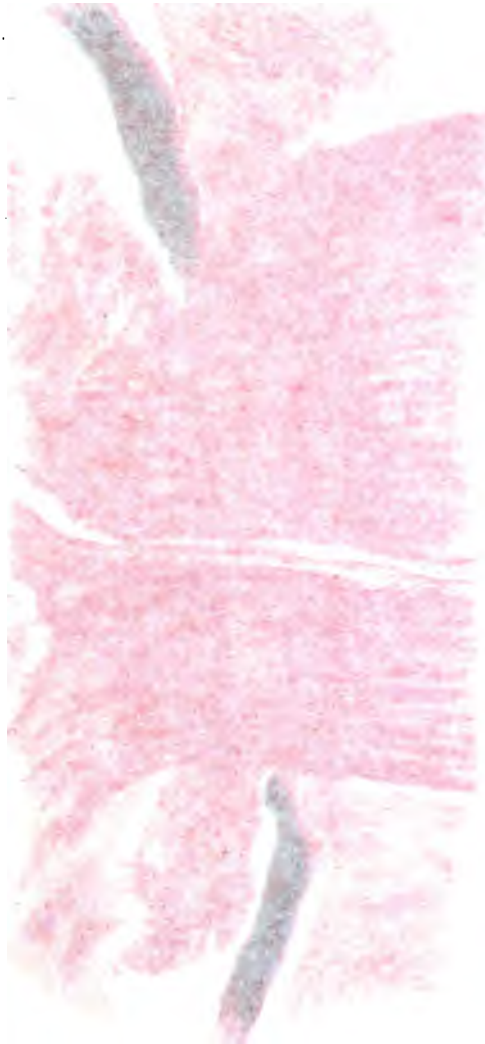



3.

H. Faber pinxt

F Moras lith Phila

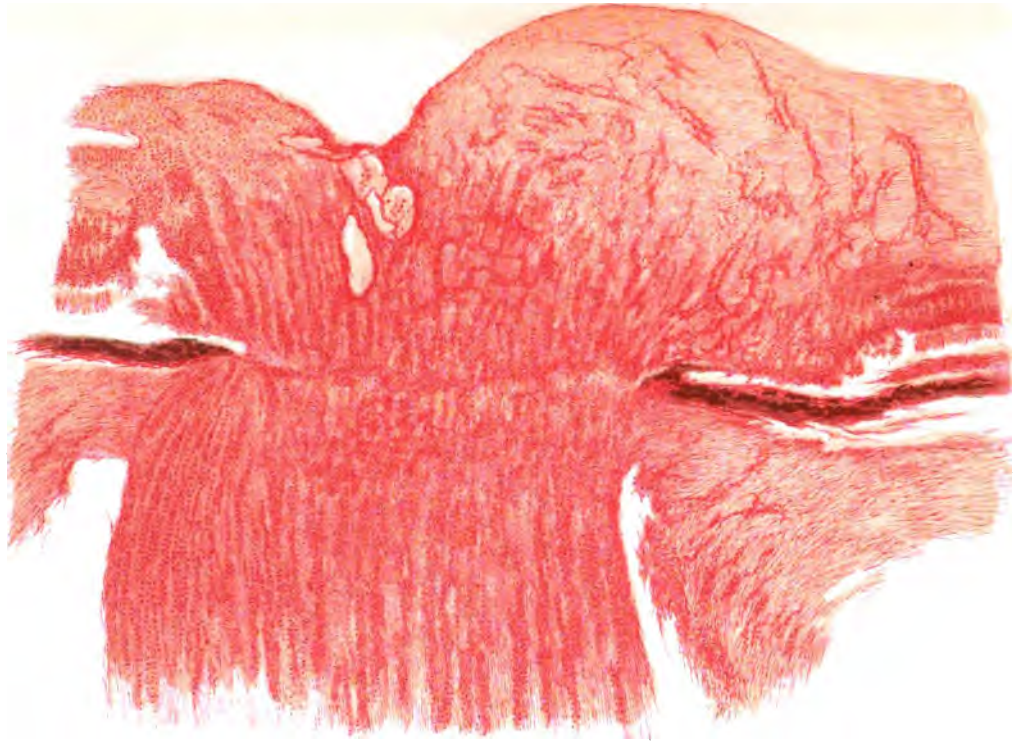

5

H. Faber pinxt

F. Meras lith. Phil.a

CASES OF OPTIC NEURITIS. By William F. Norris, Philadelphia.

I. OPTIC NEURITIS FROM CEREBELLAR SARCOMA.

A. J. A., æt. 28, born in Philadelphia, and clerk by occupation applied for advice at the Wills Hospital in November, 1873. He states that two years ago, last June, when walking home from his work, he was attacked with severe pain in the occiput, shooting forward into the forehead. This recurred from time to time, and he soon became subject to nausea and vomiting, which was especially apt to occur on rising in the morning. Although he gradually became more feeble and suffered from severe attacks of headache and nausea, he was nevertheless able to continue his work until two months ago, when, on entering the house, he suddenly staggered and fell; his hands were at the time feeble and tremulous, but his mind remained perfectly clear. His sight soon became so dim that he was unable to do any work, and his gait, which had been unsteady ever since his first attack, was now so tottering that he could scarcely walk even with the aid of a cane.

At the date of his admission to the hospital he was pallid and rather obese; his intellection was slow but unimpaired, and he complained of failing sight, intense headache brought on by any slight exertion, morning vomiting, dizziness, and pain along the lower margin of the ribs on both sides. He had a vacant, staring look, partial dilatation of both pupils, paresis of both external recti—most marked on the right side—together with feebleness of the lower limbs and great difficulty in co-ordinating their movements. When endeavoring to walk to any given point he always brings up considerably to the left of it. Vision in the left eye $\frac{10}{c}$; in the right, counts fingers at a few

feet. Ophthalmoscopic examination showed that the discs were very prominent and their normal boundaries entirely obscured. Both showed a large development of capillary vessels; that of the right eye, however, was commencing to undergo atrophy, having already acquired a bluish-white tint. The summit of the right disc was visible with $+\frac{1}{8}$, that of the left with $+\frac{1}{12}$, and the fundus near the equator of each eye with $+\frac{1}{48}$. He remained for a considerable time in the house without essential change, subject at times to intense headaches in which his pulse would vary from 90 to 116, and his temperature under the tongue from 98° to 100.5°. At such times even the slight strain caused by the contraction of his abdominal muscles in endeavoring to pass his water occasioned intense pain in the head, and this was still more marked in the act of defecation. These paroxysms were also attended with marked deterioration of sight, and he would sometimes for several hours lose all perception of light. Once, after walking from the water-closet to his bed, he was entirely unable for some time to move either legs or arms. Subsequent to this attack there was intense headache on the slightest motion, and great dimness of vision. At times he complained of seeing stone walls covered with purple vines, and occasionally a medley of horses, coaches, etc. There was a partial loss of sensibility and motion on the right side of the face, and he would sometimes complain that that cheek "got in his way while eating." The amount of squint also varied from time to time. He gradually became weaker and weaker, and died on the third of April, so quietly that neither the attendants nor the patients in the ward marked the exact time. An autopsy was made seven hours after death. There was marked rigor mortis, considerable discoloration of the extremities, and marked settling of blood about the ears and head. The veins leading from the diploe to the scalp were gorged with black blood, as were also the veins and sinuses of the dura mater. There was no trace of meningitis, and the brain seemed healthy, except that its ventricles were distended with clear serum, and that there was a large quantity of the same fluid in the arachnoid cavity.* The cere-

* Spinal and cerebral. After removal of the brain, an abundance of it welled up out of the spine.

bellum was externally healthy, but on incising it there appeared a bluish-gray tumor extending transversely through it with numerous bright red vessels ramifying in its substance. (Vide Fig. I.) The roofs of the orbits were broken through and the posterior halves of the eyeballs removed together with the entire length of the optic nerves. The optic papillæ were prominent, of a dusky grayish-white color, and their boundaries hazy and indistinct. The outer sheaths of the optic nerves were considerably distended, especially at their peripheral extremities, a condition better shown by the accompanying wood-cut than by any verbal description. A fresh piece of the cerebellar tumor teased out

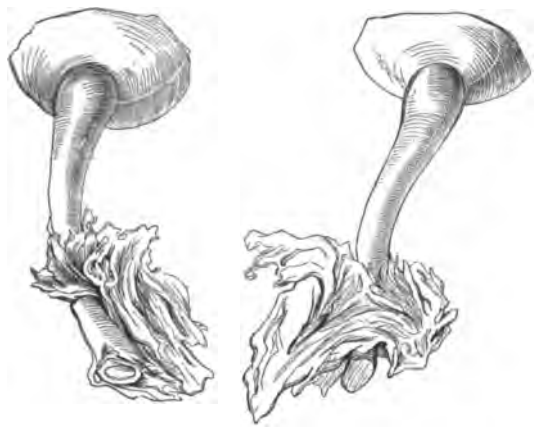

and placed under the microscope showed numerous blood-vessels crowded with colored corpuscles. The cells of the adventitia were large and granular, with large and distinct nuclei. The structure of the tumor itself was better seen on treating the specimen with a dilute solution of nitrate of silver, and showed numerous round cells with granular protoplasm, some about the size of a retinal granule, others larger and polynucleated. These were embeded in a scanty granular, and in places delicately fibrillar, matrix.* Carmine and glycerine gave the same results, but less distinctly than nitrate of silver.

The posterior halves of the eyeballs and optic nerves were

* Fig. II.

hardened in dilute alcohol, and subsequently sections of the same were made, stained with carmine and mounted in balsam. Microscopic examination showed that the disc was considerably swollen, measuring on the dried and mounted specimen $\frac{1}{10}''$ from the level of the choroid to the summit of the papilla. The lamina cribrosa was also swollen, bulging forward into the eye, and the whole tissue stained deeply and intensely with the carmine solution—far more intensely than a healthy adult nerve, but recalling vividly the aspect of a similar section made through the optic nerve of a fœtus (embryonal tissue. (Vide Fig. III.) Some sections of the swollen disc were carefully teased out with needles, and the nerve-fibres showed numerous spindle-shaped swellings which stained with carmine more deeply than the rest of the fibre. (Fig. IVa.) Adhering to the nerve-fibres were very numerous ovoid flattened nuclei, evidently belonging to the interstitial connective tissue. (Vide Fig. IVb.) There were numerous newly formed blood-vessels, and their adventitia was thickly studded with large granular nuclei. It was principally to the abundance of the nuclei of the connective tissue, and to those in the walls of the numerous blood-vessels, that the opacity of the tissue and its intense staining were due. The trabecular network found in the subvaginal space seemed more abundant than usual, and its nuclei stained deeply with carmine. (Fig. VI.)

There was, however, no such massing of this subvaginal connective tissue as to cause any distension of the outer sheath of the nerve. This had evidently been produced by the increased quantity and pressure of the subarachnoid fluid.

As tending to confirm this view, it may not be out of place to remark that a pear-shaped dilatation of the bulbar end of the optic nerve (similar in appearance to that above figured) is readily produced in the cadaver by inserting the nozzle of a syringe between the outer and inner sheaths and forcibly injecting any fluid.

II. A CASE OF OPTIC NEURITIS FROM LEAD-POISONING.

The clinical history of this case has already been published by Doctor J. H. Hutchinson, in the *Philadelphia Medical*

Times, January 17, 1874, and it is to his kindness that I am indebted for the opportunity of studying it. I will therefore recapitulate briefly its clinical aspect, and pass on to a discussion of its microscopic appearances. The patient was a young woman poisoned by the application of white-lead to the skin as a cosmetic. M. C., æt. 23, enjoyed good health until two months previous to her admission to the Pennsylvania Hospital, when she began to suffer from headache and loss of appetite, followed by violent gastric pain, nausea, and vomiting. At the time of admission to the hospital, there was a marked blue line in the gums, and soon after she was seized with epilepti-form convulsions, and died in the third. Between these paroxysms, I made with some difficulty an ophthalmoscopic examination of the right eye. The disc was prominent, its outlines were hazy, its color an opaque bluish-white, sclerotic ring not visible, and the vessels diminished in calibre. There were no choroid changes. Doctor Hutchinson made a careful autopsy, and reports that the veins and sinuses of the dura mater were gorged with fluid black blood; that the brain substance was exceedingly anæmic and the gray matter of rather a yellowish hue, and that there was a marked increase in the quantity of the cerebro-spinal fluid. The membranes of the brain were entirely healthy. The posterior halves of the eyeballs were handed to me for examination. The outer sheath of each nerve was distended, and the bulbar extremity pear-shaped. The optic papillæ were prominent, bluish-white, and opaque, the sclerotic ring not visible, and there were no choroidal changes. After careful hardening, longitudinal sections were made of the nerve and the optic disc. The distance from the level of the choroid to the summit of the disc measured $\frac{1}{18}''$. There were numerous capillary vessels throughout the swollen disc, their walls studded with large granular nuclei, and a moderate development of the ovoid flattened nuclei of the connective tissue. (Vide Fig. V.) In specimens carefully teased out, the nerve-fibres themselves appeared to be nearly normal, for, although a few of them exhibited in places a slight increase of diameter at some places where they also stained more deeply with carmine, there was, nevertheless, nothing at all comparable to the large varicosities and spindle-shaped swellings found in the nerve-fibres of the first case.

The subvaginal connective tissue was apparently in a state of nutritive hyperplasia, and stained deeply with carmine.

In both of the foregoing cases sections were made of the posterior portions of the optic nerves, and compared with those obtained at the optic entrance, and in both (although this was better marked at the bulbar extremity) there was obviously throughout an increase of the interstitial connective tissue beyond the normal amount, while the unusually intense staining of its too numerous nuclei bore witness to the increased activity of its protoplasm. In short, all sections forcibly recalled the appearance of similar portions of the fœtus, having by inflammatory hyperplasia assumed an embryonal appearance.

The excess of cerebro-spinal fluid and the dilatation of the outer sheath of the optic nerves, and consequent increase of the subvaginal space, would seem to show that in these cases at least the choked disc had been produced by the pressure of the subarachnoid fluid at this point. It might be supposed that if this were the case, and the choking due to the action of this mechanism already so fully elucidated in the labors of Schwalbe, Schmidt, Manz, Michel, and others, that the inflammatory changes would be limited to the region of the lamina cribrosa. We have found, however, that although most intense at that point in its vicinity, they were not limited to it, but extended backward throughout the orbital portion of the optic nerve. This we can readily account for when we consider that Schwalbe as well as Axel Key, and Retzius, have demonstrated that fluids injected into the subvaginal space readily pass into the lymph spaces in the interior of the nerve, which surround and separate the individual nerve-fibres, thus producing throughout its length œdema and nutritive hyperplasia.

Tumors of the cerebellum and of the posterior portions of the hemispheres of the cerebrum appear more apt to produce choked disc than those of the anterior lobes. The cranium is a closed cavity, and any increase of its contents, if they were all fluid, would press equally in all directions. But inasmuch as the brain is a soft solid, this law does not hold good, and tumors of the cerebellum, bound down by the tentorium, by their direct pressure on the fourth ventricle cut off all communication between the lateral and third ventricles of the brain and the sub-

arachnoid space of the spinal cord, and thus dam up fluid in the former. Moreover by compressing the lateral sinuses of the dura mater, they readily cause leakage of the watery parts of the blood, and are thus specially prone to increase the subarachnoid fluid.

It is perhaps worthy of remark as a clinical fact, that the temperature in the first reported case never, even in his most violent paroxysms of pain, rose above 100.5°, and the autopsy showed an entire absence of meningitis. Had it been present it would probably have been indicated by a more decided rise of the thermometer.

ON THE CIRCULATION OF THE OPTIC NERVE AND RETINA IN DISEASE OF THE SPINAL CORD AND MEMBRANES DEPENDENT UPON CARIES OF THE VERTEBRÆ. By CHARLES S. BULL, M.D., New York.

THE clinical observations contained in this short paper were made upon a series of eleven cases, all children, who were inmates of the Hospital for Ruptured and Crippled, in New York. They were all of traumatic origin, the primary lesion being a caries of the spinal vertebræ, involving one or more vertebræ, mostly in the cervical region, but occurring also in the dorsal and lumbar regions. No attempt is made to explain the cause of the disturbance in the circulation of the optic nerve and retina, and the cases are only presented in the hopes of eliciting some information.

The *first* case was a young Jewish boy, 4 years of age, with caries of the dorsal vertebræ from the 6th to the 12th inclusive. He is one of six children, the rest of whom are perfectly healthy; but this child had been rather feeble from birth. When he was about two years old, he met with a severe fall, striking on his back, and since then he has never been able to walk. The child had two large abscesses in the inguinal regions of both thighs, and a convergent squint of 3 ‴ in the left eye, which, the parents say, appeared soon after the accident. An ophthalmoscopic examination, after atropine, showed a hypermetropia of $\frac{1}{24}$, which might account for the squint. Both optic papillæ were of a deep red, the retinal veins were very much engorged and tortuous, the arteries apparently normal in calibre. The retinæ of both eyes were thrown into minute rugæ or folds separated by unequal distances. The minute vessels of the pa-

pillæ were undoubtedly increased in size and perhaps in number, as shown by the deep-red color.

The *second* case was a boy, 3½ years of age, with caries of the cervical vertebræ from the 4th to the 7th, which dated back to a fall about six months before. An abscess had made its appearance deep in the neck on the left side, which had been opened about one month before I saw him, and was still discharging a fetid pus. The ophthalmoscope showed a deeply congested appearance of the entire fundus in both eyes, with enlarged and tortuous retinal veins, and a similar appearance of the arteries, though to a less degree. The refraction was emmetropic.

The *third* case was a boy, 11 years of age, with caries of the middle and lower dorsal vertebræ, of traumatic origin, and of eighteen months' standing. There was no paraplegia either of motion or sensation, but the boy never walked since the accident, because of the pain caused by the motion of the vertebræ upon one another. There was an abscess extending from the trochanter major to the patella on the right side, and the house physician suspected amyloid degeneration of the kidneys. There were never any head symptoms at any time. Both eyes have the appearance of neuritis descendens, with marked effusion into the disc and retina, giving them a sodden, yellowish-white appearance. The veins were very tortuous and much engorged, the arteries quite small, and the outline of the disc was entirely lost in both eyes.

The *fourth* case was a boy, 10 years of age, with caries of the middle and lower dorsal vertebræ, of traumatic origin, dating back seven years. The father of the child died of pulmonary tuberculosis, and two children of the same family died of cerebral disease. In this patient both optic discs were markedly anæmic, particularly in the left eye. The arteries and veins of the retina were both reduced in size, and the retina so devoid of pigment that the choroidal vessels were plainly visible all over the fundus, which was very unusual, as the patient was a dark brunette. The refraction was $+ \frac{1}{20}$.

The *fifth* case was a boy, 14 years of age, with caries of the dorsal vertebræ, from the 1st to the 7th inclusive, of traumatic origin, dating back five years. The patient has been paraplegic

for nearly two years. He at one time recovered the power of motion in his legs, then lost it again, and he is now slowly regaining it. The ophthalmoscope showed a high degree of hyperæmia of the optic papillæ, with engorged and pulsating retinal veins, but no exudation into the retina, and no alteration in the arteries.

The *sixth* case was a boy, 9 years of age, with caries of all the lumbar vertebræ of fourteen months standing, dating from a heavy fall three years before. There is no paraplegia, but the boy is bent over forwards and has some difficulty in walking, from a very marked contraction of the tensor vaginæ femoris.

In this patient both papillæ were very anæmic, almost as much so as in progressive atrophy, yet the retinal veins were engorged and tortuous, and the outlines of the disc indistinct. Refraction —36.

The *seventh* case was a boy, 14 years of age, with caries of nearly all the dorsal vertebræ, and a marked displacement of the spinal column towards the left side. This patient fell through a hatchway nine months before I saw him, struck on his back, and was paraplegic from that time. About two months ago he began to walk, and the improvement in this respect has been constant. Both optic discs were very much congested, with an enormous development of vessels upon the disc and retina, but no pulsation. Refraction emmetropic.

The *eighth* case was a boy, 7 years of age, with caries of the vertebræ from the 6th cervical to the 4th dorsal, of four years' duration, and traumatic origin. He has been paraplegic for seven months. For some two years he has had symptoms of renal disease, and has suffered at times from incontinence of urine. The pressure on the spinal cord is gradually diminishing and the spinal nerves are slowly regaining power. In the right eye the optic disc was intensely hyperæmic, its outline indistinct, and the veins engorged and tortuous. In the left eye there was the same condition of affairs, though less marked. In this eye there was a venous pulsation. The patient complains a great deal of photophobia and pain in the eyes.

The *ninth* case was a girl, 2 years of age, with caries of the cervical and dorsal vertebræ of three months' standing. She can walk a little, but drags the left leg behind the other. Com-

plains of pain in the back, and always lies on the right side. There was a very marked hyperæmic condition of the optic papillæ, with immensely distended and tortuous veins, and a pulsation in both branches of the vein in the left eye.

The *tenth* case was a girl, 4 years of age, with caries of the middle dorsal region, involving three vertebræ, of six months' standing. The dorsal projection is very prominent, but the child complains of no pain except when the back is touched. There is no interference in the movements of the muscles of the lower extremities, and the child is well nourished and in good condition. The optic papillæ were deeply congested except at the centre. The central veins were very much engorged, but the chief feature was the very marked increase in size of the capillaries of the disc, some of which could be seen with the naked eye. There was no exudation of any kind into the retina, the media were perfectly clear, and the refraction emmetropic.

The *eleventh* case was a boy, 5 years of age, with caries of the dorsal vertebræ of one year's duration, involving the 6th, 7th, 8th, and 9th vertebræ. The child has never complained of any pain, but is completely paraplegic, and is very much wasted away. In the right there was a marked interstitial atrophy of the hexagonal pigment cells of the retina immediately around the nerve. The nerve-entrance was somewhat hyperæmic, but not markedly so, but the veins were enormously engorged and very tortuous, and pulsated for some distance beyond the margin of the disc. In the left eye there was the same interstitial pigment atrophy, and the disc and veins were equally engorged, but there was no pulsation. The arteries in both eyes were not apparently altered in calibre.

SYPHILITIC GUMMA IN THE CILIARY BODY. By Edw. G. Loring, Jr., and H. C. Eno, New York.

The patient was a well-developed woman of thirty years of age, and at the time of the attack was apparently in perfect health, and without the slightest signs of a syphilitic cachexia. Five years before, she had had a chancre, for which she had been treated in the regular way. The primary lesion was followed by the usual secondary, and these in their turn by the so-called tertiary, symptoms.

Three years after inoculation, and two years before the present trouble, the patient suffered from an attack of iritis in both eyes, and they had remained "weak" ever since.

The present attack was ushered in by similar symptoms, and the belief on the part of her attending physician was that the patient was suffering from a second attack of iritis. The trouble was, however, confined entirely to the left eye. The injection of this eye gradually increased for about a week or ten days, unaccompanied, however, by much pain or loss of vision. The patient was, however, shortly after awakened at night by a sudden and very violent attack of pain with a very rapid loss of sight, which in a day or two resulted in total blindness. Becoming alarmed, the patient presented herself at the Eye and Ear Infirmary, where I saw her for the first time, about two weeks after the beginning of the attack.

The right eye at this time appeared to be perfectly normal in every respect. The left was very much injected, and the conjunctiva, besides being very much inflamed, seemed, in conjunction with the sub-conjunctival tissue, to be thickened and œdematous, especially to the outer side of the eye. The

anterior chamber was filled by a yellowish exudation, so that the iris was concealed from view. The cornea was, however, free from any ulcerative process, and the epithelial layer was intact. There was no perception of light.

As the patient was suffering violent pain in and around the eye, and as she would not consent to have the eye removed without the consent of her friends, it was decided to do a free paracentesis. This was done with a Graefe's knife, a free incision being made in the lower margin of the cornea. The anterior chamber was thoroughly evacuated. This was followed by a great relief of pain.

The wound, however, gradually closed, and with its closure the pain returned, and the exudation began to reappear in the anterior chamber. The other eye (the right), which up to that time had shown no trace of any trouble, began now to be somewhat sensitive to light, and to show other symptoms which seemed to be of a sympathetic nature. Enucleation was therefore performed, and the eye given to Dr. Eno, whose description of the examination will be found below.

The enucleation of the left was followed by an amelioration of the condition of the right eye, so far as the dread of light was concerned; but four days after the operation a small circumscribed elevation began to make itself apparent in the line of the insertion of the rectus externus, but somewhat closer to the cornea. This had the appearance of a circumscribed elevation of the sub-conjunctival tissue, the conjunctiva proper being but slightly injected just over it. This injection of the conjunctiva proper gradually increased, following the line of the rectus externus muscle, till, within two or three days, it had spread out in a fan or cone like shape, the base of which was toward the external canthus, and the apex, sharply defined, towards the cornea.

At this time a serous exudution underneath the conjunctiva began to make its appearance, being limited to the external and lower part of the eye. The injection of the eyeball gradually extended round the cornea, above and below, till it had included the whole eye. Still the region over and around the tendon of the externus was the seat of the most marked symptoms of the trouble, and from the serous

exudation it was supposed that something was interfering with the circulation of both the superficial and deeper parts of this portion of the eye. At this time a grayish, spongy exudation began to be apparent over that part of the iris opposite the insertion of the externus rectus. This extended itself pretty rapidly in a circuit round the upper portion of the iris, so that on the day after it had been first noticed the exudation had extended over about two-thirds of the entire membrane, leaving the outer and lower parts unaffected. This exudation had a very peculiar appearance, looking more like mould of a grayish yellow color than anything I can compare it to. It projected over the edge of the iris into the pupillary space; and vision, which had hitherto remained good, now sank rapidly, so that the patient could barely count fingers at four feet. On the following day this semi-transparent exudation had extended all round the iris and was occupying the greater part of the anterior chamber. Through it the iris could be dimly seen, of a dull velvety hue. Vision was so bad that fingers could be barely counted at a foot and a half. The pupil was contracted, though not markedly so, and there were no adhesions to the lens, as was afterwards shown by the free dilatation of the pupil under atropine. Specific treatment had from the first been pushed vigorously without apparently checking the progress of the disease, and great fears were entertained that the eye would follow in the same course as its fellow.

On the following day, however, the exudation began to be absorbed, and disappeared so rapidly that within thirty-six hours after its commencement the anterior chamber was entirely free from it. Vision immediately rose and the eye made a steady and rapid recovery.

The left eye was placed in Müller's fluid immediately after enucleation. The eyeball appeared normal in size and shape, with the exception of a very considerable thickening of the episcleral tissue at the outer side of the cornea, and over the insertion of the rectus externus. The cornea was opaque, and there was a large cicatrix in the lower portion of it. At the end of two weeks the eye was removed from Müller's fluid and opened by a section passing nearly through its horizontal

meridian. The antero-posterior diameter of the eye measured 26 mm., the transverse diameter 25 mm. As seen in this section, the episcleral tumor above-mentioned is about 1½ mm. in thickness, and extends back nearly to the equator of the eyeball, inclosing in its substance the tendon of the rectus externus. The anterior chamber is filled with a mass of yellow exudation completely blocking up the pupil. The iris and ciliary body are enormously increased in size, but especially at the outer portion of the eye corresponding to the external swelling; here the iris measures 1½ mm., and the ciliary body 3–4 mm. in thickness; here also the substance of the iris and ciliary body seems to be continuous with the mass of exudation in the anterior chamber, the ligamentum pectinatum iridis being broken through. The ciliary tumor is of quite firm consistence and yellowish in color. It extends backwards to the region of the ora serrata, where it gradually is lost in the choroid, which appears to be but slightly increased in thickness.

The lens is transparent and normal in appearance, but pushed over to the nasal side by the swelling of the ciliary body on the opposite side of the eye. The vitreous is cloudy. The retina and choroid are in place. The sclera is normal in appearance, and may be seen as a white band separating the intra from the extra ocular tumor. (See accompanying plate, Fig. 2.)

Microscopic examination shows that the episcleral tumor is due to an infiltration of the episcleral tissue, with a multitude of round cells. The cells are distributed between the fibres of the connective tissue, and the blood-vessels of this region are enlarged and engorged.

At the limbus a collection of cells is so disposed as to separate the lam. elast. ant. with the superjacent epithelium from the corneal tissue for a considerable distance. The rest of the cornea presents the appearances of moderate keratitis. The anterior chamber is filled with a mass composed of round cells and coagulated fibrine. The outer layers of the sclera are invaded by the cell-growth, and throughout its whole thickness collections of round cells may be seen lying between the bundles of fibrous tissue.

Thin meridional sections were made through the centre of the

ciliary tumor, and the iris and ciliary body were found to be infiltrated with a great quantity of the same small round cells as exist in the episcleral tumor. (Fig. 1.)

In that portion of the ciliary body near the sclera, the cells are distributed between the bundles of muscular fibres; and as we pass toward the inner surface of the ciliary body, they become more numerous, separating the muscular bundles more and more widely, until, at the inner margin, we can distinguish only a mass of cells thickly packed together and traversed by an occasional capillary vessel. These cells are identical in appearance with the so-called exudation, or lymphoid cells, being about the size of a white blood-corpuscle and containing a granular nucleus. In no portion of the tumor do they present the appearances of granular or fatty degeneration.

In the iris the cells are very abundant, and in those portions most affected it is scarcely possible to recognize any element of normal iris tissue, except the pigment. The inner and under surface of the ciliary body and iris are also thickly covered with masses of round cells. The vitreous is filled with round cells and coagulated fibrine.

The retina and choroid of the posterior portion of the eye were examined, but presented no unusual appearances beyond those of an inflammatory condition.

In view of the clinical history and pathological appearances of this case, it must be regarded as one not merely of Iridocyclitis syphilitica, but also of syphilitic gumma of the ciliary body and iris. For though the lesions do not differ essentially in kind from those of a simple inflammatory origin, still their intensity and circumscribed character together with the formation of a distinct tumor justify the name *gumma*, notwithstanding the absence of retrogressive metamorphosis.

The observations of three similar cases have been recorded, one by Von Hippel (Graefe's A. f. O. viii. p. 288), two by F. Delafield (Transactions of the American Ophthalmological Society, 1871); but in all these cases the disease was more advanced and the changes more extensive, involving all the tissues of the eyeball.

Fig 1 Section through ciliary region, showing ciliary tumor and episclerial tumor &c

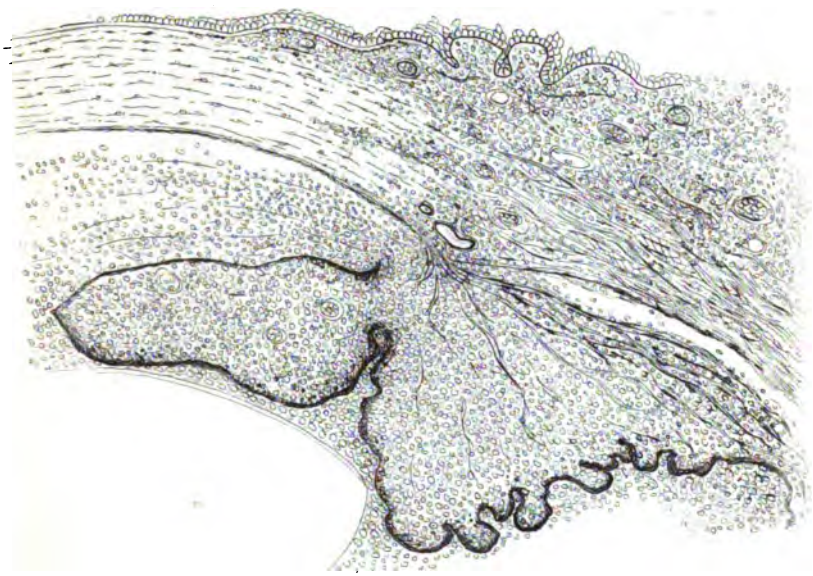

Fig. 2. Section of eyeball, natural size.

H. C. Eno del. et sculp.

ON COLOR-TESTS FOR AMETROPIA, BASED UPON THE CHROMATIC ABERRATION OF THE EYE.

By JOHN GREEN, M.D., St. Louis, Missouri.

THE following brief paragraph from Dr. Thomas Young's *Bakerian Lecture*, published in the *Philosophical Transactions* for 1801 (page 50), seems not to have received from later writers the attention it deserves:

"Dr. Wollaston mentioned [to me] a very elegant experiment for proving the dispersive power of the eye. He looks through a prism at a small lucid point, which of course becomes a linear spectrum. But the eye cannot so adapt itself as to make the whole spectrum appear a line; for, if the focus be adapted to collect the red rays to a point, the blue will be too much refracted, and expand into a surface; and the reverse will happen if the eye be adapted to the blue rays; so that, in either case, the line will be seen as a triangular space."

An observation by Wollaston, confirmed by Young, needs no verification; it is scarcely necessary to state that the experiment is elegant, and conclusive upon the point in proof of which it is presented. It is, moreover, to me, the most striking and perfect illustration of the non-achromatism of the eye with which I am acquainted, and it will, as I think, be found of value, also, as a delicate and accurate test for ametropia.

Repeating the experiment with my *left* eye by looking through an ordinary glass prism of 60°, with the refracting edge horizontal, at a bright star, a distant street-lamp, or even a very small taper flame or gas-jet placed at the farther end of a long room, I see the spectrum narrow or pointed at the red extremity and progressively wider to the extreme violet end. The triangular shape is very conspicuous, and the whole colored

space, streaked by the image of the radiating fibres of the crystalline, presents an appearance suggestive of a conical brush or pencil of rays diverging from a common focus at the red end of the spectrum. No change of accommodative adjustment alters this triangular figure except that by active accommodative effort I am able to expand it in width, so that the red end appears more or less truncated:—it is, in short, the spectrum formed by an eye *emmetropic for red rays, in its horizontal meridian.*

With my *right* eye, looking through the prism in the same position as before, I see the spectrum also widest at the violet end and narrow at the red end; but the narrowest part of the whole spectrum lies not in the red, but in the yellow, thus giving to the spectrum an appearance suggestive of a double cone or pencil of rays having a common apex in the yellow. By a slight effort of active accommodation I am able easily to change the focus of this spectrum, so as to see it as a single cone or triangle with the apex at the red extremity, and any further accommodative effort only serves to expand the whole spectrum in width, as already noticed in the case of my *left* eye. The spectrum as seen by my *right* eye, then, is the spectrum formed by an eye *emmetropic for yellow rays, in its horizontal meridian*, and therefore *slightly hypermetropic*, in the same meridian, *for red rays.*

Placing a convex glass of 144 inches focus before my *right* eye, its vision becomes practically *emmetropic for red* rays, and correspondingly *myopic for yellow;* this glass expresses, then, the measure of the chromatic aberration in my *right eye* for these two colors. So also a concave glass of 144 inches negative focus placed before my *left* eye renders this eye *emmetropic for yellow*, and correspondingly *hypermetropic for red rays.**

To measure the total chromatic aberration in my eyes, I place before my *left* eye [Em. for red] a concave glass of 20 inches

* By another method Dr. Young estimated the difference of refraction in the eye for red and yellow rays as equal to the refraction of a lens of 132 inches focus, a measurement not very different from that which I have found, viz., $\frac{1}{144}$. Dr. Young says, however: "I cannot observe much aberration in the violet rays. This may be in part owing to their faintness; but yet I think their aberration must be less than that of the red rays."—*Op. Cit.*, p. 51.

negative focus and look again at the spectrum of the point of light. All now appears changed; the spectrum is still seen triangular in form but in a reversed sense, the violet end being the apex and the red end the base. A weaker concave glass does not suffice to bring the violet end quite to a point, while with a stronger glass I can cause the violet apex to appear visibly broader, or truncated, through a voluntary relaxation of accommodation. The total chromatic aberration, then, in this eye must be about $\frac{1}{20}$.

Substantially the same value, $\frac{1}{20}$, is similarly obtained as the measure of the total chromatic aberration in my *right* eye.

This estimate, which is a little less than that given by Helmholtz ($\frac{1}{18}$), is also certainly less than the actual total aberration in my own eyes; the measurements having all been made with ordinary artificial light, which is somewhat deficient in violet rays, and in a city atmosphere always perceptibly vitiated by smoke from bituminous coal.

Exhibiting this experiment to numerous friends, I find that the emmetropes and myopes among them all describe the spectrum of the lucid point as triangular, with the apex red; the hypermetropes, on the contrary, see it with the apex violet, or at any rate with the violet end quite narrow. We have thus a direct and delicate test for ametropia, not dependent upon the recognition of letters, and one which, unlike Steiner's experiment so admirably utilized by Thomson, does not require a large pupil for its application.

In measuring myopia by this method, I have succeeded best by directing the attention to the red apex of the spectrum, the weakest concave glass, through which the apex appears as a sharp red point, being the measure of the myopia for red rays. Adding to this the correction for the brightest part of the spectrum, viz., the yellow, a correction which I have found to be about $\frac{1}{144}$, we have the measure of the actual myopia in the meridian corresponding to the direction of the refracting edge of the prism. Turning the edge of the prism then through any angle, in a plane perpendicular to the axis of vision, and again measuring the ametropia in the new meridian, we detect any difference in refraction, and by thus examining one meridian after another we may work out even very complex cases of asymmetry.

In hypermetropia, also, it has seemed to me most satisfactory to take the red end of the spectrum for observation, noting the strongest convex glass, through which the apex appears perfectly sharp, and applying the correction, minus $\frac{1}{144}$, to obtain the measure of the hypermetropia for yellow rays.

In connection with these experiments it may be observed that a red glass, excluding the more refrangible rays, ought very considerably to improve the definition of distant objects in a slightly myopic eye, provided that the illumination is sufficiently intense. This I find to be actually the case with my *left* eye [M. $\frac{1}{144}$ for yellow] in bright sunlight. So a blue glass, excluding more or less perfectly the less refrangible rays, may positively aid a hypermetrope in reading, by relieving the overtasked accommodation of a part of its burden.

The ordinary red and green lights used as maritime signals may be utilized as tests for ametropia, as I have often observed in the case of the red and green lanterns which are exhibited, in a manner very favorable for comparison, upon the tall chimneys of the Mississippi steamboats. To an emmetrope or a myope the red light appears the smaller; to a hypermetrope the green generally appears smaller than the red.

I have lately constructed a number of test-objects for astigmatism, modified from some which I described several years ago.* I refer to certain test-cards which I exhibited at the meeting of this Society in 1867, viz., perforated discs of blackened card-board, covered, on the back with thin white paper so as to present the appearance, when hung in a window, of bright lines, dots, and rows of dots showing strongly by contrast upon a dark ground. I have found these test-objects more than sufficient to detect the lowest grades of ametropia which can practically concern us, but I have found it difficult to make use of them in many cases, owing to the disturbing influence of strong irradiation. I now prefer to cover the slits or holes in the discs with fine tissue-paper, dyed red with a solution of carmine in ammonia water, and rendered transparent by Canada balsam or white varnish. By this arrangement the confusing

* Am. Jour. Med. Sciences, January, 1867, page 124. Trans. Am. Ophl. Soc'y, 1867 and 1868, page 133 and plate iii. figs. 3, 4, 5, and 6.

irradiation is avoided, and the accurate determination of ametropia in any meridian is greatly facilitated. The correction, $\frac{1}{144}$, must of course be applied to the results thus obtained, in order to arrive at the true measure of the ametropia for yellow rays. Similar perforated discs, showing lines or dots of two colors of widely different refrangibility, such as carmine and ultramarine blue (the former being a very pure red, the latter a strong violet modified by green), may be conveniently employed in repeating the observation made upon the red and green steamboat-lanterns.

Finally the experiment of Dr. Wollaston, by analyzing the chromatic aberration of the eye, suggests a double explanation of its apparent achromatism in ordinary vision. Admitting that in the accurately emmetropic eye the focus (or least circle of aberration) for yellow rays lies at the actual position of the retina, a distant point of light will be projected as a small yellow spot in the centre of a system of concentric colored discs. Of these colored discs, appearing as halos around the bright central yellow, the red and the green are pretty exactly superimposed upon the same portion of the retina, and so give rise to the compound sensation of yellow identical with that produced by the yellow rays of the spectrum. There remain, then, to be considered only the larger circles formed by the blue, indigo, and violet rays. Of these larger circles the central portions, coinciding in extent with the inner compound circle made up of the red, orange, yellow, and green rays, combine with these to make the resultant yellow appear somewhat whiter, while the outer portions of the same circles form a halo of concentric rings, shading from blue-green or blue to violet, around the brilliant yellow or yellowish-white centre. This halo is, however, composed of colors of intrinsically feeble brilliancy, too feeble, in fact, strongly to impress the retina when contrasted with the intense brightness of the yellow formed by the concurrence of the red, orange, yellow, and green rays.

Besides this physiological factor in the apparent achromatism of the eye, the experiment suggests a second, purely physical, in the radiating structure of the crystalline lens. Looking at the point of light through the prism, we observe that the successive prismatic colors are not sharply defined by any distinct

line of demarcation, but are somewhat intimately blended at their junction by lines, of varying degrees of brightness, radiating from a common point at the apex of the triangular spectrum; and it is difficult to resist the conviction that the brilliant yellow rays, thus scattered *by irradiation* throughout the area occupied by the fainter blue and violet halo, are quite sufficient to drown it in a flood of uniform or nearly uniform color.

TWO CASES OF INTRAOCULAR SARCOMA. By O. F. Wadsworth, M.D., Boston.

I. Mrs. S., æt. 28, applied to me at the City Hospital the middle of July, 1871, complaining of some pain and uneasiness about the left eye after reading or sewing. The left pupil was somewhat dilated, and there were dotted opacities on the membrane of Descemet in its lower quadrant. Iris of normal appearance; media clear; posterior portion of fundus (the only part then examined) normal; tension not increased. A slight congestion of the conjunctival vessels to the inner side of the cornea was considered as the remaining sign of a "phlyctenular conjunctivitis," which had been diagnosed by a colleague some two months before. Except some anæmia, the general condition was good. Iron, and atropine locally, were ordered.

Three weeks later only a trace of the dots on Descemet's membrane was to be seen. The anæmia was less. Atropine discontinued.

The next few weeks the eye was comfortable when not used, but after moderate use there was a prickling and dry, hot feeling in the eye, and an ache at the inner and upper part of orbit. September 2d a careful examination of the eye was made. Except one rather large vein running from near cornea toward inner canthus the external appearance was normal. T. normal. V.$=\frac{15}{20}$. The pupil dilated well with atropine. At the inner side of the fundus, so far forward that its anterior boundary could not be made out, a small tumor, of faintly mottled, bluish-gray color, with retinal vessels running over its surface, projected into the vitreous. Near its surface were minute dotted opacities in the vitreous. The rest of the fundus appeared normal.

The patient would not make up her mind to enucleation, and I soon lost sight of her till the end of April, '72. Meanwhile she had occasional uncomfortable sensations in the eyes, chiefly in the right (the sound eye), but only after use; observed a mist before the left, and sometimes phosphenes. The vein at the inner side of the conjunctiva had increased somewhat; otherwise the eye appeared externally normal. T. normal. V.=$\frac{15}{40}$. Vessels of disc apparently normal, but the whole fundus seen as through a faint haze. The tumor had increased much, and now hid the retina to within some 2½ disc-diameters of the nerve; on its surface were a few streaks of hemorrhage. Near it were membranous opacities in the vitreous, and at its lower edge a small separation of the retina. The field of vision showed a defect corresponding to the tumor.

She was again lost sight of till the end of January, '74. The sight failed gradually, and was entirely lost early in the spring of 1873, but the eye retained its natural appearance till the following July, when she gave birth to a child. She was quite well during pregnancy, and labor was natural, but a few hours after labor the eye became painful, reddened, and swollen, continued in this condition for several weeks and then shrank. It had since remained quiet.

Now, the globe so much shrunken that the lids are no longer in contact with it; a groove along the outer and lower part of the sclero-corneal junction, and indentations in the course of the recti muscles; no congestion or discoloration of conjunctiva or sclera; cornea irregular in circumference, much contracted, generally clear, but with a few small, defined, gray opacities, and two or three dots of pigment near the periphery; anterior chamber but little shallower than normal; aqueous clear; iris thin and atrophied, everywhere attached to lens capsule; pupil rather large and irregular; lens cataractous. The movements of globe free; no tenderness on pressure.

As the patient now considered the eye "neither useful nor ornamental," it was enucleated February 7th, '74.

Immediately after the operation the cut surface of the nerve, ½″ behind the sclera, showed no pigmentation to the naked eye, but on dividing the eye in the horizontal meridian on the

following day, a brownish streak was seen to extend backward from the tumor along the nerve, and the microscope showed pigmented cells between the atrophied nerve-bundles. Resection of the nerve was declined.

The antero-posterior diameter of the globe was 17½ mm., the horizontal 19½ mm. Horizontal diameter of cornea 9¾ mm. Cornea and sclera were much thickened; the inner and posterior ⅔ of the cavity they enclosed was occupied by a dark-brown tumor, with large, irregular, lighter patch in its central portion; the detached and shrunken retina lay against the outer surface of the tumor. The cells of the growth were partly spindle, partly round, and contained a large amount of pigment. The lighter central portion had undergone degeneration, and consisted in large part of granular matter with free pigment granules.

II. Mr. H., æt. 32, carpenter, consulted me July 31st, 1873, on account of an affection of his right eye. Formerly the sight of this eye was good, but some five years before he had observed a mist coming before it, and had since been obliged to use the left eye in sighting along a straight line, etc., at his trade. Only within three months had he noticed, on accidentally closing the left eye, that there was no sensation of light in the right. Meanwhile there was never any pain or redness. Toward the end of May, 1873, after a day's work, he had an attack of pain in both sides of the forehead, the pain after two or three hours becoming localized in the right eye. He had since never been free from pain, at first mostly in the eye, but now for several weeks chiefly in the right side of the head. From the date of attack he had been unable to work, and had lost much flesh; for a time was about the house, then four weeks confined to a dark room; the last three weeks the pain had been less. Latterly he had used atropine locally.

Now, considerable congestion of conjunctival and episcleral vessels; upward and outward, 1‴ or 2‴ from the cornea, an oval ectasis of sclera, 4–5‴ in its long diameter; cornea slightly hazy; anterior chamber good depth; aqueous a little tinged with blood; iris discolored; pupil dilated, as when sphincter paralyzed, immovable; T. not increased. Only a dull, dark-

red reflex to be seen behind the lens. The other eye normal.

He was advised that the intraocular hemorrhage which had evidently occurred might be due either to tumor of the choroid or to some form of chronic choroiditis. The gradual loss of sight, commencing at the age of 27, in a previously healthy eye, progressing to total blindness without pain or congestion at any time, while the other eye remained perfectly normal, and, finally, the sudden large hemorrhage into the vitreous, rendered the supposition of tumor the more probable. In either case enucleation was indicated.

The eye was removed on the next day. The globe was divided in the horizontal meridian. The lens transparent and in place. The vitreous chamber contained a large amount of blood. Retina everywhere separated from choroid (perhaps in part due to opening of globe before hardening). To the outer side, a darkly pigmented tumor of the choroid lined the sclera in the form of a thin shell, reaching from the outer edge of the disc to the ora serrata. Its inner surface was smooth, except near the disc, where a small button, with roughened surface and somewhat pediculated base, projected forward. The portion of retina which passed over the surface of the button was strongly pigmented. After hardening, the horizontal diameter of the globe was 23¾ mm.; the ant.-post. diameter 25 mm. The tumor at its thickest part (exclusive of button), 3 mm. to outer side of disc, measured 2⅓ mm.; at the equator 1 mm.; at the ora serrata perhaps ½ mm. From behind forward the tumor extended from outer edge of disc to ora serrata. From above downward, measuring along the equator, from near the vertical meridian to some 7 mm. below the horizontal meridian, about 24 mm. The portion reaching the ora serrata was some 5½ to 6 mm. broad.

(In the cuts the lens and greater portion of the retina have been removed to show tumor better.)

The button was situated a little above the horizontal meridian; its inner edge nearly reached the edge of the disc; it measured 6¾ mm. in

longitudinal, $3\frac{1}{8}$ mm. in transverse diameter, and projected $3\frac{3}{8}$ mm. in front of the thickest portion of the main tumor.

Histologically the tumor was a strongly pigmented spindle-cell sarcoma, with considerable fibrous tissue, and not very vascular.

The second case is specially interesting from the very unusual form which the tumor assumed: very great lateral development with slight tendency to increase in thickness. Clinically it is also of interest on account of the difficulty in diagnosis it would probably have offered in its earlier stages. The button undoubtedly was of comparatively recent date. It would scarcely have been an easy task to decide the presence of a tumor from the low, even, extensive elevation of the fundus which such a growth must for a considerable time have presented, and its vascularity was so little that not much aid could have been expected from the appearance of vessels on its surface.

BRIEF REPORT OF A CASE OF PIGMENTED SARCOMA. By Wm. Thomson, M.D., Philadelphia.

In the discussion of other cases of this character, this one was reported verbally, and at the request of the society the following brief clinical history is submitted, which, although incomplete in its details, may be of interest in connection with the full reports presented by some of my colleagues.

History.—May 6th, 1872. S. L. twenty years ago was injured by piece of steel, which caused inflammation of left eye lasting several weeks, but which subsided without causing any impairment of vision. Five years ago, after extraction of a tooth, there followed severe pain in the left eye, with inflammation and a protrusion of the ball, and entire loss of sight.

Present condition.—The left eyeball is displaced downwards and outwards, and has but little motion, and protrudes so that on lifting the upper lid the ball is exposed behind its equator. The cornea is transparent, the pupil widely dilated, and the lens entirely opaque. The conjunctival vessels are distended with blood. The ball is tender on pressure, its tension is much increased, and there is no light perception. The patient seeks relief from the attacks of severe pain and inflammation which recur every few weeks, and disable him from any work.

May 8th: Eyeball enucleated; in dividing the optic nerve I was obliged to cut through a pigmented mass half an inch in diameter; found the orbit occupied by a morbid growth, which was carefully enucleated by the fingers and the handle of a scalpel, and thus removed in its capsule; it consisted of a spherical lobulated mass, larger than a normal eyeball, which was densely pigmented. The optic nerve was not involved in the mass, and it was hoped that the entire morbid growth had been

removed. No accident occurred, and the man was discharged on May 24th.

January 8th, 1873: The pain has returned; the lids are swollen. The contents of the orbit are hard on pressure, and in the cicatrix in the conjunctiva are to be seen two small black nodules.

February 19th: Has had pain down the nose and in the orbit and temple so severe every day as to prevent his doing any work.

February 28th: The pigmented nodules are doubled in size, and no doubt can exist that the orbit contains a hard mass.

With the right eye V.=½ Accommodation normal; no lesions in fundus; the disc is not choked; there is no cachexia, as evidence of involvement of any organ, nor any giddiness, nausea, paralysis, or other sign of brain lesion.

March 7th: Divided external canthus, and with the greatest care removed the entire contents of the orbit, at the apex of which a small, hard nodule was felt, which it was feared extended beyond the foramen. The pigmented mass removed was equal in size to twice that of an eyeball, and after its removal the walls of the orbit were freely washed with a solution of ʒ i ad ℥ i of zinci. chlorid. Wound was dressed with sol ac. carbolic, and the man quickly recovered from the operation, and was sent home March 29th with no sign of any return of the disease.

August 6th: Is looking well. Tinnitus in both ears, but hearing not impaired; slight pain in left orbit and in the head; abduction of Rt. slightly impaired; V. and A. normal.

October 28th: Paralysis motor externus of right but no change in the fundus. No choked disc; V. = $\frac{1}{1}$; pupil responsive. The pain in the left side of head has been so severe at night as to demand narcotics. He becomes giddy on stooping down, so that he is unable to resume his work. The sensation over the brow, annulled by the second operation, has returned, but there is no appearance of a morbid growth in the orbit.

To Dr. Bowen, of Bridgeton, N. J., I am indebted for the final observations, and for the opportunity of inspecting the brain, sent to me after the autopsy. The pain in the head continued, and five weeks before death there were very severe pains in both arms and legs; he gradually lost the sight of his right eye, became deaf, had severe convulsions, and was a com-

plete imbecile for two weeks before death, on May 15, 1874, just two years after first operation. No tumor existed in the orbit, nor were the internal organs affected, except the brain, which was forwarded to me. On its left side, beneath the dura mater, but attached to it, there is an oval pigmented tumor 2½ inches in length by 1¼ inches in thickness, immediately in front of the pons. and quite near to the origin of the fifth nerve, the trunk of which is lost in the growth. The optic nerves at the commissure are normal, so that the disease must have extended by the periosteum and not by the optic nerve. The condition of the right-optic disc has not yet been determined, and will be more fully reported hereafter. The growths all presented the microscopic appearances of pigmented sarcomata.

CASE OF MELANOSIS OF APPARENT TRAUMATIC LOCAL ORIGIN. By Arthur Mathewson, M.D., Brooklyn.

By the courtesy of my friend, Dr. Geo. K. Smith, of Brooklyn, I am permitted to present the following brief notes of a case lately seen in consultation with him, which may prove of interest in connection with the other cases of kindred nature presented.

William Rogers, æt. 22, sewing-machine carrier, five years ago received a blow from a hoop on the temporal side of the right eye, from the effects of which he soon recovered, having suffered but little inconvenience. The precise nature of the wound I am unable to state. About a year after, he first noticed, at the seat of the injury, a small, dark-colored tumor, which gradually increased, and is now about the size and shape of the small field-bean split in two. This extends along the horizontal meridan of the eye, over the ciliary region and backward, and seems to be embedded in the sclera at that point. It has never caused pain. The vision is good, and the ophthalmoscope reveals nothing abnormal in the interior of the eye. About a year and a half ago, he noticed a small tumor on the right cheek near the angle of the jaw. This was followed by numerous other tumors of varying size, from that of a large pea to that of a very large horse-chestnut, and appearing over an extensive surface—abdomen, thorax, back, limbs, and face—some of a deep bluish-black, the skin over them having undergone melanotic degeneration, others still covered with normal skin, which is movable over them. They seem to have their beginning in the subcutaneous tissue, and at first have no deep attachment. Some are now exfoliating from their external surface, but there is no proper ulceration.

The most prominent tumor unconcealed by the clothing was on the right temple, and was removed for cosmetic effect by Dr. Smith. Dr. Eno, who examined it, writes thus of the microscopic appearances:—"A small melanotic mass surrounded by connective tissue, and divided up by bands of the same.

"The pigment of the melanotic mass is for the most part disposed in the form of granules, large and small, infiltrating all the tissues of the mass, and not arranged in cells. In some places, however, there are irregular pigmental masses, perhaps cells; also there are collections of large oval nuclei surrounded by delicate cell-substances of finely granular pigment-matter. These are to be found in the portions of the tumor where the pigment is least abundant. In the darker portions it is hardly possible to distinguish any structure, only an indefinite mass of pigment. The specimen presents the characteristics of melanosis, and is similar to specimens taken from the subcutaneous cellular tissue of the case previously examined by me."

There is no evidence as yet of the involvement of any internal organ, except that dark pigment-granules have been found in the urine on repeated microscopic examinations. His general health is good, and he is robust and able to follow a laborious occupation, which is the delivery of sewing machines, involving a good deal of heavy lifting.

The points of special interest in this case, to me, are the apparently local and traumatic origin at a region in which pigment normally exists (uveal tract), of a series of melanotic tumors scattered over the whole surface of the body; and also the question of the nature of these tumors, whether simply masses of pigment (simple melanosis, if there be such a thing), and only dangerous as likely to occupy vital organs and destroy life by interference with their functions, or having elements of malignacy, of a sarcomatous or carcinomatous character. The man's good general condition shows that a marked melanotic diathesis with extensive deposit of pigment-matter in the tissues is not inconsistent with life and health for a considerable period of time.

TWO CASES OF INTERESTING SYPHILITIC LESION OF THE EYE. By Charles S. Bull, M.D., New York.

The first case was an external growth involving the subconjunctival or episcleral fascia and sclera, accompanied by an intraocular growth. The patient was a woman 36 years of age, married, and the mother of six children, three of whom are living. She volunteered the statement that she had contracted syphilis from her husband, and she probably had the primary lesion about ten years ago, as shortly after that period there appeared an eruption of the skin over the whole body, though most marked on the face and chest. She was treated with mercury, and the spots gradually grew better, but have left a very distinct discoloration of the skin behind them. During the next two years she suffered from ulcers of the fauces and pharynx, alopecia and periosteal rheumatism, but her eyes remained perfectly well until seven years ago, when the left eye became very red and painful, and vision was so reduced that she had barely perception of light. She was treated in the New York Infirmary for a number of weeks, for what was probably an irido-choroiditis, and her vision improved somewhat, so that she could distinguish large objects, her right eye remaining perfectly well through the whole course of the disease. In the latter part of March of this year, the left eye again commenced to be very painful, the eyeball became very much congested, and vision again sank to perception of light. When she presented herself at the infirmary for treatment, an examination showed a general ciliary injection, a clear cornea, a discolored iris with movable pupil, and great tenderness on the slightest pressure upon the globe. The ciliary and conjunctival redness was most marked over that portion of the ciliary region lying between

the insertions of the superior and external recti muscles, and here there was a swelling or outgrowth, of about 2‴ in height, rounded at the periphery, and extending back about half an inch in a straight course. The overlying conjunctival vessels were immensely engorged and tortuous, and there was some chemosis of the conjunctiva immediately surrounding the growth. After dilating the pupil, the vitreous was seen to be so opaque with inflammatory products, that the fundus could not be seen. Some of these membranes were floating free in the vitreous, and were of all shapes and sizes. In the upper and outer part there was seen a dark-brown mass, about the size of a pea, which was stationary, and occupied a position corresponding exactly to that of the scleral growth outside. This intraocular neoplasm probably dates back to the preceding inflammation seven years ago, and is probably a gummy tumor of the sclera, and perhaps of the choroid. From the position of the extra-scleral growth being just over it, it seems not improbable that the two are directly connected through the sclera. It is rather strange that the iris should not be affected by a similar growth, inasmuch as gummata of the iris are so common in syphilitic lesions of the eye. Vision in this eye was reduced to movements of the hands, but in the right it was normal, and this eye was perfectly healthy.

The second was a case of choroiditis disseminata, with unusual ophthalmoscopic appearances. The patient was a man, married and 45 years of age, who had contracted the initial lesion of syphilis thirteen years ago. The primary ulcer was followed by a cutaneous eruption, ulcerated fauces, alopecia, and most obstinate and painful periostitis of the frontal bone, clavicles, and tibiæ. About one year after the inception of the disease, the right eye became violently inflamed and very painful, and vision was nearly entirely lost. He was treated for six months before the inflammation entirely subsided. He has had several recurrences of inflammation in this eye, and though he had regained his vision almost entirely after the first attack, yet under the repeated onsets it has steadily diminished.

In the summer of 1871 he suffered from a stroke of cerebral hemorrhage, was unconscious for seven days, and was *paraplegic*, his *arms* remaining entirely unaffected. About six months ago the vision of the left eye began to fail, and has

steadily grown worse. An examination showed in the right eye, V.=$\frac{20}{200}$; in the left eye, V.=$\frac{20}{70}$, with no improvement by any glasses. The pupils were moderately dilated but extremely sluggish, and the irides were normal in color and appearance. The ophthalmoscope showed marked choroiditis disseminata in both eyes, the signs of atrophic degeneration being most advanced in the right eye. Both nerve-disks were the seat of progressive atrophy, with a central atrophic excavation, which in the right eye reached down to the lamina cribrosa. The arteries were very much diminished in calibre, and the results of a retinal perivasculitis were well marked. All over the retina, though most marked in the region of the equator, were scattered irregular, shapeless masses of pigment, as is usual in this form of choroiditis. But in the neighborhood of the posterior pole of the eye, in the region of the macula and optic disk, the pigmentary deposit was very abundant and arranged in a very peculiar manner. The spots of pigment were nearly all of the same size and shape, hexagonal in form, and arranged exactly as the hexagonal pigment cells of the external surface of the retina, and to the ophthalmoscope presented the same appearance as the microscopic drawings of these cells which we see in the anatomical descriptions of the minute structure of the eye. The appearance was about the same in both eyes, and was very peculiar. Most of the masses were posterior to the retinal vessels, but some of them were in the most anterior layers of the retina, and covered the vessels. It is the only case I have seen where there was such an arrangement of the pigmentary deposits in the retina and choroid.

SYMPATHETIC OPHTHALMIA, PERSISTING AFTER ENUCLEATION. REMOVAL OF EXTREMITY OF OPTIC NERVE AND SURROUNDING TISSUES. RECOVERY. By Hasket Derby, M.D., Boston.

C. E. B., a bricklayer, aged, 24, came to me October 28th, 1873. Three months before, while at work in the brick-yard, he had got some clay in his left eye; this accident had been followed by gradual diminution of vision, unattended by pain, and not at all interrupting his work.

On examining the left eye, I found the pupil small and adherent around its entire edge, iris discolored and bulging forward so as to be almost in contact with cornea throughout its entire extent. No ciliary tenderness. Vision $\frac{5}{100}$; projection perfect. Other eye normal.

The next day iridectomy was performed on the left eye. The wound, made upwards with a Liebreich's knife, healed readily.

November 3d: Some blood in pupil; iris on normal plane; vision as before.

1874, January 19th: Patient returned, complaining of some pain in right eye. Very slight ciliary redness was found to exist. Left as before.

29th: Rt. ciliary redness increased; pupil free; some punctated deposit on centre of cornea. Vision $\frac{20}{20}$. Left, some increase of ciliary redness with slight tenderness over site of wound.

A weak solution of atropine was ordered in right eye; and patient carefully watched.

February 10th: Renewed ciliary redness of right eye, some pain. Vision nearly, but not quite, $\frac{20}{20}$. Increase of deposit on back of cornea. Left, ciliary redness increased; more ten-

derness over wound. Vision $\frac{5}{100}$, as before. New pupil filled with membrane.

Sympathetic ophthalmia being clearly imminent, enucleation of the left eye was proposed and performed on the afternoon of the same day (February 10th), the specimen being handed to Dr. Wadsworth for examination.

"The eye, hardened in Müller's fluid and alcohol, was divided by horizontal section. Vitreous and aqueous chambers were filled with a firm whitish coagulum, showing albuminous infiltration. The retina was slightly separated from the choroid over large extent, apparently from the contraction of the vitreous during hardening. Iris attached to lens capsule. Ciliary body to naked eye more grayish than normal, and somewhat thickened.

"Microscopic examination showed the ciliary body was densely infiltrated with pus cells; its anterior processes were drawn forward and attached to the posterior surface of the peripheral portion of the iris. The iris was infiltrated with small cells, but in less degree than ciliary body; its posterior surface was attached to the anterior capsule of the lens over a very large extent. The pupil was closed by a fibrous layer containing some cells and a large amount of uveal pigment. The interspaces of the fibres of the zonula contained numerous small cells; more numerous near the ciliary processes and iris, but extending in less numbers to the lens capsule. The anterior fourth of the vitreous contained many pale cells of greatly varying size and shape. The greater portion were of the size and form of pus-corpuscles; other round cells were larger, up to thrice the diameter of pus-corpuscles, some containing two or more nuclei; others were spindle, or stellate, with long thread-like processes. Many were situated at the side of large vacuoli. In many places the cells by juxtaposition or anastomosis of their processes formed delicate membranes, which could be traced for long distances. The boundary between this portion of the vitreous and the homogeneous, nearly structureless, posterior portion was pretty sharply defined, and curved backward from the retinal surface a little behind the pars ciliaris retinæ.

"The contents of the anterior chamber were mostly homogeneous; but the anterior surface of the iris, ligamentum pectina-

tum, and a small portion of the periphery of the posterior corneal surface were lined with a thin layer of small cells. Similar cells lay here and there in small groups on other parts of the posterior surface of the cornea, but much the greater part of this surface was free, and the endothelium lining the membrane of Descemet appeared unchanged. Cornea and sclera were normal, only about some of the perforating vessels at the sclero-corneal junction there was some cell infiltration.

"The papilla was slightly thickened, as was the retina in its immediate neighborhood. Here the elements of the outer and inner granular layers were separated by œdema so as to form a series of irregular arcades, and the internal limiting membrane was thrown into folds. In the rather shallow depression near centre of papilla was a mesh-work of fine fibres enclosing some cells, and on the surface of the retina near by were also a few small cells here and there, but neither in the papilla nor this part of the retina was any cell increase evident.

"Near the ciliary attachment the retina showed some cell-infiltration and the walls of a few of its vessels in this region were crowded with cells. Elsewhere it showed little change. There was, however, almost everywhere between it and the epithelial layer a thin layer of coagulum, generally homogeneous or containing only granules of epithelial pigment, but near the ciliary body containing pus-corpuscles also.

"The choroid showed everywhere some increase of small cells, very much greater in the neighborhood of the ciliary body."

February 12th: Ciliary redness had entirely disappeared from right eye. Vision nearly $\frac{20}{20}$, the punctated deposit on back of cornea accounting for the slight falling off in this respect.

I did not see Mr. B. again until April 22d. Within a few days muscæ had appeared before the right eye, and vision begun to fall off. No pain had been felt on the other side, and an artificial eye had been worn with entire comfort. I found the ciliary redness had returned and was more marked than before; cornea a little hazy; iris discolored and adherent in several places to anterior capsule. Vision rather more than $\frac{20}{30}$. Patient was sent at once to the hospital and placed in a darkened room, atropine being freely applied. The next day the pupil was dilated ad maximum, several spots of pigment on anterior

capsule marking the previous adhesions. Redness less; fewer muscæ.

This improvement proved, however, of short duration. Two days later the iris became again discolored, the pupil contracted, and the ciliary redness increased. Two leeches were applied to the temple, and mercurials given internally. But nocturnal pain now came on, and soon became very distressing.

April 30th: The pain at night had somewhat diminished; ciliary redness daily growing more marked and forming a well-defined zone about cornea. Decided ciliary tenderness; vision daily diminishing.

May 2d: All the symptoms aggravated; increased redness and ciliary tenderness. Nocturnal pain, agonizing, extending back to ear and effectually preventing sleep. Anterior chamber deepening.

With all these symptoms of irido-cyclitis there was nothing to be found in the orbital cavity of the other side to account for the attack, either in the shape of discharge or tenderness on pressure. The artificial eye, which had never caused uneasiness, had not been worn since the commencement of the attack. The patient was now profoundly depressed, his general health beginning to give way, and the prognosis seemed gloomy in the extreme.

As a last resort, by the advice of Dr. Hay, of Boston, and my brother, Dr. R. H. Derby, of New York, and assisted by the latter, I, May 4th, carefully dissected up the conjunctival cicatrix in the left orbital cavity and removed some 3‴ of the extremity of the optic nerve and surrounding tissues. This fragment was unfortunately mislaid after the operation, so that no microscopical examination could be held.

During that night the patient was entirely free from the usual attack of pain. Within twenty-four hours the eye began slowly to improve.

May 8th: The redness was diminished, the pupil more fully dilated, and the vision clearer. There had been but a short attack of pain in the night, severe while it lasted.

May 10th: Complains of exquisite tenderness of eyeball, on awakening in the morning.

17th: Very little redness remaining, atropine omitted.

He continued to improve up to the 29th, when he left the hospital. Tension was then slightly increased, anterior chamber deepened, pupil somewhat dilated and sluggish, vitreous hazy, nerve dimly visible. Vision $\frac{20}{70}$; ciliary redness hardly perceptible.

June 11th: Pupil smaller and less sluggish; anterior chamber narrower; V. $\frac{20}{30}$.

Whether the removal of the extremity of the optic nerve, or the probable accompanying excision of a portion of the ciliary nerves, or the freeing of the latter from entanglement in the cicatrix by the necessary dissection, brought about relief in this case, we can only conjecture. The practical point raised, and one, it seems to me, of vast importance, is the following: Would it not be well, in all cases of sympathetic ophthalmia persisting after enucleation, to perform an operation similiar to the foregoing?

NOTE.—Unfortunately this improvement was not to last. During my absence from the city, in the summer, the patient had two attacks of inflammation, less severe than the preceding, but of the same general character. One occurred early in July, the other towards the middle of September, each lasting about a fortnight.

October 20th: Pupil slightly dilated; anterior chamber deepened; fresh deposit of pigment on anterior capsule; vitreous very hazy, allowing no clear view of fundus. V. $\frac{20}{200}$. No tenderness in ciliary region.

A FOREIGN BODY IN THE GLOBE ONLY PRODUCING SYMPATHETIC TROUBLE AFTER THIRTEEN YEARS. Dr. B. Joy Jeffries, Boston.

A man aged 42, some thirteen years ago, was cutting some kind of a spring in a rifle factory, when a piece flew and struck the right eye on the cornea, out and below, cutting through it. The patient was laid up two or three weeks. His sight held good for two or three years, then it gradually failed without any pain, and in some five months was quite gone. Since then he has had no pain till eight weeks ago, from May 6, '74, when ciliary redness was noticed and pain commenced. This has not been severe enough to prevent sleep, but "troubled the other eye." Now there is intense ciliary redness in a marked and limited zone, which, however, he says is less than it was the previous week. There is a scar on the cornea down and out, iris evidently disorganized and pressing against the cornea. The globe is hard. No pupil, and iris fastened into the old scar of the cornea. Marked sympathetic in the other eye. Enucleated May 8, '74. On section a detached, funnel-shaped retina was found. In place of the choroid a débris of inflammatory material, bedded in which was a piece of metal ¼ inch long, of the size of the point of a brad. The whole of the ciliary region massed together by recent inflammation. Placed in Muller's fluid. Sympathetic symptoms were all gone in a few days, and the patient expressed himself as perfectly relieved.

The case seemed to me to show that sympathetic trouble might not be started up until the ciliary region of the globe was implicated. The metal had lain years in the choroid, evidently causing its partial change by inflammation without affecting the other eye. When the ciliary region became affected, as shown by external redness, then only did the formerly well eye begin to show trouble, which enucleation at once relieved.

TREPHINING THE CORNEA TO REMOVE A FOREIGN BODY DEEPLY EMBEDDED IN ITS SUBSTANCE. By C. R. Agnew, M.D., New York.

M. C., æt. 30, a fireman in gas-works, consulted me on September 10th, 1873, for kerato-iritis of five months' duration, produced by the deep lodgement of an extremely small foreign body in the cornea.

Scattered over the area of the cornea were numerous cloud-like opacities, some deep and some superficial; there was marked ciliary injection, discolored, mossy-looking iris, with sluggish, irregular pupil, restrained but not fixed by three or four very small adhesions of synechia posterior.

The ciliary neurosis was very annoying, and, combined with some sympathetic irritation in the fellow eye, had for some months kept the subject from work.

Opposite the infero-nasal margin of the pupil in the cornea there was a very minute ulcer surrounded by a circular opacity. This opening led obliquely to a sinus, in the bottom of which, apparently as deep as the membrane of Descemet, was an extremely minute black foreign body. To this unremoved foreign body I attributed the kerato-iritic inflammation, as the subject remembered the fact of his having got a bit of coke or coal in his eye, and of the immediate inflammatory consequences. I attempted to remove the foreign body from the bottom of the sinus, using delicately, for the purpose, various forms of spuds and needles, but without avail. I could easily explore the sinus in the corneal tissue down to the bed of the foreign body on the membrane of Descemet, but without being able to dislodge the foreign body except at the risk of pushing it into the anterior chamber. Drs. Pomeroy and Webster

examined the case by means of oblique illumination and the ophthalmoscope, and agreed with me as to its nature, and that the very minute black speck in the bottom of the sinus was not a pigmentary product in the inflamed cornea. It was evident that enucleation was inevitable unless the foreign body could be removed. It occurred to me, as I could not remove the foreign body alone, that I might remove, by means of the trephine, the disc of corneal tissue which included it, and thus remove the cause of the kerato-iritis and of the sympathetic trouble in the fellow eye. We placed the patient under ether, held the eye under fixation forceps, and without difficulty removed a disc of corneal tissue, the exact centre of which was the opening of the sinus holding the foreign body. Although we applied the trephine perpendicularly to the corneal surface, we did not cut through into the anterior chamber so as to complete the circle at once, but so as to leave a small segment of the deep surface of the disc to be cut by the scissors. Removing the disc and examining the sinus in its centre, no foreign body could be found, as the black speck had disappeared. This speck had not dropped through the sinus into the anterior chamber, as there was no opening in that direction; it could not be found floating on the surface of the eyeball, or in the inferior conjunctival cul-de-sac, and it is not probable that it got into the anterior chamber through the wound made by the trephine, as the kerato-iritis soon subsided and the eye regained a healthy state, and all sympathetic trouble in the fellow eye disappeared. The question remains, what became of the extremely minute black speck which was seen in the cornea before the operation, and could not be found in the disc of corneal tissue removed. In using the corneal trephine it is observed that the disc of tissue which it cuts out is more or less crumpled by the rotatory motion, and reasoning upon this fact, we were led to believe that the foreign body was worked out from the depth of the sinus, and washed away unseen by the free escape of aqueous humor and tears. No prolapse of iris followed the trephining, and under simple dressing, with a light bandage, the eye soon recovered without synechia anterior.

The symptoms of kerato-iritis rapidly vanished, the cornea became much clearer except where the scar was left by the trephine.

This scar, when mature, was only about half the diameter of the calibre of the instrument. I did not feel justified, in this case, in attempting to remove the foreign body by any of the methods previously recorded, and the history of the case, followed for many months subsequent to the operation, seems to ensure a beneficent result. Although the existence of slight synechia posterior guarded this subject against the occurrence of prolapse of the iris through the wound made by the trephine, we would not hesitate to resort to the use of the trephine for the removal of a deeply embedded and immovable corneal foreign body, even though a synechia anterior might result, the danger resulting from a synechia anterior being less than that from a foreign body remaining permanently embedded in the cornea.

A NEW METHOD OF TREATING BLEPHAROSPASM.

By Arthur Mathewson, M.D., Brooklyn.

The following case is presented as illustrative of a simple method of treating what sometimes is found to be a very obstinate and troublesome affection, with the hope that it may be given a further trial, and may prove as effective as in this instance.

Miss V. B., æt. 21, has had epileptic attacks since childhood, in one of which, five months before she first consulted me, March 5th, 1874, she fell, bruising the right temple and supra-orbital region. Blepharospasm, affecting the corresponding side, came on, apparently as a result of this injury, the eye being tightly closed, and the patient unable to open it. McKenzie, in his work on diseases of the eye (London, 1854, page 181), refers to such injuries as a cause of one-sided blepharospasm—the twitching of the lids and the resistance to raising the upper with the finger distinguishing such cases from those of paralysis of the levator palpebræ, which is sometimes the result of like injuries. The eye was otherwise unaffected, and the vision was good.

On May 2d, a variety of other means having been tried without effect, and the patient and her friends being very anxious that something further should be tried, I bethought me of a plan I had seen employed by Dr. Van Bibber, of New York, in a case of ptosis exhibited at a meeting of the New York Society of Neurology and Electrology; which was, to raise the upper lid by means of a slender band of india-rubber fastened near the lower edge of the upper lid below and the forehead above with stripes of isinglass plaster and collodion. As I recollect this method had been employed by Dr. Van Bibber only in a

case of ptosis, and was not suggested as a means of relieving blepharospasm, but it occurred to me, as I raised the lid with my finger, that if it could be kept elevated for a time, the spasm of the orbicularis might be overcome, and that a slender rubber band fastened in the way indicated—which by its elasticity would yield enough to render it not unendurable, and at the same time exert a constant force in opposition to the action of the muscles—would be just the thing for that purpose. Accordingly a band of rubber, about a line in breadth, half a line in thickness, and an inch in length, was attached by one end to the surface of the upper lid, near its lower edge, at the middle of its horizontal length, a strip of isinglass plaster, notched so as to adapt itself accurately, being applied across the band, and the whole covered with collodion and allowed to dry till firmly adherent. Then the band was stretched upward to an inch and a half, so as to elevate the lid moderately, and fastened to the forehead in the same way. The band kept in place, and was borne without inconvenience for twelve days, till, during the struggles of an epileptic attack, it was loosened. The blepharospasm was then found to be entirely overcome, and has not returned.

The prompt and complete relief afforded by this simple device in a case that had so long resisted other means of treatment, seems to me to commend it to a general trial.

The size, length, and tension of the band may of course be varied to suit circumstances, and in some cases it may be found better to employ more than one band, and to act upon the lower as well as the upper lid.

Though I have as yet had no opportunity of trying these elastic bands in cases where the contrary condition exists, and instead of blepharospasm or ptosis there is paralysis of the orbicularis or spasm of the levator palpebræ superioris, I believe they will do good service in such cases, being applied so as to draw the eyelids together, and thus assisting feebly acting muscles, and antagonizing those whose action is too strong.

A CASE OF DOUBLE, EXTREMELY MINUTE, AND APPARENTLY CONGENITAL LACHRYMAL FISTULA. By C. R. Agnew, M.D., New York.

The case was that of a girl three years of age, in excellent health and of healthy parentage.

A year previously to the date of my examination, December 5th, 1873, a minute drop of clear fluid was observed exuding from the region of the left lachrymal sac at a point immediately below the tendon of Horner's muscle. Six months afterwards a similar drop of fluid was observed over the right sac. In neither case was there, or had there been, the faintest trace of inflammatory action about the eyes, or any tendency to blepharitis or catarrh. I first saw the child on December 5th, 1873, and observed its good health and entire freedom from any trace of eye disease or want of full facial development. The parts about the internal canthi were well formed, and might have been taken as models of anatomical perfection. Immediately beneath the horizontal elevation made by the tendon of Horner's muscle, and over the centre of the corresponding portion of the lachrymal sac of each eye, might be seen, on careful scrutiny, an extremely minute capillary opening, from which the merest drop of pellucid fluid would exude on pressure, or spontaneously. The margins of the fistulæ were not raised in the least above or depressed below the surface of the surrounding skin, nor were they in the slightest degree inflamed or otherwise changed in color. The little fistulæ were so extremely minute that they were scarcely to be distinguished, except when a little dew-like moisture exuded. The puncta seemed to be well formed and patulous. The parents stated

that sometimes after crying, the fistulæ would discharge tears in small quantity, but entirely unaccompanied by any local inflammatory action. I did not feel justified in resorting to any form of surgical interference, contenting myself with asking to see the case, should any change occur.

THREE NEW INSTRUMENTS:—SPECULUM, OPHTHALMOSTAT, AND TENOTOME. By Russell Murdoch, M.D., Baltimore.

Fig. No. 1 represents the speculum in position. It consists of two blades, marked *a* and *b*, the one attached at right angles to the bar *f*, and the other to an inverted saddle. The saddle rides under the bar, and has at one end a pin, around which

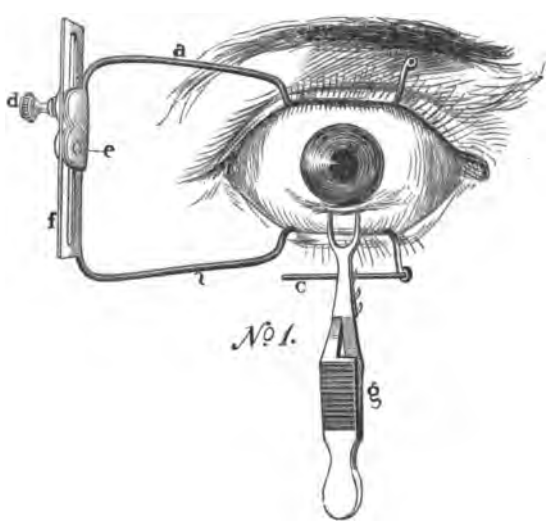

it describes nearly a semicircle, carrying the blade a with it, and at the other end a screw, *d*, to fix it in position on the bar.

In adjusting the instrument, the blades are to be invariably first brought closely together and fixed by the screw, and then their distal ends inserted under the lids; by a reversed quarter-turn of the screw, the blade *a* is sufficiently loosened to

slide on *f*, but not enough to fall out of its natural horizontal position.

In pulling the lids apart, the free end of the bar, *f*, must be steadied by the ball of the most convenient finger or thumb, varying, of course, with the eye to be operated on. When the lids are drawn apart to the desired position—a feat easily accomplished—a quarter-turn of *d* fixes the blades.

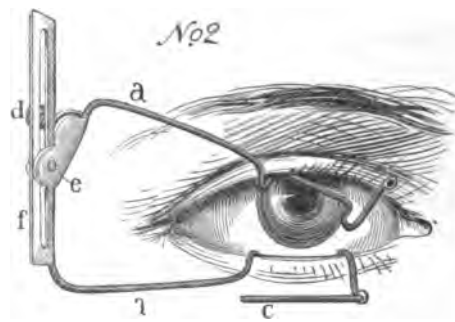

Fig. 2 shows the method by which the lids disengage themselves. The operator has only to make a complete reversed turn of the screw to find the speculum on the cheek of the patient, and that absolutely without pressure on the ball, interference with the wound, or handling of the lids.

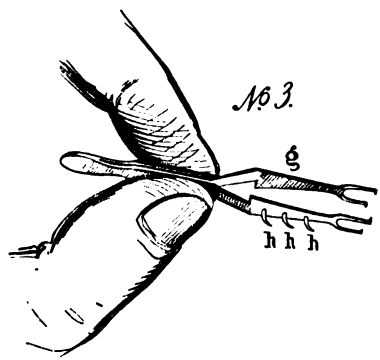

It is hardly necessary to state that the ready disengagement of a speculum is the most important desideratum.

In Figs. 1 and 2, the letter *c* represents a small movable bar, an attachment which can be secured in either blade of the speculum, and is designed to retain in position an ophthalmostat.

This instrument is shown first, in position, in Fig. 1, and then side-view, unapplied, in Fig. 3. In a word, it is a pair of

crossed-branched, forked, rat-toothed, self-holding, and self-retaining spring forceps, and, as its name implies, is an automatic eye-holder. The application is so very simple, and so well represented in the drawing, as to require no further description.

The third instrument is a crochet-pointed hook tenotome Is designed to be used in any operation where the muscles are first to be found and held, and then cut, as in strabotomy.

The angle at which the blade joins the shank is 120°, an angle, in my experience, most convenient for the combined function of hook and knife. The crochet-point has been employed by a fellow-townsman, Dr. Theobald, on the ordinary strabismus hook, and designed by him to prevent the muscle from slipping off the hook in the Moofield's operation. I have added it to the present instrument in order to hunt up stray fibres, and thereby dispense with the second hook, as well as with the scissors.

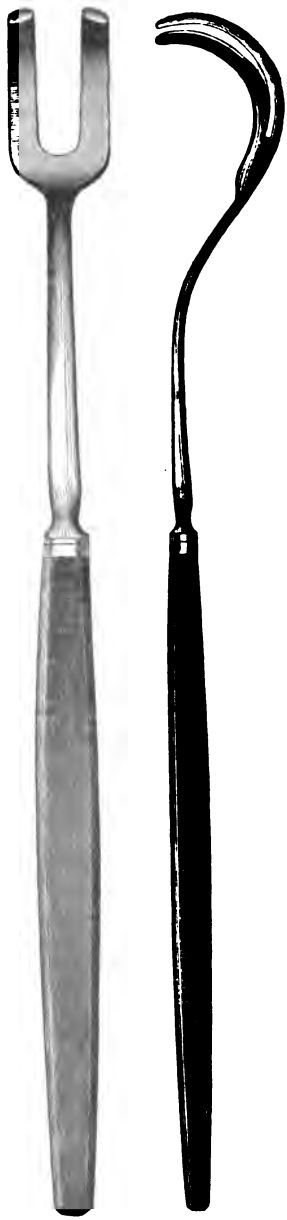

INSTRUMENT FOR FACILITATING SECTION OF THE OPTIC NERVE. By G. Hay, M.D.

Having sometimes in enucleation found it difficult to draw forward the eyeball sufficiently so as to be able to sever the optic nerve at some distance from the ball, it occurred to me that the latter might be lifted with the aid of an instrument passed behind it, and for this purpose I had made a kind of two-branched blunt hook.

The branches are smooth, thin plates, so shaped as to fit the posterior surface of the eyeball. They are somewhat parallel with each other, long enough to pass about threequarters the way around the posterior half of the eyeball, and separated by an interval of a quarter of an inch, to allow the optic nerve to pass between them. They are one and a half lines broad, and at the ends flat, rounded, blunt, thin, and smooth.

From the junction of the two plates proceeds the stem, which, at the height of about three-quarters of an inch, is bent outwards, away from the concavity of the branches.

As I have used the instrument, it was introduced from the nasal aspect of the eyeball, the two curved plates sliding easily along by the optic nerve, one on each side of it. The nerve was cut from the temporal side.

TWO NEW INSTRUMENTS.

1. A RETRACTOR FOR THE UPPER LID. (WITH WOOD CUT.) By Dr. Henry D. Noyes, New York.

When we have to deal with an eye which is deeply sunken in the orbital cavity, it is extremely difficult to separate the lids so as to get a satisfactory exposure of the cornea. We frequently meet this condition in old and emaciated persons.

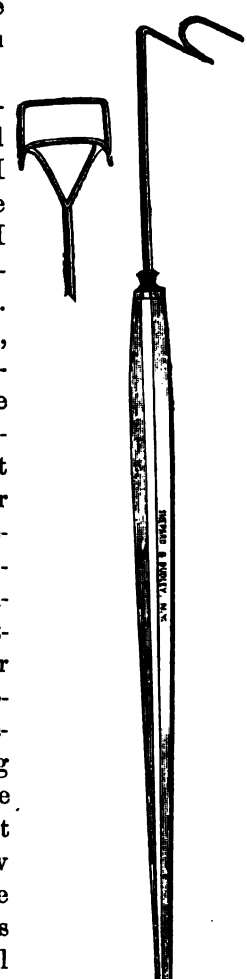

Furthermore, if for any reason it is imperative not to make pressure on the eyeball when we wish to expose it fully to view, I have found it hazardous to use either the usual elevator or any form of speculum. I have commonly resorted to a strabismus-hook, with which to lift the upper lid only.

This device is, however, not satisfactory, and for a deeply set globe the usual elevator fails to give complete exposure of the eye, and no speculum can meet the difficulty, because all such instruments must rest upon and be arrested by the anterior margin of the orbit. The contrivance described and figured below has been invented to obviate the objections above alluded to. It has been devised after reflecting upon the manner in which the upper lid is lifted, viz., by being, as it were, rotated over the spherical surface of the eyeball. In other words, because in being elevated the upper lid retreats under the roof of the orbit, an effectual instrument to perform this movement must follow the lid into the cavity of the orbit. The method by which this new retractor acts is at once apparent. It catches the tarsal margin as a pen is laid in a rack, and

carries the whole lid under the orbital roof as far as may be desired. The operator's hand does not lift up the lid against the roof of the orbit, but pushes it backwards over the top of the eyeball, between it and the superior surface of the orbit. There is always room enough here to allow the instrument to be then, as it were, buried in the cavity, and no pressure need be made on the globe. The lightness of the instrument is an incidental recommendation of it. It is made of stiff wire and needs to be strong only in the shank. Its action in exposing the front of the eyeball to view is so complete that one needs sometimes to have care not to push with it too much. Unlike the common elevator, it does not press against the angle of reflection of the conjunctiva, but exerts its force upon the free tarsal edge, and hence possesses peculiar power.

---

2. A FIXATION FORCEPS WHICH ATTACHES TO THE SPECULUM. (WITH WOOD CUT.)

Under many circumstances it becomes desirable to have, for fixing the eyeball, some instrument which shall not compel the aid of an assistant. Sometimes an assistant of suitable dexterity to be entrusted with this delicate function cannot be obtained. Every operator will often be glad to be enabled to perform all the manipulations about an eye with his own hands exclusively.

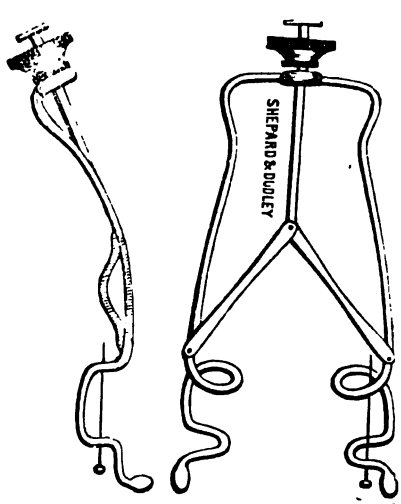

The instrument now presented has been devised to answer the purpose indicated; and I can confidently state that it often proves extremely useful. It is a small forceps with crossed blades and a rather stiff spring to keep them shut; it is curved in an S shape, and rides upon the lower blade of a wire specu-

lum. The double curve given to the forceps blades is intended to follow a line which, beginning upon the front surface of the lower lid, travels up to and over its tarsal border, then down its conjunctival surface to the cul-de-sac, turns again to pass upon the globe, and they seize the conjunctiva bubi near to the lower margin of the cornea. Into one of the curves the tarsal edge of the lower lid fits; the other curve receives the edge of the speculum. If about to use the instrument, slip it with closed blades into the inferior cul-de-sac. Let the lower lid fit itself into the proper curve, press the blades apart and seize the conjunctiva; at a point near to or far from the cornea as the position which is to be given to the eye may call for; then insert the speculum in the usual way, and as its blades are separated in spreading the lids asunder, the action of the speculum at the same time draws the eyeball downwards. The function of the forceps is confined to moving the globe downwards, and does not admit of much deviation sideways. There is no means provided for fastening the forceps to the speculum, but two or three notches might, if needful, be made in its blades to keep the forceps from slipping from side to side. It must be admitted that in using these forceps there is some compression of the eye. I have on this account not ventured to apply it to operations where a large wound is to be made in the cornea. But to many cases, as enucleations, small iridectomy, etc., etc., it usefully adapts itself. One merit it possesses is that the act of closing the speculum instantly relieves the pressure of the forceps, and its small size and weight prevent its doing any mischief. In its action it will be observed that the line of traction is in a tangent to the globe, and does not tend to pull off the conjunctiva, or to antagonize the instinctive effort of the eye, when handled, to retreat back into the orbit. An experience of eighteen months enables me to speak favorably of this contrivance.

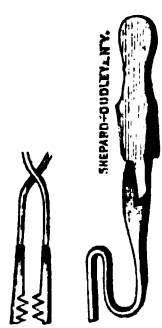

As an addendum to the above remarks, and in the same line of suggestion, I may state, that to keep the cornea turned outwards as in an operation for converging strabismus, without calling upon an assistant for help, one simply needs to separate the

lids with the usual speculum, to attach an ordinary spring-catch fixation forceps to the eyeball in front of the insertion of the rectus externus, and after drawing the eyeball outwards to the point desired, let the forceps fall down over the temporal edge of the orbit. Provided the patient is well under the influence of an anæsthetic, and lying on the back, the eye will maintain the everted position until the finish of the operation—the weight of the forceps will be sufficient to hold it steady.

CASE OF HERPES ZOSTER OPHTHALMICUS. THE WHOLE SIDE OF NOSE INVOLVED WITHOUT AFFECTION OF THE EYE. By O. F. WADSWORTH, M.D., Boston.

A LITTLE girl, 4½ years of age, suffering from an attack of herpes zoster ophthalmicus, was referred to me at the Boston Dispensary, by my friend, Dr. B. F. Greenough, Nov. 14, 1873. The mother stated that she had first noticed complaint of pain, and soon after a "pimple" at the root of the nose, about a week before.

When I saw her there were numerous rather deep ulcerations, some of them covered with thick crusts from beneath which pus oozed. The ulcerations were situated on the right side of the forehead and front part of the hairy scalp, the upper lid, and the whole side of nose to the tip. There was no affection of the nasal mucous membrane. The upper lid was swollen and closed. On raising it with an elevator, the conjunctiva of the globe was found much congested, but without chemosis; the cornea and iris clear and bright.

The mother did not bring the child with any regularity, and I saw her only once again during the course of the disease, about a week later. The condition of the skin was a little better, the lid still swollen, the cornea and iris normal.

The first part of April, 1874, I visited the child at her home. There were large cicatricial pits on the right site of forehead and root of nose, rather smaller and more shallow ones, but still marked, on the upper lid and extending down the side of nose to the end. The eye was perfectly normal in appearance. The mother stated that the whole duration of the disease was about three weeks.

It was impossible to obtain the history of the case with as much accuracy as desirable, on account of the youth of the patient, the ignorance of the mother, and her neglect to bring the child as directed. Still the fact of a well-marked eruption of herpes zoster on the side of the nose without affection of the eye was established.

It has been laid down as a clinical rule, and never to my knowledge contradicted, that when the whole side of the nose is affected in this disease, the eye does not escape. The explanation is found in the fact that the same nerve (naso-ciliary) which supplies the lower part of the skin of the nose and the nasal mucous membrane, supplies also the long root of the ciliary ganglion and long ciliary nerves, and so the cornea and iris.

The case reported forms an evident exception to the rule. The eruption was present to the tip of the nose, yet the eye did escape. The mucous membrane of the nose was also unaffected. The latter circumstance would go to show that the naso-ciliary nerve was not involved, and this granted, the supposition of a variation in nerve-distribution would readily account for the anomaly. This supposition is probably correct, for Professor Turner has reported (*Journal of Anatomy and Physiology*, November, 1871) just such a variation as would be required. The frontal nerve gave origin to a long, slender, infra-trochlear branch, which passed below the pulley of the superior oblique muscle, to be distributed along with the infra-trochlear branch of the naso-ciliary nerve.

SIX CASES OF HERPES ZOSTER OPHTHALMICUS. WITH REMARKS. By Dr. B. Joy Jeffries, Boston.

HERPES ZOSTER, OPHTHALMICUS. CASE I.

A lady aged 55, after exposure to a continued cool wind against the right side of the head, in driving in the evening, felt, August 31, 1873, a pain in the corner of the right eye, "like a needle." She went to bed and finally to sleep. The next day there was more pain, and hot applications were made. By the third day an eruption appeared, and the lids were swollen so as to close the eye; the conjunctiva was inflamed. The disease occupied the right side of the scalp to the occiput, the forehead, brow, lid, and side of the nose to the tip. The crusts began to come off in three or four weeks, and were very extensive. Crusts also came from inside of the nose on that side. By the sixth week the skin was healed up. I saw the patient in the eighth week, October 25, 1873, and found scars on the brow to the outer side, from there to the root of the nose, down the side of it and at the inner angle of the lids. These scars are not pitted, *i.e.*, below the surface, but red and raised like *keloid.* There is some conjunctival trouble, with tears and slight secretion. Some small vesicles on inside of lower lid towards inner canthus, also on the globe above the cornea. There is great intolerance of light. Vision, so far as could be told, about as good as the other eye. Seemingly no *iritis* or *keratitis.* The patient was fairly worn out with the attack of ophthalmic shingles, she had lost flesh, and was weak and depressed. No atropine had been used. This was ordered: grs. ij to ʒ j. *bis die.* Over the skin, to be painted, chloroform one part to five of sweet oil, citrate of iron. and quinine grs. v. *bis*

die. By eight days, November 2, 1874, patient has found great relief from the local application to the skin, and slept quite well. She says it "cools the skin and lets the eye open easier." The atropine did not irritate the conjunctiva. The scars are much less red. The vesicles on the inner sides of the lids are not so troublesome. Vision in each eye without glasses equal $\frac{20}{70}$. I succeeded in making an ophthalmoscopic examination, which was borne quite well. The pupil was well dilated, and there was no iritis. The papilla and whole retina were quite red from injection. A proper test gave me Hm. with V. equal 20—30 with $+ \frac{1}{30}$. Treatment continued.

November 21, 1874: The patient has no "lasting real pain," but occasional darts through the eye. There is still sensitiveness to light, and occasional vesicles on inner side of upper and lower lids. She has gained flesh and appetite. The affected eye has vision equal 20—60 with $+ \frac{1}{30}$. Atropine and pill continued once a day, and cutaneous application *pro re nata.* She complains more especially of excessive itching of the skin.

December 7, 1873: This has continued, and there have been continued crops of vesicles on inside of lids. From the known action of calomel in phlyctenular ophthalmia, this was directed to be dusted on at night, and atropine solution in the morning. Some dots were now seen in the cornea, like interstitial keratitis. Local and internal remedies as before.

December 30, 1873: V. O. D. equal $\frac{20}{50}$, without glass. V. O. S. with $+ \frac{1}{30}$ equal $\frac{20}{20}$. The vesicles on the inside of the lids look flat and firm. Itching over brow and lid severe. Treatment continued.

January 18, 1874: V. O. D. equal $\frac{20}{40}$, without glass. Itching still persists, more especially morning and evening, and now only occasionally darting pain through the eye. Cornea deposits or spots less, with improved vision. The ulcers from the vesicles better, less of a yellowish-color than they have had, and filling up. Continue calomel insufflation, and quinine alone internally, grs. ij. Patient says the side of her head feels "unnatural."

January 29, 1874: Patient said she had last night a piercing sudden pain deep in the eye for a few seconds, startling her considerably. The ulcers on lids are healing. There is a pig-

mented spot on the sclerotic up and in from the cornea. Light is much better borne. Itching something less. Treatment continued.

March 1, 1874: Darting pain less often. Some scattered herpetic-like pustules still on inside of upper and lower lids; they are not so deep. All are not new ones. V. O. D. with $+\frac{1}{42}$ equal $\frac{20}{30}$. Tonic continued. Patient had a touch of sciatica. Bears light better and cold better. Itching "like that of chilblains." Local application continued. The vesicles, or rather their bases, less deep. Some new ones. Calomel powder stopped and tannic acid, ʒ j. to glycerine ℥ j. used instead. I heard by note that this produced considerable pain, and it was stopped and calomel continued. Still some spots in the cornea. Ophthalmoscopic examination shows retina and nerve more natural. The seats of vesicles healing and showing marked yellow color. Simple cerate ordered.

May 6, 1874: Corneal spots much faded. Vesicle seats healed and filled with yellowish cicatricial tissue. Patient still complains of much itching. All the symptoms are better, and patient in much better physical condition. Tonic continued, as also calomel. Patient's husband reported she was much better, the latter part of June, 1874.

HERPES ZOSTER FRONTALIS. CASE II.

A gentleman, aged 32, had undergone excessive and fatiguing work in a new business. Without any apparent, or at least recollected, exposure to cold, there occurred over the region of the frontal nerve, in the scalp of the right side, excessive smarting and pain, followed by groups of "red, fiery pimples which stung like a coal of fire." These he attributed to or connected with a previous injury, to be presently mentioned. There were none on the brow, lids, or side of the nose; the eye also escaped. The subsequent crusts were ten to fourteen days in coming off, and it was some three weeks before he was through with the whole attack. When the patient was a lad, sixteen years previously, he was holding a screw-driver vertically near his face, turning in a screw under a vehicle. The instrument slipped, and the end struck him under the edge of the right upper orbit in the

track of the frontal nerve. It caused considerable pain there, and radiating over that side of the scalp. Since then he has had frequent neuralgic-like pain in the locality, and at times the skin itself positively tender to the touch. He had always mistaken the frontal notch for an injury then done to the bone, and supposed this attack of frontal shingles to be due to it, on account of the occasional neuralgia. Now, three years since this attack, he has quite marked scars over the seat of the ulcers, especially high up on the forehead. They are so noticeable that his friends, during the recent epidemic of variola, insisted that he had been a victim. The patient's mother had a severe attack of shingles, with which disease, from observation of other cases, they were rendered familiar.

HERPES ZOSTER OPHTHALMICUS. CASE III.

A gentleman, æt. 45, Sunday, March 8, 1874, after previous exposure to considerable cold, felt a sharp pain at the inner corner of his right eye, as if something had got into it. By Monday morning there was redness of the lid, increasing that and the next day. The patient, however, was able to keep about. Wednesday the redness extended over the head, occupying pretty thoroughly the track of the frontal nerve. The lids were so swollen as to close the eye. The eyeball escaped. There was no eruption down the side of the nose, but on it, just below the level of the inner carthus. The upper lid had on it what the patient supposed to be a stye. The pain was not very severe at any time, but the whole was very uncomfortable. Besides this, pain was felt over the side of the face up to the meridian line, quite graphically described as a "feeling of that half of the head being all wrong and sick." The irregular pustules left thick crusts at inner corner on the nose, on upper lid near the edge, on the eyebrow and forehead, and smaller ones scattered over the scalp back to the occiput on right side. The gland behind the right ear was swollen and tender, but did not suppurate. Five and a half weeks after the attack, there are more or less well-marked scars on the seat of the above-mentioned crusts. The patient complains of no trouble now. I am inebted to my colleague, Dr. Hay, for permission to gather these notes from the patient himself.

HERPES ZOSTER OPTHALMICUS. CASE IV.

A man aged 63, a night-watchman in a store, about fourteen days previous to March 15, 1874, began to feel a sensation as if "a fly was on his head." By the next day he had pain over his eye, and considerable swelling the next two days. On the third and fourth day the eruption was noticed by his family, and by this time the lids were swollen to his nose. At the end of the fourth day the parts affected were all red and swollen and broken out in sores. The pain was severe enough to prevent sleep. I saw him on the twelfth day. On the quite bald scalp on the right side, limited to the distribution of the frontal nerve, are five scattered crusts, as far back as the nerve goes. On the forehead and brow, quite to the outer side of the frontal nerve, is a group of heavy crusts on a deep-red cutaneous surface. This was still there the fourteenth day, and a blush yet seen over the scalp. The lids continue swollen. There has been no eruption on them, or on the side of the nose, and the eyeball had escaped. There is distinct difference of sensation on the two sides of the head. Cold affects him severely, but itching is only what he especially complains of. Treatment consisted of local application of chloroform and sweet oil, and quinine internally. The patient sent me his photograph, which I had asked for, and, not appearing again himself, I judge treatment was of service to him.

HERPES ZOSTER OF UPPER LID. CASE V.

Monday, September 30, 1872, a girl aged 13 applied to me, saying that her left eye had been bloodshot from the previous Thursday. By Sunday she had seen and felt a group of the vesicles occupying the inner third of the left upper eyelid. They smarted and stung, and were well-marked vesicles with some swelling of the skin. By the next day I found them more or less confluent, forming a thin crust. The disagreeable symptoms were about gone.

HERPES ZOSTER OF LOWER LID. CASE VI.

September 11, 1873, a lad, aged 17, presented himself with a group of herpes zoster just below the right lower lid, an inch

in diameter. The vesicles were large, situated in a reddish base, and the part painful.

Ophthalmic shingles is now so frequently diagnosticated and reported, that perhaps an apology is due in presenting these cases. Each seems to me, however, to have some special point of interest, either in itself, or as illustrating our present knowledge of this very curious affection.

In the first case of the lady who suffered so severely, the scars, as I said, were not pitted, as we usually see, but *raised* and *red*, looking very much like *keloid*. I look, however, to their absorption and sinking below the surface. As seen for some months after the attack, they never would have been taken for scars of shingles. I have never before seen such continued formation of vesicles on the inner side of the lids and in the globe, or such persistent ulceration of the original vesicles which came there with the cutaneous eruption. All the cutaneous ulcers had long healed, and I was puzzled how to treat these annoying *ulcers*, which they fairly were. They would not bear any even weak stimulation, as from zinc or tannin. As calomel in powder acts so well in phlyctenular ophthalmia, I used it freely. It certainly did no harm, and I think was of benefit. This ulceration was deep into the cartilage, as shown by the yellow color I speak of, and the final yellow cicatrices. This may, perhaps, explain the tardy filling up with new growth.

In case 2 the quite certain injury of the frontal nerve may have been an exciting cause. Only the cutaneous tract above the notch and point of injury was affected. Whilst patients can so often fix on, and speak themselves of, some decided exposure to cold previous to an attack, this gentleman knew of none. The frontal nerve in its cutaneous distribution had been in a constant state of irritation, if I may use the word, since the injury, sixteen years before. There were frequent neuralgic pains and absolute tenderness to touch.

In case 3 the amount of pain and suffering was quite inconsiderable compared with the extent and duration of the attack. The peculiar pain and discomfort over the whole of the head and face on the affected side was something unusual. It may have been due to or connected with the swollen and tender gland behind the ear, which, however, did not suppurate.

In case 4 the patient, aged 63, was lucky to escape with so little persistent pain and itching. The crusts and scars in the eyebrows were quite to the outside of the nerve. The photograph shown, rather tends to conceal than render this evident.

In cases 5 and 6 we have instances of very evident attacks of zoster over the cutaneous distribution of but a small twig of the nerve. I think, however, they would have been found associated with or dependent on a partial and of course minute interference with nutrition or inflammation of the Gasserian ganglion, since simply *portions* only of the ganglion have been affected.

The irregular distribution of even ophthalmic shingles, and its not following the laws framed for it by a very large majority of the cases reported, may be explainable by abnormal nerve distribution. The implication of neighboring parts and encroachment on other tissues may also be due to variations in nerve connections and distribution. I would call attention to these variations as given at page 130 in the "Handbuch der gesammten Augenheilkunde," by Merkel, who has collected, and comments on, all reported variations in connection and distribution.

TREATMENT OF CASES OF HERPES ZOSTER FRONTALIS BY ELECTRICITY. ARTHUR MATHEWSON, M.D., Brooklyn.

Case I is of special interest, as forming an exception to Hutchinson's rule, that "whenever the side of the nose, *to its tip*, shows vesicles, the eye inflames severely." The patient, Dr. J. C. Shaw, late House Surgeon of the Brooklyn Eye and Ear Hospital, æt. 27, of good general health, was much exposed while driving, January 1st and 2d, 1873, and was struck on the right eye by a piece of snow on the 2d.

January 3d: He noticed a darting pain in the right eyeball coming on at intervals and lasting but a few seconds.

January 4th: The pain continues, but there is nothing abnormal in the appearance of the eye or surrounding parts.

January 6th: A slight conjunctival injection appears near the inner canthus.

January 9th: A little red spot at the inner part of the right upper lid first suggested the idea of approaching herpes zoster, to account for the continued and increasing pains which now began to radiate over the forehead. The following day left no doubt on this point, for a well-marked characteristic eruption appeared about the root of the nose and at several places on the right side of the forehead and top of the head.

January 13th: The *eruption has extended over the side of the nose so as to almost cover it, even to the tip. The eye shows nothing more than some conjunctival injection. The cornea is perfectly clear, and the iris slightly, if at all, affected.* Both lids are partially covered externally with eruption, and somewhat swollen. The pain has been at times intense, affecting the eye itself, and the orbit more than the forehead, and only

relieved by subcutaneous injections of morphine, until yesterday, when the galvanic current was tried with marked effect in mitigating the pain. From this time he used the battery freely at his own discretion, to the great relief of his sufferings and the apparent hastening of recovery. Quinine was used in large doses, and veratrine ointment applied locally.

January 15th: The pain has entirely ceased, and the eruption is on the wane. The case progressed favorably, and the patient was left in good health, the eye unaffected, no neuralgic pains, and with but few scars, one of these very near the tip of the nose.

Case II.—Henry Archibald, æt. 60, blacksmith, came to Brooklyn Eye and Ear Hospital, April 23d, 1874, with herpes zoster affecting right side of forehead. Ten days before, severe pain came on, which lasted a week before the eruption made its appearance. The right side of the forehead and the upper lid of the right eye were covered with vesicles and much swollen, so that it was difficult to separate the lids sufficiently to see the eye. The conjunctiva was injected and chemotic, but the cornea and iris were not affected. The vesication did not on this day extend down the side of the nose. The galvanic current was applied by Dr. G. M. Beard, to the immediate and almost complete relief of the pain, which had hitherto been intense. No other treatment was employed except tonic doses of the citrate of quinine and iron.

April 24th: There has been no severe pain since the application of the galvanic current yesterday. Some small young vesicles have appeared on the side of the nose, but do not extend far down. Local galvanization was repeated. The case progressed favorably from this time under continuance of the same treatment. The small vesicles on the side of the nose soon dried up as if aborted. Except for occasional neuralgic pains, which still continue, the eye was left in perfect condition, and the scarring of the forehead is less than I anticipated from the degree of vesication.

Case III.—Mrs. E., æt. 30 (Circa.), a patient of Dr. L. D. Bulkley, seen May 31st, 1874, by courtesy of Dr. Beard,

who was treating the patient by local galvanization. The eruption extended over the right side of the forehead, the eyelids of that side, and the right side of the upper lip. The side of the nose was not affected. There was conjunctivitis, but no other affection of the eye. The pain had been intense, but was greatly relieved by the galvanic current, which was at first applied twice a day. The patient made a good recovery under this treatment.

Case IV.—Charles Rodgers, æt. 28, watchman, a robust, vigorous-looking Irishman, came to the Brooklyn Eye and Ear Hospital, February 24th, 1873, with history of pain in right eye beginning four days previously, and after two days extending over the right side of forehead. There was nothing in the appearance of the eye to account for the pain, there being only slight conjunctivitis present. On close inspection vesicles so minute as easily to escape notice were found scattered over the right side of forehead and upper part of lachrymal sac. The minuteness of the vesicles was the most peculiar characteristic of this case. The pain was mitigated by the employment of local galvanization, and the patient disappeared after a few days.

The local galvanization, which was so successful in relieving pain and apparently in modifying other symptoms in these cases, was suggested by the good effect which my colleague, Dr. Prout, had obtained from its use in one of his cases.

Case V.—Edward H. Rowley, æt. 18, salesman, of good general health, was sent for my inspection, March 25th, 1873, by Dr. D. A. Dodge, of Brooklyn. Four days previously, pain began in supra-orbital region of the left side, and extended down the side of the nose. This continued two days. On the third day he first noticed an eruption at the root of the nose on the left side. This afterward extended over the left side of the forehead, but did not go downward over side of nose. The trouble about the eye was limited to some swelling of the lids and slight conjunctivitis. The patient suffered a good deal of pain, and was left with a deep cicatrix nearly half an inch in breadth, extending like a band across the forehead near the

median line. No other sequelæ. Galvanic current was not used in this case.

Case VI.—Mary Murphy, æt. 12, came to Brooklyn Eye and Ear Hospital, September 6th, 1871, with herpetic eruption on the left side of the forehead, some conjunctivitis, and history of pain for several days and nights. This patient soon disappeared, and the hospital record of her case is imperfect.

CANTHOPLASTY: A CLINICAL STUDY. By H. ALTHOF, M.D., of New York.

IN submitting the chapters on diseases of the conjunctiva and cornea, as found in the text-books, monographs, or journal articles of the present day, to a careful revision, and comparing whatever new or clinically useful has been said about them during the last fifteen years with the progress made in other branches of Ophthalmology, we cannot deny that, in spite of much time and labor spent, a proportional advance has by no means been made in this subject.

Follicular trachoma is at this moment just as much a real plague of mankind as it was years and years ago. Its rapid spread through hospitals, military depots, prisons, schools, factories, etc., etc. Its obstinate resistance to even the most careful and consistent treatment, the constant relapses leading so often slowly, but with frightful certainty, to ultimate destruction, and the suffering it causes the patient, have all earned for it the reputation of the most nefarious of conjunctival affections. Its literature might fill a respectable library, and it is true that our knowledge of its anatomical character has, during the last twelve years, been materially advanced, thanks to the researches of English, German, and Dutch authors. But as far as the therapeutic means at our disposal are concerned, the laws laid down by Graefe in 1856 still hold good. Says this greatest of all clinical observers: "It is exclusively to caustics that we owe the good results we see in the treatment of trachoma, and only to a careful selection of those agents, to their discreet application in regard to energy and frequency, must we look for still better ones in future. But no matter to what nicety and precision we may be able to carry their use,

one fundamental principle will hardly ever be shaken: the caustic must never be applied with intention to destroy the so-called trachoma follicles; it must only irritate them, and by such repeated irritation produce changes in the diseased tissues, which will either lead to total absorption, or at least to such a state of things in the affected membrane, that the nefarious consequences of vascularization of the cornea are prevented, stopped, or paralyzed." The chief representatives of this class of remedies are nitrate of silver in substance, solutions or combinations with nitrate of potassium and the sulphate of copper; and if we add to them the application of water of different temperatures, the inoculation of blennorrhœa or circumcision of the cornea for the most desperate cases, coupled with such internal remedies or dietetic rules as circumstances may require: we then have the whole of the treatment of trachoma of the present day. How unsatisfactory it is, every one knows who is familiar with great institutions making the study of eye diseases a specialty, or with blind asylums and houses of refuge which offer shelter to the victims of granular lids.

The next disease to which I have to call attention is diphtheritic conjunctivitis, by far the most dangerous of all external ophthalmiæ, but fortunately also very rare; so rare, indeed, that its existence in New York in the genuine form was at one time positively denied. I am sorry to say that since then we have seen more of it than we wished. All over the world oculists still look upon Graefe's famous article in 1854 as the classic picture, neither has any better mode of treatment been proposed than what he there laid down.

But how very little have local depletion, the constant use of iced compresses, most energetic use of calomel, the best of diet, etc., etc., done to arrest the destructive march! And what confidence can we put in them for the future, since we have learned that the characteristic infiltration which we sought to relieve thereby, because of the dangerous pressure from the swollen lids on the ball, and in the change of circulation following it, is due to invasion of those lowest of organizations, called bacteriæ, which care neither for the fire of the strongest chemical reagent nor the ice-bath continued for days and weeks? Before the year 1869, I have never seen but one result

in typical, genuine diphtheria: destruction. I therefore believe that we shall have to put more faith in mechanical means which may be able to diminish the pressure leading so rapidly to mortification of the cornea.

There is no conjunctival disease of a serious nature which offers to the oculist better chances of success than *blennorrhœa* in its different forms; simple blennorrhœa, whether acute or chronic, with or without deep-seated changes of tissue, gonorhœal ophthalmia, and ophthalmia-infantum, are foes whom we may in most cases expect to conquer, if they only have not been allowed to go too far. Graefe's expression of an "almost always victorious" treatment is well chosen. Here the recommendation of cold water and the caustic is as old as the first description of the disease; the last fifty years have only defined their indications more strictly, and advanced some very subtle but very valuable modifications in their use, without in any way altering the principle. But even the most careful and skilful physician will find cases baffling all his efforts, and of such virulence that his therapeutics work far too slow to prevent the saddest consequences.

The class of conjunctival affections which I have to mention now, and on which I beg leave to make some more detailed remarks, is one of particular interest, both on account of the frequency of its occurrence, the violence of its attacks, and the frequency of relapses, and because of the different opinions expressed in regard to its pathogenesis. I refer to what is called scrofulous, strumous, or lymphatic conjunctivitis, herpes of the conjunctiva, or with a more modern term, phlyctænular conjunctivitis resp. keratitis. The great majority of physicians still believe in a vicious diathesis (dyscrasia) as the cause of the trouble, and nowhere have I found the plain statement, that a general disease of the blood has nothing to do with the form in question. There can be no doubt that it proves more violent and more obstinate in scrofulous individuals than in the healthy, but that is a different thing altogether. In itself, phlyctænular conjunctivitis must be looked upon as a purely local trouble. Let us take a very common and very bad-looking case: we find the lids more or less swollen and glued together by thick crusts. They cannot be opened without the

most violent protest of the little patients, who try with all their might to shield themselves against the faintest ray of light, by burying their faces deep in the pillows of the bed. After opening the eyes, which I have often been obliged to do under ether, we find the conjunctiva deep-red and infiltrated, particularly the *cul-de-sac*, with numerous superficial losses of substance, or small grayish ulcers producing a moderate amount of thin muco-purulent secretion,—cornea generally intact in the centre, but showing at the periphery a quantity of small bluish protuberances or open excoriations. The head and face are covered with brown or yellow crusts, which, when removed, expose the swollen, easily bleeding cutis. The mucous membrane of the nose a prey to chronic inflammation from a simple catarrh to a most offensive ozæna, the alæ nasi thickened to thrice their normal circumference; nostrils closed by hard crusts, almost in contact with the massive, puffed, and cracked upper lip; the concha of the ear changed into a shapeless, encrusted mass; copious discharge of yellow or greenish matter from the external auditory canal; glands of the neck and chin painful and hard, or already softening and filled with pus; general condition miserable; no sleep, no appetite; in the majority of cases obstinate diarrhœa with more or less emaciation. This is the picture of a case that will at once be claimed as "scrofulous," and treated accordingly. But if the physician would only once call at the house of the patient, and look at the hygienic conditions under which such children usually live, he would easily see how unnecessary it is to call in "scrofula" in order to explain the state of things. In most instances he will find the child in an overheated, badly-ventilated room, of course on the bed, its face buried in feather pillows, which it holds over its head with a frantic effort against any attack of the mother or physician. The exposed occiput is covered with eczema in all its states, from the simple eczema rubrum to the ulcerating form, produced in the first instance by the heat of the pillow on which the child slept. The profuse and constant perspiration has irritated and macerated the soft epidermis; the child at once began to scratch, and every one who sees a good deal of small children, knows that even the youngest baby scratches with a marvellous skill and energy, not with its hands

alone, but by throwing the head backwards and sidewards, rubbing it against everything within its reach, and never stopping till the small vesicle, the first state of eczema, is destroyed, and a small loss of substance produced, which is covered by a thin crust. As soon as the latter is noticed, the child is kept doubly warm; the process repeats itself, grows in extent and intensity, and in a few days destroys the epidermis over the whole cranium, goes over the forehead to eye and nose, and down the side to the ear, causing at once an almost absolute sleeplessness, followed by loss of appetite and digestive troubles. Weeks pass in this way, without proper advice being looked for, and only when the whole store of patent medicines and nostrums internally and externally has been exhausted, the patient is brought to the dispensary in a truly pitiful state. If the physician at once protests against the feather pillow and hot rooms, and insists upon fresh air, the most scrupulous cleanliness, frequent bathing, good food given at regular hours, if he treats the eczema in the well-known old way, and the eyes as he would a common but aggravated conjunctivitis, he will find out quick enough that he needs neither cod-liver oil, calomel, nor sulphur auratum to see his charge recover. But after getting well once, it is well known how often relapses set in, and against those we have so far been almost powerless.

These remarks on the present state of treatment of the most important conjunctival affections show clearly that it is yet a grateful task to pay some attention to their therapeutics, and when, over eight years ago, I saw for the first time a very striking result from a proceeding not yet methodically employed, I remembered the following words of Graefe: "We do not only advance therapeutical science by searching after entirely new forms of treatment, but just as much by submitting in a strictly empirical way to a close investigation those of them which have hitherto lacked a firm basis. It is particularly the duty of all colleagues who have a very large material at their disposal, to work in this direction, and try by a great number of carefully observed cases to sift facts from deceiving accidents. Joint activity alone can separate the chaff from the wheat in the overloaded granary of ophthalmological therapeutics."—*Archives*, vi. ii. 122.

Starting from the point of view that it would be desirable to diminish or paralyze the pressure of the lids on the eyeball in a very large number of conjunctival diseases, I found that so far three proceedings had been employed to achieve the object in view. The first is the excision of pieces of conjunctiva. Graefe himself looks upon this procedure as useless in the majority of cases. It may, and often does, produce a temporarily remarkably favorable result, but this is generally and quickly paralyzed by the tendency of the wound to form luxuriant granulations, or by the formation of deep scars, which again give rise to irritation and vascularization of the ball itself, seriously impeding the free use of the organ for the future.

The second method consists in cutting out an oval part of the palpebra itself, leaving the wound to heal by granulation. I have often tried it without seeing more than a very passing relief, and then only as far as the upper lid is concerned.

The third and far the most important is the simple slitting of the outer commissure involving the skin, cellular tissue, and superficial layers of the orbicularis, without opening the conjunctival sac. The angular palpebral artery is invariably cut, and a very copious hemorrhage follows, which used to be considered the principal source of the good results observed. But even this procedure, by far the most effective of the three, gave only momentary although excellent results; so the idea suggested itself to make them permanent by modifying the operation so as to prevent the quick healing of the parts separated. It is an easy matter to accomplish: the cut is made deep enough to open the sac, and the conjunctiva is united to the skin by 3–5 sutures. It is the operation long known under the name of Canthoplasty, recommended principally for the treatment of blepharophimosis and also tried in various conjunctival affections (Graefe, Pagenstecher, Sämisch), without having ever been methodically put to a severe test. The latest remarks on the subject which I have been able to find in literature, are contained in an article of W. Wagner's, (Zehender's *Monatsblätter*, Februar–März, 1874), criticising Dr. Ryder's review of Dr. Schmid's report of the proceedings in the eye department of the city hospital at Odessa. Wagner gives us clearly enough

to understand that in his eyes Schmid has done "tarsotomia" in a great many cases without proper indications, and I am very much inclined to share his opinion,—but on the other hand believe that so far canthoplasty has been decidedly underrated in efficiency on account of want of careful trials on a large scale. The experiences of a great many friends of mine, and my own, dating back to the year 1865, have made us look upon this simple procedure as a valuable contribution to our therapeutics.

I. Trachoma.—Most of the cases operated on have been those of follicular trachoma in all its forms and different stages, from the fresh acute state, with only copious lachrymation and intense photophobia, to the severest chronic, with almost total destruction of conjunctiva, fleshy pannus of cornea, or even formation of staphyloma with absolute blindness. The indications were either to avert the danger to vision or to relieve suffering where sight had been destroyed. I have on record 400 cases thus treated during the last 7½ years,—not by any means the whole number which I have done myself, or which I have seen done by friends, but fully sufficient to entitle us to give the procedure a position. The very first case (March, 1867) was striking. A sailor, 30 years of age, in good health, having suffered for nine years from granular lids, had been previously treated in New York, Boston, Philadelphia, and other places. The present violent outbreak came after an exposure of 10–12 hours to a severe storm, which he had to weather in an open boat 2 months ago. He entered the Infirmary in the following condition:—Conjunctiva of both lids and bulbus changed into a thick solid mass of trachoma follicles, furrowed by white scars produced by caustics; thin greenish secretion; highest degree of photophobia; both corneæ absolutely opaque, perforated upwards and outwards with large prolapse of iris; good perception of light. Canthoplasty done and wounds united by 5 sutures on each side; the lids, which could now be easily everted, were treated with pure nitrate followed by careful neutralization and constant application of iced compresses. Twenty-four hours later there was an abundance of purulent secretion, lids readily opened, photophobia materially diminished; patient feels very much relieved. On the third day the sutures were removed and the usual treatment continued, the case pro-

gressing very favorably. On the 32d day I made a large iridectomy on both eyes inwards and downwards, and discharged the patient on the 53d day in the following condition:

Right eye: Lids yet a good deal thickened; secretion trifling; cornea opposite the coloboma bright and clear, sees Snellen XX distinctly in 6 feet with stenopæic apparatus.

Left eye: Almost the same state and same vision.

This man I have been able to follow up ever since 1867 to this day; he is now a salesman in a clothing-store, and does well. So far he has not had a relapse, but uses a solution of sulphate of copper (gr. V) now and then, particularly during summer. V. = $\frac{XI}{XX}$ (March, 1874).

The second case I observed in June, 1867. Patient was a student of law. Disease of 7 years' standing. Had always been under treatment, principally by nitrate of silver, which has given the conjunctiva the usual gray-blue color. Cornea thickly vascularized; numerous superficial losses of substance, lids moderately swollen; secretion abundant. The young man cannot walk alone, and is led by his father. Canthoplasty was done at once, the eyes afterwards treated with sulphate of copper and cold water. In December, 1867, patient returned to his studies, and has now been for two years established in this city as a lawyer. No relapse yet. V. = $\frac{XII}{XX}$ (March, '74).

Encouraged by these first two cases, I have since done the insignificant little operation in a vast number of patients, the Eye Infirmary furnishing us with an enormous number of trachoma-sufferers; and all who have tried it have found it more or less valuable. I have no doubt that I have often done it where the case would have given just as good a result in the end without it, but the relief for the patient is so decided, it facilitates the application of other remedies to such a degree, and supports particularly the chief curative agent, the caustic, so evidently, that the limits of indication have grown wider and wider. Neither do I doubt that the permanent lessening of the pressure of the lids on the ball acts favorably against relapses. I am far from saying it prevents them altogether, but it certainly limits them to the minority of cases; and if a relapse appears, it is never very violent, and yields more readily to the

usual treatment. Taking further into consideration the fact that I have never seen a patient disfigured or even annoyed by symptoms directly brought on by the slitting of the outer canthus (blepharitis angularis, etc., etc.), I cannot blame colleagues, who have desired to give it even a wider range than I have done myself; I firmly believe that it will always prove a valuable contribution to our antitrachomatous therapeutics.

Diphtheritic Conjunctivitis.—Four years ago my friend Dr. Allin asked me to see at the N. Y. Eye Infirmary a young woman suffering from genuine diphtheritis. The usual treatment had so far not been able to arrest the nefarious course of the disease, and although we were well aware of Graefe's warning, "I am opposed to scarifications, because even the slightest wounds must become infiltrated by diphtheritic deposits, and thereby give rise to a new stasis of blood,"—we decided to do a canthoplasty, believing that the much dreaded specific infiltration of so small wounds as the operation produces could not possibly be of vital consequence, compared to the advantages which we might gain by a quick and permanent diminution of the pressure of the lids. The result of this first trial is described in the Transactions of the American Ophthalmological Society, 1871, page 91. Since that time I have kept on record 23 cases of more or less virulence, all treated without internal remedies, if the latter were not necessitated by the general condition of the patient, but in all cases without calomel. Canthoplasty and iced compresses, followed during the blennorrhoic state of the affection by the use of caustics, being the treatment. The worst of these cases I beg leave to mention minutely:

Girl of 4 years, seen first on May 5th, 1870. The child was taken home by her mother from the ship of her father in an open boat in very boisterous weather; got thoroughly wet, and complained of headache next morning. Eyelids swollen and closed by thin crusts, which were taken off by frequent washing with tepid water. The case grew worse during the day and following night, offering on the 3d day the following appearance: Lids badly swollen, of a blue livid color, excessively painful and hard to the touch; a thin, greenish secretion, mixed with white mucous flakes, running over the cheeks. Patient is very

restless; pulse 150–156; respiration, 48; temperature, 101°. Finding it impossible to get a view of the conjunctiva on account of the restlessness of the child, I administered a small dose of chloroform, which allowed a careful inspection. Diagnosis: Diphtheritic conjunctivitis. Treatment: iced compresses, mild aperient, no restriction in diet. Next day I saw the patient in company with Dr. Sinclair, finding her decidedly worse. Pulse, 160; temperature, 102°; nostrils closed with thick, greenish crusts; lips dry and coated; mucous membrane of mouth and fauces swollen and covered with white patches. Chloroform was again used and the lids carefully opened, when a glimpse obtained of the cornea showed the epithelial layer already fully infiltrated, with small losses of substance upwards. Being convinced that the next few hours would bring perforation of the cornea, I did canthoplasty on both eyes, making the wound as small as possible, and carefully uniting the conjunctiva to the skin by 3 sutures. The lids could be well everted at once, the conjunctiva offering all the symptoms of diphtheria in its worst state, of a gray color, bloodless, and very hard. Ordered ice applications and stimulants internally.

May 7th: The child had a bad night. I found new diphtheritic patches round the anus and vulva; the concha of left ear was badly swollen; temperature of body, 102; lids thinner than day previous, soft and flabby, easily evertible; secretion thin and discolored; cornea not worse. Wound of the operation stiff and thickly infiltrated; sutures hold well. Same treatment aided by quinine and chloride of potassium.

May 8: Decided improvement of all symptoms locally and generally. Lids can be readily everted without aid of chloroform; swelling rapidly subsiding; conjunctiva showing spots of vascularization; cornea clearing up in its lower halves. Sutures all removed; treatment continued with addition of atropine.

May 9: Patient has constantly improved; swallows well; diphtheritic patches round anus and vulva in statu quo; lids reduced almost to normal size; copious blennorrhoic discharge; conjunctiva shows large, velvety patches, which were slightly cauterized; cornea clearing; ulcers healing. Treatment continued.

After this day the child improved steadily but very slowly, so

that I could not pronounce the eyes out of danger before the 19th. I saw her afterwards every day till the end of June, when she left for the country. In December she was again brought into town. The cornea presented two pretty large opacities corresponding to former losses of substance. In April of this year they were very small and circumscribed, apparently not affecting vision in the least.

During the four years following this first experience of the efficiency of canthoplasty, I have used it in all the cases I have seen (23), with the exception of one, a mother infected by her child, who did not return to the infirmary until the 5th day after the diagnosis was made and her attention called to the dangerous character of the disease. The cornea was then perforated at three different spots and vision hopelessly lost. Admitting now that half of the whole number would have recovered without the operation, there are 11 left which I believe would under no circumstances have ended so favorably. None of those 22 cases was lost; no cornea perforated. Seven eyes required iridectomy for central opacities, four of which I did myself, one was operated on by a friend of mine, and the two remaining are still at large. In no case was there any difficulty in the healing of the wound, in spite of more or less infiltration of the margins, nor was any deformity produced. As far as I know, canthoplasty has not been previously introduced as an auxiliary remedy in diphtheritis, and if it ever should be proved, beyond any doubt, that the real cause of this terrible disease is the immigration of bacteria into the tissue, internal treatment will be at once entirely given up and local therapeutics will reign supreme.

3d. *Blennorrhœa* (B. gonorrhoica and B. neonatorum).—I have already quoted Graefe's phrase of an "always victorious" treatment for blennorrhœa, and the expression is certainly true in regard to the vast majority of cases, if they come under our hands at not too late a moment. Nevertheless there is a number, particularly of gonorrhœal ophthalmia, in which our agents work far too slow for arresting the disease and its destructive tendencies, so that we cannot conscientiously decline to consider further contributions to our present therapeutic means, providing they are based à priori on a sound principle, and supported

by practical observation. I am not aware that canthoplasty has ever been used as a helpmate to the usual treatment of blennorrhœa.* My experience with it has been very limited; I have operated on 13 cases of gonorrhœal ophthalmia in 4 years (out of a total number of 53), and on 3 of O. neonatorum (total number 64), a very small quantity, but very important in quality. I beg leave to give the first case of the former in detail: In April, 1870, I saw a child, late in the evening, in consultation with Drs. Kudlich and Geissler, in Hoboken. The little patient was a very handsome, uncommonly well-developed girl of 4 years of age, who was brought to Dr. Geissler 2 days previous, suffering from what he then supposed to be a severe acute conjunctivitis. Ordered ice-compresses, and a dose of citrate of magnesia. Next morning, all the symptoms of gonorrhœal ophthalmia having developed, the doctor examined the vulva, and found a very virulent catarrh. Dr. Kudlich was at once called in, and it was then ascertained that 5 days previous a rape had been committed on the child by one of the boarders, who, when brought before court, was suffering from gonorrhœa. He confessed his guilt, and was promptly convicted. I found the child in bed in great agony, and administered chloroform to make a careful examination. The upper lid of right eye immensely swollen, overlapping the lower completely, and hanging down far over the cheek, of a blue-reddish color, and so tight that eversion was impossible even under the influence of the anæsthetic; a thin, yellow secretion oozing from under the lid in a constant stream. The chemotic conjunctiva bulbi covered the cornea so much, that only its centre could be seen; it was perfectly opaque, with a deep ulcer, of which the base had already begun to protrude. Canthoplasty was at once performed; the lid could then be easily and fully everted. Treatment: Cauterization with pure nitrate of silver, with careful neutralization by salt water; perforation of ulcer; atropine; iced compresses; small doses of morphia to keep the child quiet.

* The *Handbuch der gesammten Augenheilkunde*, Vol. III., 1st Part, reached me only a few days ago. Arlt says on page 443: "Canthoplasty was used by Graefe as a pressure—diminishing and antiphlogistic remedy in acute blennorrhœa."

2d day. *Under Chloroform.*—Swelling of lid and chemosis materially diminished. Secretion still very profuse. Cornea can be thoroughly examined; looks dim and opaque. Ulcer has been punctured again in the morning, and was reopened. Wounds of canthoplasty well united. Same treatment.

3d day. All symptoms improved. Sutures taken out. Treatment continued.

The case then progressed favorably. Chloroform was dispensed with after the 7th day. The child left three months later for Europe in the following condition: Lid almost normal; in no way disfigured. A small circumscribed leucoma at the margin of the pupil. Vision apparently not injured. Cases of such virulence are not so very rare, and may be saved by the old régime alone; but with an ulcer with protruding base, the cornea stands very little chance while the trouble in the lids is still florid. I believe that without canthoplasty this ulcer would have led to a broad perforation with its well-known consequences, the lids could never have been treated so thoroughly, and, finally, I should have considered it a very satisfactory result had a sufficient part of the cornea been saved to allow an iridectomy 6 months later.

The second case came under observation on the 4th day after the first symptoms had shown themselves. Was ascribed to a cold which the patient, a policeman, believed to have taken while on duty during a stormy night. Gonorrhœa contracted 11 days ago. All the symptoms severe; right cornea thoroughly hazy, left one perforated with prolapse of iris. The little operation was done at once, and the usual treatment followed. The sutures removed on second day. Final result: 12 weeks after first visit, right eye, vision normal; on left cornea a small, well-circumscribed leucoma adherent, with hardly any trouble of vision.

During March and April of the present year, I have treated 3 journeymen tailors, who lived in the same room. One of them was suffering from gonorrhœa, and the two others were infected undoubtedly by using the same washing utensils. Two of them were suffering in both eyes, the third from the right alone; the good left eye of the latter I put at once under an impermeable bandage. The others were treated in

the usual way, with canthoplasty added; all made a perfect recovery. The rest of the 13 cases do not need mentioning in detail; they all belonged to the worst class. Canthoplasty proved a very valuable assistant to the old treatment: diminished suffering, although it did not materially lessen the time in which the disease generally runs its course.

The three children with ophthalmia infantum, which I mentioned before, were all sadly neglected specimens (treated by warm applications), all showing perforations of cornea, with highly degenerated conjunctiva. In all of them the improvement was at once manifest after canthoplasty had opened the way for a sensible treatment of the lids; and in all three sufficient parts of the cornea were saved to allow large iridectomies.

4th. *Phlyctænular Conjunctivitis and Keratitis.*—It was this affection which furnished the largest amount of patients, and the results of the operation were so gratifying that it was at once adopted by the surgeons of some of our large institutions. It would be abusing the patience of the reader were I to cite cases. The results are shortly these: The operation stops at once the severe photophobia, which seems to be the principal cause of suffering. It allows a free use of such remedies (cauterization of cul-de-sac, red ointment, atropine) as before could only be employed either imperfectly or not at all. That this is a great advantage every one knows who has ever observed with what intense energy the little ones squeeze their lids the moment they are touched, or who has heard the excuse of the nurses that it is impossible to apply the remedies recommended. The greatest advantage, though, is the prevention of relapses. Dr. Wagner (l. c. page 110) says: "It would be interesting now to learn whether the author has succeeded in preventing somewhat the relapses of phlyctænular conjunctivitis by this operation (i. e., splitting of the outer canthus). If so, he would be clearly entitled to the gratitude of the whole ophthalmological world." Well, the surgeon who first used canthoplasty in phlyctænular conjunctivitis will be grateful to Dr. Wagner for the compliment, be he who he may. This prevention of relapses not only in some, but in the vast majority of cases, say at least 85 per cent., was the first good office

I claimed for the operation as far back as 1869, and since that time all those who have adopted it in this country have often been witness to its efficiency. I am sorry not to understand Russian, so as to be able to read Dr. Schmid's Odessa report in the original. The report of Dr. Ryder in Zehender's *Monatsblätter* for January, 1873, does not state clearly when simple splitting of the canthus, and when canthoplasty was performed. But in regard to this power of preventing relapses, it will need only very little experimenting to convince the most sceptical. In this country the operation has been done for all forms and in all states of phlyctænular conjunctivitis and keratitis. My principle is to perform it even in very mild cases, if they prove very obstinate.

5th. *Keratitis diffusa.*—Hutchinson's disease is very frequent with us. The best remedy we have is, and very likely always will be, moist heat, such as recommended by the English oculist. Everybody knows the obstinacy of the disease and the difficulty of treatment—the suffering of the patient when what was gained through months is lost again in a few days;—and therefore it may be well to mention the only case in which I have performed canthoplatsy. The patient was a girl of 10 years of age—a typical case—brought to me by her father, to whom I clearly stated the character of the affection as inherited syphilis. He then informed me that his wife a year and a half ago gave birth to a child suffering from pemphigus, which caused its death on the 11th day; that she was ailing after this, and had died some 7 months ago, the physician in charge having at that time expressed his opinion that syphilis, contracted from the baby, was at the bottom of her trouble. This gentleman devoted himself at once entirely to the care of his daughter, applying himself the warm applications for from 6 to 8 hours every day. The patient did very well in the beginning under the usual general and local treatment, but had frequent relapses, and, although gaining visibly in health, did not seem to have great chances for ultimate recovery. After 27 months of constant care, during which time the warm applications had only been interrupted by a trip to Europe, and by a stay of 2 months with a relative, the child suffered from a fresh attack of great violence. I proposed canthoplasty, stopped the warm

poultices for a week to see the wounds well healed, and then began again with them very energetically. Three weeks were enough to bring on a surprising cure. For two years the child has been well with a vision of $\frac{XIX}{XX}$. This is so far an isolated experience with me. I hear that others have done the same, but cannot state any results. I think it justifies further proceedings in the same direction.

6th. *Ulcus serpens* (Saemisch).—This nefarious form is not as rare with us as we might well wish, and in spite of the best care on the part of physician and patient, the "hypopion keratitis" (Roser), or non-irritating suppurative infiltration of the cornea (Graefe), is a foe against whom we are generally absolutely powerless. I have done canthoplasty together with the usual treatment of puncturing or splitting the ulcer in 2 cases, without observing any effect either good or bad.

7th. *Softening exudations in the cornea.*—The cases of keratitis, leaving more or less dense opacities in the cornea, which swell from time to time, and keep up an almost constant state of irritation, are not frequent. With permission of Dr. Loring, I briefly state the following case:

Healthy woman of 25 years. Keratitis with perforation 2 years ago, leaving a large leucoma adherens. Frequent vascularization of the cornea together with decided symptoms of secondary glaucoma induced the doctor to perform iridectomy. The glaucoma disappeared, but the irritation of the cornea showed itself as often as before. But after canthoplasty, 10 months ago, this also has ceased.

In diseases or malformations of the eyelids, canthoplasty has for a great many years been so fully tested that further remarks on this class of affections seem superfluous. It cannot be too highly recommended as a helpmate of the various operations in use for trichiasis, entropion caused by shrinking of the conjunctiva after trachoma, etc., etc.

I would call special attention to cases of total blindness brought on by granular lids, blennorrhœa, and diphtheria, in which the operation was performed solely for the purpose of relieving the sufferings of the patients caused by the chronic irritation of the conjunctiva. The annoying lachrymation and

secretion were in almost all cases entirely stopped or greatly lessened, and a comparatively comfortable state of things established.

Only seldom have I been obliged to repeat the operation. A couple of very obstinate cases of trachoma happening in the practice of friends of mine or in my own, where it seemed advisable to perform it for a second time, gave excellent results.

The value of the procedure may be stated in a few words: in trachoma, diphtheria, and blennorrhœa it may prove the chief agent of treatment. In trachoma and phlyctænular conjunctivitis and keratitis, its principal merit lies in shortening the attack, preventing relapses, relieving suffering quickly, and supporting powerfully the efficiency of other remedies. In diseases of the lids requiring operations it greatly improves the chances of the latter. In ulcus serpens (Saemisch) and diffuse keratitis (Hutchinson) it may become a desirable support of the treatment so far in use. Adding to this the fact that it is very easily done, that it can never do any harm, and never causes any disfiguration if properly performed, I am sure it will not be entirely overlooked as a contribution to the ophthalmic therapeutics.

About the performance of the operation I do not need to speak. If the lids are well separated, a simple cut down to the malar bone, producing a wound of the outer integument not larger than 8 mm., will in most cases fully relax the pressure of the lids. Slight modifications of this first act must be left to the discretion of the surgeon. The greatest neatness is of course required in uniting the conjunctiva to the skin. Three sutures are generally sufficient, but the operator must judge for himself how many he thinks proper to use.

SCHNELLER'S OPERATION FOR TRICHIASIS AND ENTROPION OF THE LOWER LID. By J. S. Prout, M.D., of Brooklyn, N. Y.

In the *Annales d'Oculistique* for March–April, 1874, there is a description of Schneller's operation, taken from A. Von Graefe's *Archiv für Ophthalmologie*, vol. xix. part 2. It is as follows: Two incisions, through the skin only, parallel to the palpebral border, are united at their ends so as to include an elliptical portion of skin, which is left in position, but the skin above and below it is dissected up, and the two free margins are united through their whole extent by sutures *over* the circumscribed portion, which is thus, as it were, buried. After a time its epithelium seems to disappear and it fuses with its covering.

The covered piece acts the part of a splint in stiffening the lid, and thus opposes the tendency to inversion; at the same time the skin of the lid is shortened by the distance between the two incisions. I have done this operation once and obtained a satisfactory result.

Mrs. H., æt. 77, consulted me a year ago on account of spasmodic inversion of both lower lids. On June 2, 1874, she came again, requesting that an operation should be done for the relief of her condition. There was no contraction of the conjunctiva nor trichiasis, but the inverted cilia irritated the conjunctiva, causing spasmodic action of the orbicularis muscle. Schneller's operation was advised, and on the 4th, two days later, it was performed, without anæsthetic or assistant, on the left eye which was the worse of the two. Making the incision round the piece to be covered in was found to be the only difficult step of the operation. The upper line was carried about one and

one-half lines from the palpebral border, the lower about three lines farther down. When their extremities were united, the ellipse thus made was about three lines in vertical and nine lines in horizontal measurement; to close which four or five sutures were introduced. On the 6th, the lid was but little swollen; the edges of the wound were partially united; there was no inversion. Some of the sutures were now taken out. On the 8th, the remaining sutures were removed, and, as there was not complete union, contractile collodion was used to close the wound. On the 13th, there was nearly complete union. A small abscess, or stye, more properly, had formed at the palpebral border,—not in the wound. Collodion was applied again. On the 16th, the stye was incised; the wound had united. On the 27th, there was no inversion; the lid was firm.*

The right eye, which was affected to a much less degree, was not operated on, but contractile collodion was used with good effect. When the inversion of the left lower lid was cured, and with it the irritation of the conjunctiva, the inversion of the right became but little annoying, and by the use of the collodion was entirely overcome.

* On the 7th of August, nine weeks after the operation, at the site of the wound there was a small, scarcely noticeable, wart-like puckering or projection of the skin, which could have been easily snipped off with scissors. The patient was perfectly satisfied with the result.

A CONTRIBUTION TO THE STATISTICS OF CATARACT EXTRACTION OF ONE HUNDRED AND EIGHTEEN RECENT CASES. By C. R. Agnew, M.D.

The cases in the tables that follow are given as they occurred, and without selection or exclusion.

They include several in which the most unfavorable prognosis was declared, and in which the bare chance of a good result was accepted by the subject.

Some of the desperate cases did well, and some in which a favorable prognosis had been declared did badly, thus showing that however carefully we may weigh probabilities we are liable to error, and that those who are blind with even seriously complicated cataract are entitled to a the chances of a good method of operating.

The methods of operating used were those known as Graefe's, Liebreich's, Lebrun's, and the "old flap." My opinion has at times been much unsettled as to the method which offers the best prospect for useful vision in the greatest number of cases. I have, however, about come to the conclusion that the Graefe operation is the best, provided the middle of the cut is not made far from the junction of the sclerotic and clear cornea.

An insufficient wound is the most dangerous complication of a cataract extraction. Some of the so-called membranes in the pupil were so delicate as to be detected only by careful scrutiny with the ophthalmoscope or oblique illumination.

I have great pleasure in saying that most of the work of watching and recording the cases has been done by my assistant, Dr. David Webster, whose accuracy and carefulness are proverbial.

EXTRACTIONS BY VON GRAEFE'S METHOD.

No. of Case.	Sex.	Age.	General Condition.	Character of Cataract.	Complications.	Anæsthetic.	Section Upwards.	Section Downwards.	Accidents in Operation.	Complications during Recovery.	Secondary Operations.	Resulting Vision.
1	F.	69	.....	Hard....	.....	None....	...	1	.....	.....	.....	V. = $\frac{1}{4}$
2	M.	65	.....	Hard....	.....	None....	...	1	.....	.....	.....	V. = $\frac{10}{50}$
3	M.	65	.....	Hard....	.....	Ether and Chlor.	..	1	Spoon used.	Membrane in pupil	1 needling.	V. = $\frac{1}{10}$
4	F.	(?)	.....	Hard....	.....	Ether....	...	1	.....	Membrane in pupil	4 needlings	V. = $\frac{20}{40}$
5	F.	68	.....	Hard...	Staph. post. touching macula.	Ether....	...	1	.....	Membrane in pupil	1 needling.	V. = $\frac{1}{40}$
6	M.	65	.....	Hard....	.....	Chlor....	...	1	.....	Membrane in pupil	1 needling.	V. = $\frac{20}{100}$
7	M.	58	Insane....	Hard....	.....	Ether....	...	1	.....	.....	.....	V. = 0
8	F.	62	.....	Hard....	.....	Chlor....	...	1	.....	.....	.....	V. = $\frac{20}{50}$
9	F.	62	.....	Hard....	.....	Chlor....	...	1	.....	Membrane in pupil	1 needling.	V. = $\frac{1}{4}$
10	M.	76	Feeble....	Hard....	.....	Ether....	...	1	.....	.....	.....	V. = $\frac{1}{4}$
11	M.	43	Corpulent.	Semifluid.	.....	Ether....	...	1	Some vitreous lost.	Iritis with closure of pupil.	1 iridectomy, 1 keratonyxis.	V. = 0
12	M.	75	.....	Hard....	.....	Ether....	...	1	.....	.....	.....	V. = $\frac{20}{50}$
13	M.	49	.....	Hard....	.....	Ether....	...	...	.....	Iritis with closure of pupil.	1 iridotomy, 1 needling.	V. = $\frac{20}{100}$
14	M.	43	Diabetic Cataract.	.....	Diabetis.....	Ether....	...	...	.....	.....	.....	"Reads ordinary print."

15	M.	76	.....	Hard	.....	Ether	...	...	.....	.....	.....	V. = $\frac{20}{70}$
16	M.	76	.....	Hard	.....	Ether	1	...	.....	.....	.....	V. = $\frac{20}{70}$
17	M.	43	Good	Hard	.....	None	1	...	.....	Iritis; closure of pupils.	Iridotomy	V. = $\frac{20}{50}$
18	M.	49	.....	Hard	.....	None	...	...	.....	.....	.....	V. = $\frac{20}{50}$
19	M.	43	.....	Hard	.....	Ether	...	...	.....	.....	.....	V. = $\frac{1}{12}$
20	M.	73	.....	Hard	.....	None	...	1	.....	.....	.....	V. = Counts fingers.
21	F.	68	Gouty; enlarged joints.	Hard	.....	None	...	1	.....	Iritis and closure of pupil.	Iridotomy	V. = $\frac{20}{70}$
22	F.	45	Corpulent	Hard	.....	Ether	...	1	.....	Membrane in pupil	.....	V. = $\frac{20}{200}$
23	M.	61	Atheromatous arteries.	Hard	.....	Ether	...	1	.....	.....	.....	V. = $\frac{20}{70}$
24	F.	65	Good	Hard	.....	Ether	...	1	.....	.....	.....	V. = $\frac{20}{50}$
25	F.	71	Gouty; enlarged knuckles	Hard	.....	Ether	1	...	.....	Iritis with closure of pupil.	Iridotomy	V. = Perception of light.
26	M.	60	.....	Hard	.....	Ether and Chlor.	1	...	.....	.....	.....	V. = $\frac{20}{40}$
27	F.	63	Poor	Hard	.....	Ether and Chlor.	1	...	.....	Iritis; membrane in pupil.	.....	V. = Sees to go about alone.
28	M.	54	Fair.	Hard	.....	Ether and Chlor.	1	...	.....	Membrane in pupil	Keratonyxis	V. = $\frac{20}{50}$
29	M.	75	Extremely feeble.	Black Cataract.	.....	Ether and Chlor.	1	...	.....	Hemorrhage from choroidal vessels.	.....	V. = 0

No. of Case.	Sex.	Age.	General Condition.	Character of Cataract.	Complications.	Anæsthetic.	Section Upwards.	Section Downwards.	Accidents in Operation.	Complications during Recovery.	Secondary Operations.	Resulting Vision.
80	M.	43	Corpulent.	Semifluid.	Detachment of retina of fellow eye	None	...	1	Hyaline ruptured before section was complete; spoon used; some vitreous lost.	Thick membrane formed	Paracentesis; iridotomy	V. = $\frac{10}{60}$
81	F.	35	Poor.....	Semifluid.	.....	Ether and Chlor.	1	...	.....	Membrane in pupil	Keratonyxis	V. = $\frac{10}{10}$
82	F.	70	.....	Hard....	.....	Ether and Chlor.	1	...	.....	.....	.....	V. = $\frac{10}{100}$
83	M.	60	.....	Hard....	.....	None	1	...	.....	Membrane in pupil	.....	V. = Counts fingers.
84	F.	72	Gouty; enlarged knuckles	Hard....	.....	None	1	...	.....	.....	.....	V. = $\frac{10}{10}$
85	F.	62	Good	Hard....	.....	Ether ...	1	...	.....	Membrane in pupil	Keratonyxis	V. = $\frac{10}{10}$
86	M.	57	Paralysis Agitans.	Hard....	Myopia with staph. post.	None	...	1	.....	.....	.....	V. = $\frac{10}{10}$
87	M.	48	Poor ...	Black cataract; fluid vitreous, and tough capsule. Congenital atrophy of fellow eye.	.....	None	...	1	.....	Conjunctivitis....	.....	V. = $\frac{10}{100}$

38	M.	47	Good.....	Hard.....	.....	None....	...	1	.....	.....	.....	V. = $\frac{20}{70}$
39	M.	57	Poor.....	Hard.....	.....	None....	...	1	.....	Iritis; membrane in pupil.	Iridotomy.	V. = $\frac{20}{30}$
40	M.	81	Marasmatic	Hard.....	.....	None....	...	1	.....	.....	.....	V. = $\frac{20}{40}$
41	M.	58	Poor.....	Hard.....	Myopia.....	Chlor....	1	...	.....	.....	.....	V. = $\frac{10}{50}$
42	F.	76	Asthma...	Hard.....	Visual field doubtful on nasal side.	Ether....	1	...	Cornea collapsed and wrinkled.	.....	.....	V. = $\frac{20}{200}$
43	F.	75	General senile atrophy	Hard nucleus; soft cortex.	.....	Ether....	1	...	.....	Pupil filled with soft lens matter	.....	V. = $\frac{20}{200}$
44	F.	57	Good....	Hard.....	Opacity of cornea.	Ether....	...	1	.....	.....	.....	V. = $\frac{20}{200}$
45	F.	57	Good.....	Hard.....	Opacity of cornea.	Ether....	...	1	.....	.....	.....	V. = $\frac{20}{200}$
46	F.	56	Had general dropsy twice; very weak.	Semifluid.	.....	Ether....	1	...	.....	Iritis; membrane in pupil.	Iridotomy.	V=Unknown.
47	F.	58	Dyspeptic.	Small nucleus; much soft cortex.	.....	Ether....	1	...	.....	.....	.....	V. = $\frac{20}{100}$
48	F.	74	Feeble....	Hard.....	.....	Ether....	1	.	Lens shaky, showing rupture of hyaline before section completed; cornea wrinkled.	Iritis; membrane in pupil.	.....	V. = $\frac{20}{100}$

No. of Case.	Sex.	Age.	General Condition.	Character of Cataract.	Complications.	Anæsthetic.	Section Upwards.	Section Downwards.	Accidents in Operation.	Complications during Recovery.	Secondary Operations.	Resulting Vision.
49	M.	74	Dyspeptic and half starved.	Hard	.....	Ether	1	.	Hemorrhage from limbus into ant. chamber; cornea wrinkled.	Membrane in pupil.	.....	V. = $\frac{20}{100}$
50	F.	60	Rheumatic and dyspeptic.	Hard	.....	Ether	1	...	Cornea wrinkled.	.....	.....	V. = $\frac{20}{60}$
51	M.	61	Good	Calcareous degeneration of capsule.	.....	Ether	1	.	Extracted capsule with forceps after ext. of lens.	.....	.....	V. = $\frac{20}{100}$
52	M.	55	.....	Old choroiditis; fluid vitreous.	Fellow lost by Extr. (panophthalmitis).	None	1	.	Lens in capsule extruded with vitreous by spasm of orbicularis.	Hyalitis	.....	V. = Sees to go about alone.
53	E.	67	Goitre; catarrh.	Hard	.....	None	1	.	Iris fell before knife and was cut.	Delicate membrane in pupil.	.....	V. = $\frac{20}{60}$
54	F.	58	Mother of 14 Children.	Hard nucleus; soft cortex.	.....	Ether	1	.	Bleeding into ant. chamb. from limbus; small fragment of cortex left in centre of pupil.	Iritis; membrane in pupil.	.....	V. = $\frac{14}{60}$
55	M.	61	Smokes from 6 to 10 pipes a day.	Hard	.....	None	1	.	Hyaline gave way on completion of iridectomy; removed lens with scoop; lost vitreous and left some cortex in field of pupil.	Eye lost by Hyalitis.	.....	V. = 0

56	F.	58	Dyspeptic; weak; nervous.	Hard; developed with much pain.	.....	Ether..	1	...	.....	Slight serous iritis.	.....	V. = $\frac{20}{20}$
57	F.	41	.....	Hard...	Extracted after 14 needlings; eye extremely myopic.	.....	1	...	.....	Membrane in pupil	.....	V. = $\frac{6}{100}$
58	F.	..	.....	Hard....	.....	.....	1	...	.....	.....	.....	V. = $\frac{20}{20}$
59	M.	57	.....	Hard....	.....	Ether..	1	...	.....	Loss of vitreous with prolapse of Iris from vomiting while coming out of anæsthetic state.	.....	V. = $\frac{20}{40}$
60	M.	50	.....	Hard....	.....	.....	...	1	.....	Cystoid cicatrix...	.....	V. = $\frac{20}{40}$
61	F.	..	.....	Hard....	.....	.....	...	...	.....	.....	.....	V. = $\frac{1}{10}$
62	F.	66	.....	Hard....	.....	Ether..	...	1	.....	.....	.....	V. = $\frac{10}{20}$
63	F.	36	.....	.....	.....	Ether..	1	...	.....	Membrane in pupil	Keratonyxis	V. = $\frac{20}{40}$
64	F.	58	.....	.....	Synech. post....	.....	...	...	.....	.....	.....	"Has sharp vision."
65	M.	40	.....	.....	.....	.....	...	1	Hemorrhage into ant. chamb.	.....	.....	V. = $\frac{20}{20}$
66	M.	70	.....	.....	Synech. post. and Staph. post. with previous iridectomy	.....	1	..	Spoon used to evacuate lens.	.....	.....	V. = "Reads Jaeger No. 8 at 7″."
67	F.	55	.....	.....	.....	None...	...	...	Spoon used to evacuate lens.	.....	.....	V. = $\frac{1}{70}$
68	M.	35	.....	.....	.....	.....	...	1	.....	.....	.....	V. = Not recorded.
69	M.	54	.....	.....	.....	Chlor..	...	...	.....	.....	.....	V. = "Can read and write."

No. of Case.	Sex.	Age.	General Condition.	Character of Cataract.	Complications.	Anæsthetic.	Section Upwards.	Section Downwards.	Accidents in Operation.	Complications during Recovery.	Secondary Operations.	Resulting Vision.
70	M.	60	...	...	...	...	...	...	...	...	...	"Reads ordinary print."
71	F.	55	...	...	...	...	...	1	Lens brought out with spoon.	...	...	V. = $\frac{20}{40}$
72	F.	37	...	...	...	...	...	...	...	...	Needling	V. = "Reads ordinary print."
73	F.	47	...	...	...	...	1	...	Spoon used to remove lens	Capsular opacity	...	V. = $\frac{20}{100}$
74	M.	54	...	...	...	Chlor.	...	1	...	...	...	V. = $\frac{20}{40}$
75	F.	67	...	...	...	...	...	1	...	...	...	V. = 0
76	M.	64	...	...	...	None.	1	...	...	...	...	V. = $\frac{20}{200}$
77	F.	63	...	...	...	None.	1	...	...	...	...	Unknown.
78	F.	70	...	...	...	None.	1	...	...	...	...	"Reads ordinary print."
79	M.	54	...	...	...	Chlor.	...	...	...	Panophthalmitis	...	V. = 0
80	F.	65	...	...	...	None.	...	1	...	...	...	V. = $\frac{20}{40}$
81	F.	69	Rheumatic and dyspeptic.	Hard.	Small cornea, 5″ diameter.	Ether.	1	...	Dialysis of iris produced by point of knife in making section which was enlarged with scissors.	Iritis without pain—membrane in pupil.	...	V. = $\frac{20}{40}$
82	F.	40	Nervous.	Hard.	...	Ether.	1	...	...	...	...	V. = $\frac{20}{60}$

83	F.	38	Good ...	Soft—traumatic.	None	Ether..	1	...	.....	.....	.....	V. = $\frac{10}{60}$
84	F.	66	Subject to attacks of erysipelas.	Hard.....	....	Ether..	1	...	.....	.....	.....	V. = $\frac{10}{60}$
85	F.	64	Corpulent.	Hard.....	.....	Ether..	1	...	.....	.....	.....	V. = $\frac{10}{60}$

EXTRACTIONS BY LIEBREICH'S METHOD.

No of Case.	Sex.	Age.	General Condition of Patient.	Character of Cataract.	Complications.	Accidents in Operation.	Condition of eye after operation.	Complications during Recovery from Operation.	Secondary Operations.	Resulting Vision.
1	F.	45	Poor.....	Hard.....	.....	.....	Pupil clear and circular.	Catarrhal conjunctivitis and immobility of lower segment of iris.	.....	V. = $\frac{10}{60}$
2	M.	40	Fair	Pasty ..	Atrophy of fellow eye from needling.	.....	Pupil clear and circular	.....	.....	V. = $\frac{10}{60}$
3	F.	21	Fair	Semifluid.	11 needlings had caused absorbtion of lens in the other eye.	Prolapse of iris successfully reduced.	Pupil clear and circular.	Prolapse of iris; iritis; closure of pupil.	Iridotomy..	V. = $\frac{30}{100}$

No. of Case.	Sex	Age.	General Condition of Patient.	Character of Cataract.	Complications.	Accidents in Operation.	Condition of Eye after Operation.	Complications during Recovery from Operation.	Secondary Operations.	Resulting Vision.
4	M.	60	Fair	Hard			Pupil clear and circular.	Soft lens matter seen in pupil 48 hours after extraction.	Keratonyxis.	V. = $\frac{20}{20}$
5	F.	63	Good	Hard			Pupil clear and circular.			V. = $\frac{20}{20}$
6	F.	35	Poor	Traumatic			Pupil clear and circular.	Soft lens matter seen in pupil a few days after extraction; serous iritis.	Paracentesis	V. = $\frac{20}{100}$
7	M.	40	Poor	Traumatic	Leucoma; Synech. post. and ant.; fluid vitreous.	Loss of vitreous; collapse of cornea; spoon used.	Collapsed eyeball.	Panophthalmitis		V. = $\frac{0}{0}$
8	F.	56	Excessively nervous.	Hard			Pupil clear and circular.	Catarrhal conjunctivitis; immobility of lower segment of iris; membrane in pupil.		V. = $\frac{20}{100}$
9	M.	50	Weighs 325 lbs.	Hard			Pupil clear and circular.	Prolapse of iris 24 hours after extraction.	Excision of prolapsed iris.	V. = $\frac{20}{100}$
10	F.	34	Very poor	Inflammatory	Extreme myopia; atrophy of choroid.		Pupil clear and circular.	Cortical matter in pupil some days later; membrane.	Keratonyxis.	V. = $\frac{1}{10}$
11	M.	60	Thin and wiry.	Hard			Pupil clear and circular.	Catarrhal conjunctivitis; membrane in pupil.	Keratonyxis.	V. = Percep. of light.

12	M.	85	Fair	Semifluid.	.....	.....	Pupil clear and circular.	Large prolapse of iris 24 hours after extraction; iritis; membrane in pupil.	Excision of prolapsed iris.	Counts fingers.
13	M.	70	Hemiplegia from Apoplexy.	Hard...	Couching had been done on the other eye; iris tremulous; eye frequently red and painful.	.....	Pupil clear and circular.	Prolapse of iris seen next day; slight iritis.	.....	V. = $\frac{16}{20}$
14	M.	65	Fair	Hard.....	Myopia	.....	Pupil clear and circular.	Serous iritis; membrane in pupil.	Paracentesis done twice.	V. = $\frac{20}{20}$
15	M.	52	Fair	Hard.....	.....	.....	Pupil clear and circular.	Slight membrane in pupil.	.....	V. = $\frac{20}{40}$
16	M.	70	Marasmatic.	Hard.....	Totally inelastic iris.	Wound enlarged with scissors; spoon used.	Pupil clear and circular.	Panophthalmitis....	.....	V. = $\frac{0}{0}$
17	M.	72	Good	Hard.....	.....	.....	Pupil clear and circular.	Membrane in pupil.	Keratonyxis.	V. = $\frac{20}{20}$
18	F.	69	Good	Hard.....	.....	Slight loss of vitreous.	Pupil clear and circular.	Synechia anterior of all the iris below the cut.	.....	V. = $\frac{20}{70}$
19	M.	63	Good	Hard.....	Inelastic iris	Wound enlarged with scissors at both ends; vitreous lost.	Cornea collapsed.	Synechia anterior of all below cut; membrane in pupil.	Keratonyxis.	V. = $\frac{20}{20}$
20	F.	41	Good	Hard.....	.....	.....	.....	Membrane in pupil..	Keratonyxis.	V. = $\frac{20}{60}$
21	M.	64	Dyspeptic and nervous.	Immature.	Myopia with staphyloma posticum.	Slight iridectomy	Pupil clear and circular.	Panophthalmitis....	.....	V. = 0

EXTRACTIONS BY LEBRUN'S METHOD.

No. of Case.	Sex.	Age.	General Condition of Patient.	Character of Cataract.	Complications.	Anæsthetic.	Accidents in Operation.	Complications during Recovery.	Secondary Operations.	Resulting Vision.
1	F.	60	Gouty; rheumatic knuckles; neuralgia	Hard nucleus; soft cortex.	.....	None.	Iridectomy of pupillary border of iris; soft lens matter milked out; cornea flaccid.	Membrane in pupil absorbed without any secondary operation.	.....	V. = $\frac{10}{10}$
2	F.	70(?)	.....	Hard nucleus; soft cortex.	.....	None.	Soft lens matter milked out and pupil left clear; marginal iridectomy.	Slight serous iritis.	.....	V. = "Reads ordinary print easily."
3	F.	65	Poor.....	Hard nucleus; soft cortex.	Fellow eye lost by inflammation following extraction.	None...	Blood and cortical left in pupil.	No inflammatory reaction.	.....	V. = $\frac{10}{10}$
4	F.	35	Feeble.....	Soft	.....	None..	.....	.....	.....	V. = $\frac{10}{10}$
5	F.	44	Marasmic	Semifluid ..	Synech. post. Previous iridectomy.	None...	.....	No inflammatory reaction.	.....	V. = Counts fingers.
6	F.	44	Marasmic	Semifluid ..	Synech. post. .	None.	Lebrun's section with iridectomy. The capsule was so tough that it had to be extracted by forceps before the lens would move from its fossa.	No inflammatory reaction.	.....	V. = Counts fingers.

EXTRACTIONS BY THE OLD FLAP METHOD.

No. of Case.	Sex.	Age.	General Condition of Patient.	Character of Cataract.	Complications.	Anæsthetic.	Flap. Upwards.	Flap. Downwards.	Accidents in Extraction.	Complications during Recovery.	Secondary Operations.	Resulting Vision.
1	M.	55	Good.	Hard.		None.	1					V. = $\frac{20}{40}$
2	M.	80	Atrophy of old age.	Hard.			1					V. = $\frac{20}{40}$
3	F.	70	Fair.	Hard.		None.	1					V. = $\frac{20}{50}$
4	F.	65				None.		1		Prolapse of iris caused by fit of sneezing.	Hook operation for pupillary membrane.	V. = $\frac{20}{50}$
5	F.	61				Chlor.	1					V. = $\frac{20}{70}$
6	M.	53				Ether.	1				Keratonyxis for membrane.	V. = $\frac{20}{40}$

STATEMENT OF RESULTS.

Graefe's	Successes	66	85
	Partial Successes	9	
	Failures	7	
	Unknown	3	
Liebreich's	Successes	15	21
	Partial Successes	2	
	Failures	4	
Lebrun's	Successes	4	6
	Partial Successes	2	
Flap	Successes		6
	Total		118

Successes	91	= 77⅓ per cent.
Partial Successes	13	= 10⅓ per cent.
Failures	11	= 9⅓ per cent.
Unknown	3	= 2⅓ per cent.
Total	118	

In 11 cases V. = $\frac{20}{20}$
In 12 cases V. = $\frac{20}{20}$
In 1 case V. = $\frac{10}{20}$
In 1 case V. = $\frac{2}{2}$
In 14 cases V. = $\frac{20}{20}$
In 8 cases V. = $\frac{20}{50}$
In 5 cases V. = $\frac{20}{60}$
In 1 case V. = $\frac{16}{50}$
In 5 cases V. = $\frac{20}{70}$
In 2 cases V. = $\frac{20}{80}$
In 9 cases V. = $\frac{20}{100}$
In 2 case V. = $\frac{1}{9}$
In 1 case V. = $\frac{1}{9}$
In 11 cases V. = $\frac{20}{200}$
In 8 cases V. = Ability to read ordinary print.

91 cases reckoned as successes.

In 1 case V. = $\frac{11}{13}$
In 1 case V. = $\frac{5}{70}$
In 2 cases V. = $\frac{1}{20}$
In 1 case V. = $\frac{6}{200}$
In 1 case V. = $\frac{1}{40}$
In 7 cases V. = Ability to get about alone, count fingers, etc., etc.

13 cases reckoned as partial successes.

In 9 cases V. = 0.
In 2 cases V. = Faint perception of light.

11 cases reckoned as losses.

In 3 cases the result is unknown.

Remarks.

Loss of vitreous occurred 3 times in the 21 Liebreichs, or in $14\frac{3}{7}$ per cent.; 4 times in the 85 Graefes or in $4\frac{7}{10}$ per cent.; and not at all in the Lebruns and old Flap.

The lens was removed by the scoop in 5 Graefes, or about 6 per cent.; in 2 Liebreichs, or about $9\frac{1}{2}$ per cent., and not at all in Flap or Lebruns.

Prolapse of iris occurred during recovery in the Liebreichs 4 times, about 19 per cent.; in the Flap once, $16\frac{2}{3}$ per cent.; in the Graefes once, less than $1\frac{1}{2}$ per cent., and in the Lebruns not at all.

Cystoid cicatrix occurred in one Graefe, and in none of the other methods.

Synechia anterior occurred in 2 Liebreichs where there had been no prolapse of iris.

Immobility of the portion of iris below the cut, either from synechia posterior, or from a localized iritis with interstitial thickening, was noted in *two* Liebreichs.

Iritis with closure of pupil occurred in 5 Graefes and in 1 Liebreich.

Serous iritis occurred in 2 Liebreichs and in 1 Lebrun.

Panophthalmitis occurred in 3 Liebreichs and in one Graefe.

Hyalitis occurred in 2 Graefes.

Pupillary Membranes formed in 20 Graefes and in 8 Liebreichs.

Sympathetic Irido-choroiditis, destroying both eyes, occurred in one Graefe.

Notes of cases in which loss occurred after operation by Graefe's method.

Case 7.—H. K., 58. Nothing peculiar observed in the physical condition of the patient, except that he was extremely loquacious and had acne rosacea. Extraction done December 1st. A small portion of pupillary margin of iris was cut off in making the section. On lacerating

the capsule fluid cortical substance flowed into and obscured the anterior chamber. The lens was easily extruded, but it seemed to be necessary to use a spoon to remove some small pieces of cortical from the anterior chamber. This patient took ether very quietly, and was left for a few moments by his attendant, after he had been informed of the safe removal of the cataract and replied that he was very comfortable. In the course of half an hour the patient was found to have removed, during the temporary absence of his attendant, the black silk mask and strips of isinglass plaster with which his eye had been closed, and to have dressed himself for a walk. The patient was, after much difficulty, put to bed again and his clothes hidden and the dressings renewed.

December 7th: Eye looks well; wound healed. Counts fingers readily.

December 25th: Eloped from hospital, having found his clothes and borrowed a hat.

January 5th: Returned again. Examined ophthalmoscopically and found to have retino-choroiditis with floating bodies in vitreous, and possibly a small retinal detachment.

Case 11.—J. F., 43, muscular, and corpulent. Extraction attempted by Graefe's method, December 15. It was impossible to produce complete anæsthesia of the eye by means of chloroform. The patient struggled excessively against the anæsthetic, and would suddenly become stertorous and asphyxiated, compelling efforts to be made for his partial resuscitation. Under these circumstances there was a premature loss of aqueous in the attempt to make the section, and we were forced to desist. The wound healed kindly, and on January 1st another attempt was made to operate, under ether. The ether affected the patient as badly as the chloroform had, and at no time could anæsthesia of the eye be accomplished, although a pint of ether was used in a cone. There was so much muscular rigidity and straining, that two or three persons were engaged in holding the patient while the ether was being assiduously administered. The section was, however, completed. In cutting out, the iris came in front of the knife, and was so cut as to leave the margin of the pupil intact, forming an isthmus, as it were, between a large irregular perforation and the pupil.

After lacerating the capsule, this isthmus-like segment of the pupillary margin was drawn out by means of forceps, and out with scissors in such a manner as to complete the coloboma. While performing this manipulation, the vitreous prolapsed, and two or three minims of it escaped in a gushing manner.

The eyes were closed with isinglass-plaster strips, and a black silk dressing.

As there was little or no pain, it was deemed wise, in view of the large amount of vitreous humor lost, not to open or expose the eye, especially as the removal of the outer dressing showed that there was neither swelling nor discoloration of the eyelids, nor any discharge.

January 15th: At this date the eye was opened, the cornea found to be clear, anterior chamber restored, circum-corneal injection slight. A slow iritis now set in without pain or increase of tension.

February 7th: Coloboma bridged over by a membrane.

At this date the patient, having good perception of light, was allowed to go home.

April 28th: We attempted to tear the membrane in the pupil by means of a stop-needle and sharp hook; patient under insufficient chloroform. Failed to secure an open pupil.

July 11th: Did an iredectomy. Succeeded in removing a sufficient piece of iris from nasal side of the coloboma, but not in maintaining an open pupil.

October 10th: Needled the membrane. After recovering from this operation, the patient had good vision, enabling him to read and write in his occupation—that of a lawyer. After a lapse of several months, however, vision began to fail, and then suddenly went, and the ophthalmoscope revealed almost total detachment of the retina.

Case 25.—E. K. W., 71. Patient had marked senile atrophy. Eyelids and general skin flaxed and inelastic, and knuckles much enlarged by gouty deposits.

Graefe's operation done under ether and without accident or vomiting. Eye did badly from second day; corneal wound did not heal until 15th day. Choroiditis with large lymphoid effusions in anterior chamber, reduced V. to perception of light, and

so matted iris as to make any operation for secondary cataract hopeless.

This eye was enucleated some months afterwards by Prof. Bacon, of New Haven, who did a Liebreich upon fellow eye, resulting in useful vision.

Case 29.—H., æt. 75. Lenses have both begun to undergo secondary degeneration, have dark chocolate-colored nuclei, especially the left with striæ, and veins of a whitish calcific character mottling or marbling them. Right eye probably involved in an injury of that side of face in childhood, as there are extensive scars. V.=counts fingers in one foot. Patient is an old rheumatic, has marked senile marasmus, and is very feeble. V.= L. E. perception of light only. No limitation of visual field; phosphenes present.

October 13, 1874: L. E. operated upon by Graefe's method. Mixture of equal parts of ether and chloroform given.

The cornea was very flaccid, wrinkling after escape of aqueous; lens large and very dark-colored nucleus. No accident during the operation nor loss of vitreous. Isinglass plaster and black silk dressing applied.

October 14th: Has had little or no pain since operation. Slept well without hypnotic. During the night blood issued from beneath the dressings. This morning eye examined: blood oozing from ciliary region through wound. Atropia instilled; bandage and charpie applied. Had some bloody oozing, until 20th, when wound of cornea healed. On 30th October was discharged. Wound healed; coloboma still open and showing a dark, olive-colored reflex. V.= faint perception of light.

Case 55.—J. K., 61. Had right eye injured and vision impaired, by wound from foreign body, eight or ten years ago, resulting after some years in a cataract. Has a central scotoma; circumference of visual field unaffected.

November 12, 1873: Operated upon the right eye by Graefe's method, without anæsthetic. Speculum and fixation forceps used, and section made easily. Iridectomy made in usual manner. This was immediately followed by gushing escape of vitreous humor. Removed lens by means of a scoop, and was compelled by drainage of vitreous to leave some crumbs of cor-

tex in field of coloboma. Had severe pain first night, requiring anodyne.

November 13: Removed bandage and charpie; considerable secretion from conjunctiva; eyelids swollen; chemosis marked; cornea clear, but aqueous turbid; field of coloboma grayish; tension increased.

Instilled atropia; applied iced cloths, and leeched temple.

18th: Opened wound and evacuated anterior chamber.

29th: Eye remained in condition of chronic iritis for several days, with small hemorrhages into anterior chamber. Discharged with good perception of light.

Case 75.—E. C., 67. Marked premature senile marasmus.

L. E. operated by Graefe's method under ether, section downward, expecting in this way to obviate some of the difficulties of an operation. No accident attended operation, but cornea fell in a crumpled state into empty lenticular fossa. He had excessive, constantly recurring vomiting and retching for several days.

May 17th: Cornea sloughing, and anterior chamber and lenticular fossa suppurating. Soon sympathetic irido-choroiditis of a most painful character occurred in fellow eye, which was cataractous. Enucleation urged, but declined. Patient left Brooklyn Eye and Ear Hospital in a miserable state, and lost all perception of light, suffering exceedingly.

Case 79.—W. J. D., 54, April 15th, 1871. Right eye operated upon, Graefe's method, section upward. Chloroform given. Panophthalmitis set in on day following, sinking the eye.

Notes of cases in which loss occurred after operation by Liebreich's method.

Case 7.—M. H., æt. 40. Blown up by gunpowder fourteen years previously. The accident had destroyed and sunk right eye, but leaving it free from irritability. It had produced a perforating ulcer of the fellow eye, which healed with an extensive leucoma and synechia anterior, and slight synechia posterior. I had made an iridectomy upwards, at that time, restoring useful vision, which he had enjoyed until 1872, when, after receiving a blow upon the eye, cataract supervened, reducing

vision to perception of light. Testing his eye in 1873 for an operation, it was found that the lower portion of the visual field was blind, but whether from detachment of retina or choroido-retinal atrophy, we could not say. He was informed that the chances of a cataract extraction were all against him, but that it might possibly result in some vision.

A Liebreich was attempted, March 12th, 1873. The lens proved to be pasty or waxy, and the vitreous and aqueous commingled, so that the eyeball began to empty itself as the corneal section was made. The lens was removed, however, partly by pressure, partly by the aid of a spoon, and the eyes closed by means of strips of isinglass plaster and a black silk dressing.

March 13th: Some pain during night, but not so severe as to prevent natural sleep. Removed dressings; instilled atropia anterior chamber full.

March 13th, 5 P.M. Pain in forehead. Removed dressings; eyeball plump; cornea hazy; no perception of candle-light. Gave opium and repeated atropia.

8 P.M.: Pain in forehead and eye increased. Gave hypodermic of Sol. Morph. M., m. x., with entire relief of pain.

March 14th: Panophthalmitis, which ran its usual course spoiling eye.

Case 11.—W., 60. A thin and wiry man with sclerosis of all observable arteries. The operation (Liebreich) was without accident, but the eye recovered with a membrane in the pupil, reducing V. to $\frac{20}{100}$. Some weeks later, as V. lessened, the pupillary membrane was needled. This was followed by serous iritis, which yielded slowly to paracentisis, leeches, and atropia. After some weeks patient was allowed to go home. He returned in three weeks, with pupil closed, eyeball somewhat congested, tension minus, perception of light very uncertain.

Case 16. (Liebreich's).—H., æt. 70, farmer. Observable vessels sclerosed. Pupil sluggish. No anæsthetic used. Incision made easily. When the capsule was opened lens would not follow. Wound enlarged, but pupil would not stretch. I then tilted the lens by pressure on the upper part of the cornea, and delivered it by means of a flat spoon. No vitreous lost, nor was there ery much violence inflicted. Operation done June 4, 1873.

June 5th: Removed flannel bandage and charpie; considerable conjunctival secretion; cornea transparent; pupil black; incision scarcely discernible; little or no injection of circumcorneal parts. Dropped in Sol. Atrop., and renewed bandage.

June 6th, 6 A.M.: Had severe throbbing, supra-orbital pain during the night, but did not ask for relief. Removed bandage. Conjunctival secretion marked; eyeball red; cornea cloudy. Atropia and iced cloths.

3 P.M.: Tension +. Opened wound and emptied anterior chamber.

Evening: Edge of flap beginning to show necrosis. Applied hot fomentations; gave quinine and tincture of iron.

June 10th: Eye gone by panophthalmitis.

Case 21. (Liebreich) D. B., æt. 64. A very tall, thin gentleman, who had had several severe attacks of bronchitis and been subject to syncopy. Marked sclerosis of radial arteries and other superficial vessels. Eyes known to be myopic and to have posterior staphylomata. Corneal diameter 5½'''. Pupil mobile. The incision was easily made. In finishing the latter the lower margin of the pupil fell in front of the knife and was cut. The lens came out easily, pushing through the wound one or two tags of the cut iris, which were easily removed by the scissors. Every vestige of cortex was carefully removed by gently stroking and pressing the cornea, and without using the spoon, until the pupil seemed under oblique illumination in the focus of a two-inch lens to be clean and black. No vitreous was lost, nor was there any remaining prolapse of iris. Patient counted fingers immediately after the operation on October 22d, 1873. A light flannel bandage and charpie were applied. The patient did perfectly well until the fourth day—26th inst., when at 3.30 A.M. he was awakened by feeling as though he had struck his eye. This was followed by severe pain.

At 10 A.M. the eyelids were swollen, tender to the touch, and there was much circumorbital pain. The eyeball was reddened; the iris pressed forward against the cornea, which was still transparent. The pupil was still clear and not contracted. Atropia was instilled, leeches applied, and after encouraging the bleeding by hot fomentations, iced cloths were placed upon the closed eye and frequently changed. Quinine was given, and

such nutritious food as could be taken. In a comparatively few hours the interior of the eye seemed to be engaged in pyogenic action, and to furnish a free flow of pus, somewhat tinged with blood. Under this inflammatory action the cornea soon sloughed, the eye rapidly diminished in size, painlessly shrinking until it formed a bulb not more than four or five lines in diameter. We were impressed by the rapid diminution of the size of the eyeball. It seemed as though it quickly melted. There was very little pain after the pyogenic action was fairly set up, and at no time was much, if any, inflammatory action in the circumocular connective tissue. It occurred to me that the disaster might possibly be due to atheroma of one or more of the branches of the ophthalmic artery.

A NEW METHOD OF OPERATING FOR STRABISMUS. By J. F. Noyes, M.D., Detroit, Mich.

Besides mere cosmetic considerations, and of paramount importance in operating, is the restoration, when possible, of binocular vision. In striving to do this, the necessary correction of the deviation or squint has always been affected either by a retrocession or setting forward of the tendon by first dissecting it off at the point of attachment or insertion on the ball.

It has also been found necessary in some cases, where the convergent deviation exceeded 3½‴, to perform two or more operations to make the correction, or least a tenotomy upon each eye. But this is not all: by making the tenotomy on the shortened muscle, as is now done, an increased widening of the palpebral commissure is produced, and an unnatural prominence is always given to the eye with a palpable sinking of the caruncle, and this, especially when limited to one eye, results too often in a positive deformity.

Again by disturbing the point of attachment or insertion of the tendon on the globe, there is the risk of disturbing also the vertical meridian of the eye and of producing in the healing and contracting of the wound more or less astigmatism.

In my operation none of these things can possibly take place, since the correction is always effected by *shortening* of the opposing or elongated muscle and without disturbing, also, the point of attachment or insertion of the tendon on the ball.

Essentially the main points or features which are new in the method now proposed to recapitulate them may be stated as follows, viz.:

1st. The correction of the deviation or squint is made only on one eye and by one operation, and is effected without disturbing the point of insertion or attachment of the tendon on the ball.

2d. The tenotomy is made on the opposing or elongated tendon.

3d. The shortening necessary to correct the squint or deviation is made by lapping the ends of the divided tendon, and is applicable to all cases.

My first operation was made on a girl, æt. 20, March 3d, 1874. Right eye deviation by measurement, 4‴. Strabismus convergent. Eye slightly amblyopic; can make out with it No. 13 Jaeger. Left eye normal; result of operation satisfactory.

The second case, also a girl, æt. 20, was operated on about one month after the first case. Tenotomy on the left eye. Deviation convergent, 4‴. Amblyopic. Reads No. 14 Jaeger with difficulty. Right eye normal; result perfect. A photograph showing same is herewith presented to the society.

The operation is made in the following manner:

The patient being fully under chloroform or ether, the lids secured wide open by a stop speculum, a horizontal incision or slit is made in conjunctiva directly over the tendon, sufficiently long, through which the tendon is lifted out on a blunt hook. The tendon is then divided quite near to its insertion on the ball, leaving enough end or stump so that the other end of the divided tendon can be carried under it lapped and secured by sutures. The amount of shortening thus effected must by actual measurement equal the deviation to be corrected. If it be found necessary to do this a portion from the end of the tendon may be cut off before carrying it under and lapping as already described.

The surfaces of the tendons where they come together in lapping, I need hardly say, should be previously freshened by a knife, or the tendon, if it can be done, may be divided in the first place obliquely. Two stitches or sutures only are sufficient to secure the ends of the tendons thus placed until they grow together, using a curved needle for this purpose; it is passed first through the conjunctiva, and then from beneath through the tendons, thus placed on one side and tied, and then in the same manner on the other side and tied. On the third or fourth day after the operation, or longer, the sutures can be removed with safety.

41B 2 2